Int. J. Oral Maxillofac. Surg. 2026; 55: 1291–1298
https://doi.org/10.1016/j.ijom.2026.04.014, available online at https://www.sciencedirect.com

International Journal of Oral & Maxillofacial Surgery

Clinical Paper

Head and Neck Oncology

Impact of line-field optical coherence tomography in preoperative margin assessment of head and neck basal cell carcinoma: a cohort study

A. Frosolini[a], V. Chiantini[a], G. Gabriele[a], A. Cartocci[b], L. Tognetti[b], O. Massarelli[a], P. Rubegni[b], P. Gennaro[a], E. Cinotti[b]

[a]Department of Medical Biotechnologies, Maxillofacial Surgery Unit, University of Siena, Siena, Italy; [b]Dermatology Unit, Department of Medical, Surgical and Neurological Sciences, University of Siena, Siena, Italy

A. Frosolini, V. Chiantini, G. Gabriele, A. Cartocci, L. Tognetti, O. Massarelli, P. Rubegni, P. Gennaro, E. Cinotti: Impact of line-field optical coherence tomography in preoperative margin assessment of head and neck basal cell carcinoma: a cohort study. Int. J. Oral Maxillofac. Surg. 2026; 55: 1291–1298.
© 2026 The Author(s). Published by Elsevier Inc. on behalf of International Association of Oral and Maxillofacial Surgeons. This is an open access article under the CC BY-NC-ND license (http://creativecommons.org/licenses/by-nc-nd/4.0/).

Abstract. In head-and-neck basal cell carcinoma (BCC), accurate preoperative delineation of lateral tumour margins remains challenging. Line-field confocal–optical coherence tomography (LC-OCT) offers real-time, high-resolution imaging that may improve surgical planning. This study evaluated the impact of preoperative LC-OCT on oncologic and procedural outcomes, focusing on lateral positive margins.A mixed prospective–retrospective cohort study was conducted, comparing BCC cases treated after LC-OCT implementation (2023–2024) with historical controls (2018–2021). Lesions with unclear clinical or dermoscopic margins underwent LC-OCT-guided mapping. Primary outcomes were positive histological margins and recurrence; secondary outcomes included time to surgery, operative time, frozen section use, reconstruction, and minimum lateral margin distance. Multivariable logistic regression adjusted for group, age, tumour size, H-zone location, presentation, histologic subtype, and pT stage.A total of 102 patients were included (LC-OCT n = 23; controls n = 79). H-zone distribution was comparable between groups (69.5% vs 53.2%, P = 0.50). Positive margins occurred in 19.0% vs 24.6% (P = 0.772), and recurrence in 0% vs 5.2% (P = 0.573). Median time to surgery was longer with LC-OCT (48 vs 34 days, P = 0.016), while operative time was shorter (55 vs 95 minutes, P = 0.013).In multivariable analysis, H-zone location (aOR 3.96, P = 0.041) and aggressive histology (aOR 6.39, P = 0.015) predicted lateral positivity, whereas LC-OCT did not (aOR 1.61, P = 0.565; AUC 0.774).LC-OCT did not independently reduce lateral positive margins but may support precision mapping, at the cost of longer treatment timelines. Prospective studies with standardized workflows are warranted.

Keywords: Optical coherence tomography; Basal cell carcinoma; Head and neck neoplasms; Margin of excision; Dermatoscopy; Plastic surgery procedures.

Accepted for publication 15 April 2026
Available online 27 April 2026

0901-5027/551291 + 8

© 2026 The Author(s). Published by Elsevier Inc. on behalf of International Association of Oral and Maxillofacial Surgeons. This is an open access article under the CC BY-NC-ND license (http://creativecommons.org/licenses/by-nc-nd/4.0/).

Basal cell carcinoma (BCC) is the most common skin cancer worldwide, characterized by local invasiveness and very low metastatic potential. It predominantly affects chronically sun-exposed areas, especially the face and neck, where accurate preoperative margin delineation is crucial to minimize recurrence and cosmetic morbidity[1]. Diagnosis and margin assessment traditionally rely on clinical examination and biopsy[2], but these methods are invasive, subject to sampling error, and may be inadequate in defining tumour extent, particularly within the H-zone of the face[3]. This creates a clear need for precise, non-invasive imaging tools for preoperative BCC assessment.

In this context, line-field confocal–optical coherence tomography (LC-OCT) emerges as a promising imaging modality. Based on a combination of optical coherence tomography and reflectance confocal microscopy, it allows for high-resolution images of skin structures without tissue damage[4]. LC-OCT offers real-time imaging in both vertical (histology-like) and horizontal planes, achieving a cellular resolution of 1 μm and a penetration depth of 500 μm. This technology can differentiate tissue structures and reveal characteristic morphological features of BCC such as lobular patterns, millefeuille pattern, bright rim, and clefting[5]. Recent literature has underlined LC-OCT substantial diagnostic accuracy in identifying BCC, with reported sensitivity rates from 97% to 98% and specificity ranging from 80% to 95%[6,7]. Some studies have assessed the role of LC-OCT in the preoperative delineation of margins. Paradisi et al.[8] examined frozen sections of high-risk BCCs and compared LC-OCT margin analysis with full-margin histopathological assessment in 22 patients. Deußing et al.[9] present a proof-of-concept/tutorial of artificial intelligence (AI)-assisted, in-vivo LC-OCT margin mapping with no control group, quarter-wise scanning, an AI probability colour map, and a standard 3 mm safety cuff before same-day excision; notably the location sites were not limited to head and neck. Jacobsen et al.[10] report an ex-vivo Mohs case series (six BCCs) imaging canonical LC-OCT markers on excised tissue, again without clinical comparators or preoperative planning metrics. Thus, while previous studies primarily demonstrate feasibility and LC-OCT technique, there is a lack of information on its clinical impact in a real-world head-and-neck setting.

Therefore, the purpose of the present study was to critically evaluate the strengths and limits of LC-OCT in the assessment of head-and-neck BCC lesions, offering a comprehensive insight into its diagnostic accuracy and clinical applicability in a surgical setting. The primary aim was to determine whether preoperative LC-OCT-guided improves: oncologic safety, measured by the rate of positive histological margins and recurrence; surgical quality, as reflected in reconstructive outcomes and the need for reintervention. The secondary aims were to assess the broader procedural and organizational consequences of integrating this technique in clinical practice: impact of LC-OCT on surgical planning workflow, expressed as time from diagnosis to intervention; use of intraoperative frozen section and surgical duration.

Patients and methods

Study design

To address the research purposes, a mixed prospective-retrospective cohort study was performed. Patients referring for clinical suspicion of BCC of the head-and-neck region and treated at the Maxillofacial Surgery Unit of the University Hospital 'Le Scotte' in Siena, Italy, between 2023 and 2024 (after the introduction of preoperative LC-OCT) were prospectively collected and compared with a retrospective cohort of patients treated between January 2018 and December 2021[11]. All lesions that were examined by LC-OCT were challenging cases because patients were subjected to this examination when clinical and dermoscopic tumour margins were unclear. Lesion size and anatomical location were collected a priori to assess baseline comparability between cohorts and were included as covariates in adjusted analyses.

Inclusion criteria and outcomes

Patients with incomplete data or those who died before treatment were excluded from the study. Collected variables included demographics, clinical presentation, lesion characteristics (size, location, TNM)[12], histopathology, surgical details (reconstruction type, duration), and follow-up outcomes. The primary outcomes of the study were the following: rate of positive surgical margins, defined as the presence of tumour cells at the periphery of the excised specimen (direct indicator of the adequacy of preoperative tumour delineation), or at the deep margin, both as confirmed by postoperative histopathology; recurrence rate defined as the clinical or histopathological reappearance of BCC at the same site within a 6-month follow-up period (confirmed through clinical, dermoscopic and LC-OCT examination, and, when needed, biopsy); reconstructive outcome evaluated through surgical notes and photographic documentation, focusing on reconstruction type, margin clearance (including minimum lateral negative margin), complications, revision surgery, and aesthetic outcome (Manchester scale, score range 4–14). Secondary outcomes included: surgical duration, measured from skin incision to final suture; number of surgeries required to achieve complete excision; impact of LC-OCT on surgical planning, defined as any modification to the planned excision margins based on LC-OCT findings. For risk stratification, lesions were classified according to involvement of the facial H-zone, defined as the anatomical area of the central face, including the nose, eyelids, eyebrows, periorbital skin, lips, chin, ears, and temple, which are recognized locations for high-risk BCC[13].

LC-OCT-guided margin detection and surgical protocol

Tumour margins were initially delineated at the clinical and dermoscopic limits and marked with a dermographic pen. Paraffin oil was applied to eliminate air between the skin and the LC-OCT probe (deepLive, DAMAE Medical, France). The probe was then passed along the entire margin under dermoscopic guidance to detect tumour presence. When LC-OCT findings were negative, the line was redrawn closer to the lesion; if positive, it was moved outward. This process was repeated until a fully LC-OCT-negative margin was obtained, positioned as close to the lesion as possible. All examinations were performed by a single experienced operator (E.C., > 10 years of OCT expertise) and required approximately 30 min.

Standard excision was subsequently performed by the maxillofacial team. The planned lateral margin corresponded to the LC-OCT-negative line

Table 1. Demographic and primary outcomes from our cohort study.

Variable	LC-OCT group	Control group	*P*-value
Mean age (years)	69.1 ± 10.2 (23 patients)	76.5 ± 12.5 (79 patients)	0.011*
Female sex	13/23 (56.5%)	35/79 (44.3%)	0.350
Presentation at diagnosis: recurrent lesion	3/23 (13.0%)	11/79 (13.9%)	1.000
H-zone location	16/23 (69.5%)	42/79 (53.2%)	0.50
Tumour size (cm)	2.15 ± 1.47 (23 patients)	1.65 ± 1.14 (79 patients)	0.093
pT2 staging	10 (43.5%)	22 (29.3%)	0.202
Positive histological margins	4/21 (19.0%)	18/73 (24.6%)	0.772
Distance to tumour of negative margins (mm)	3.38 ± 3.07 (9 patients)	1.57 ± 1.32 (7 patients)	0.220
BCC diagnosis	18/23 (78.3%)	72/79 (91.1%)	0.106
Non-BCC diagnosis: benign lesion	2/23 (8.7%)	5/79 (6.3%)	
Non-BCC: NMSC diagnosis	3/23 (13.0%)	2/79 (2.5%)	
BCC subtypes aggressive (invasive/morpheaform)	5/18 (27.8%)	44/68 (64.7%)	0.006*
Recurrence at follow-up	0/21 (0%)	4/75 (5.2%)	0.573
Reintervention for residual tumour	2/23 (8.7%)	4/75 (5.3%)	0.58

BCC, basal cell carcinoma; LC-OCT, line-field confocal–optical coherence tomography; NA, not appropriate; NMSC, non-melanoma skin cancer.
*Statistically significant at $P < 0.05$.

plus a 2–6 mm safety cuff, adjusted for subsite and histological suspicion; deep margins were taken at the subcutaneous fat or periosteum as appropriate. If intraoperative suspicion of residual disease arose, frozen sections were sampled at the narrowest margin and additional resections performed if positive. Reconstruction was completed by primary closure, local flap, or dermal substitute, following facial aesthetic unit principles[14]. Postoperative follow-up occurred at 1, 3, 6 and 12 months, including dermoscopy and LC-OCT when indicated.

Statistical analysis

Data from both cohorts were compared to assess potential differences in preoperative characteristics and surgical outcomes. All analyses were performed on an intention-to-diagnose basis. Non-BCC lesions identified on final histopathology were retained in the cohort, as their exclusion would have introduced post-hoc selection bias. Quantitative variables were reported as mean ± standard deviation (SD). Categorical variables were summarized as absolute counts and percentages. Normality was assessed using the Shapiro–Wilk test. As several continuous variables were not normally distributed, between-group comparisons were performed using the Mann–Whitney *U*-test. χ^2-Test or Fisher's exact test was applied to categorical variables depending on cell size. Logistic regression was used to identify predictors of lateral margin positivity. Covariates included in the multivariable model were selected a priori based on clinical relevance and previously reported risk factors for positive surgical margins in head-and-neck BCC, rather than on univariable statistical significance, in order to avoid data-driven model specification. Results are reported as adjusted odds ratios (aOR) with 95% confidence interval (CI) ($\alpha = 0.05$). Analyses were performed in jamovi (v2.3)[15].

Results

A total of 102 patients were included in the study: 23 in the LC-OCT group and 79 in the control group. The mean age

Table 2. Secondary outcomes.

Variable	LC-OCT group	Control group	*P*-value
Interval diagnosis to surgery (days)[a]	75.8 ± 65.0; 48; 40 (22 patients)	44.8 ± 46.6; 34; 23 (47 patients)	0.016*
General anaesthesia	6/23 (26.1%)	39/77 (50.5%)	0.055
Intraoperative frozen section positive	3/23 (13.0%)	20/74 (27%)	0.261
Advanced reconstruction (flap)	12/23 (52.2%)	40/75 (53.3%)	0.577
Primary closure	7/23 (30.4%)	16/75 (21.3%)	
Graft/dermal regeneration	4/23 (17.4%)	19/75 (25.3%)	
Surgical duration (min)[a]	92.95 ± 84.58; 55; 70 (22 patients)	127.06 ± 81.13; 95; 82 (79 patients)	0.013*
Manchester scale (aesthetic outcome), mean ± SD	4.6 ± 1.9	5.6 ± 2.5	0.138

LC-OCT, line-field confocal–optical coherence tomography.
[a]Mean ± standard deviation; median; interquartile range.
*Statistically significant at $P < 0.05$.

Table 3. Multivariable logistic regression for lateral positive margin.

Predictor	aOR	95% CI	*P*-value
H-zone (high-risk) vs other	3.96	1.06–14.80	0.041*
Aggressive histology vs non-aggressive	6.39	1.43–28.61	0.015*
LC-OCT (study) vs control	1.61	0.32–8.17	0.57
Size (per cm)	0.32	0.09–1.10	0.071
Age (per year)	0.98	0.94–1.03	0.50
Presentation: recurrent vs primary	1.45	0.28–7.48	0.66
pT: high vs low	7.53	0.56–101.13	0.13

aOR, adjusted odds ratio; CI, confidence interval; LC-OCT, line-field confocal–optical coherence tomography.
Outcome: lateral positive margin on final histology. Analysis restricted to basal cell carcinoma with available lateral margin status.
Aggressive: infiltrative/morpheaform. H-zone: nose, eyelids/periocular, lips, chin, ear.
*Highlight the $p < 0.05$.

was 69.1 ± 10.2 years in the LC-OCT group and 76.5 ± 12.5 years in the control group ($P = 0.011$). Sex distribution, recurrence at presentation, tumour localization, and mean tumour size were comparable (see Table 1).

The mean interval between LC-OCT mapping and surgery was 8.2 ± 13.7 days. In 12 of 23 LC-OCT cases (52.2%), preoperative skin markings were no longer visible at the time of surgery and margin localization was reconstructed intraoperatively using standardized clinical photographs. The interval between diagnosis and surgery was longer in the LC-OCT group, with a mean of 75.8 ± 65.0 days and a median of 48 days (IQR 40), compared with 44.8 ± 46.6 days and a median of 34 days (IQR 23) in the control group ($P = 0.016$) (Table 2). General anaesthesia was used in 6/23 (26.1%) of LC-OCT patients and 39/77 (50.46%) of control patients ($P = 0.055$). The intraoperative frozen section was positive in 3/23 (13.0%) in the LC-OCT group and 20/74 (27.0%) in controls ($P = 0.261$). Reconstruction type did not differ overall ($P = 0.577$) (Table 2). Surgical duration was 92.95 ± 84.58 min (median 55, IQR 70) in the LC-OCT group and 127.06 ± 81.13 min (median 95, IQR 82) in the control group ($P = 0.013$). BCC were the final histopathological diagnosis in 18/23 (78.3%) of the study group and 72/79 (91.1%) of the control group. In contrast to preoperative clinical assessment and/or incisional biopsy, non-BCC (basosquamous or squamous cell carcinoma) were diagnosed in 3/23 (13.0%) of the LC-OCT group and 2/79 (2.5%) of the control group; benign tumours were diagnosed in 2/23 (8.7%) of the study group and 5/79 (6.3%) of the control group ($P = 0.106$). BCC histologic subtype distribution differed between groups (LC-OCT vs control: nodular 13 vs 0, infiltrative 2 vs 43,

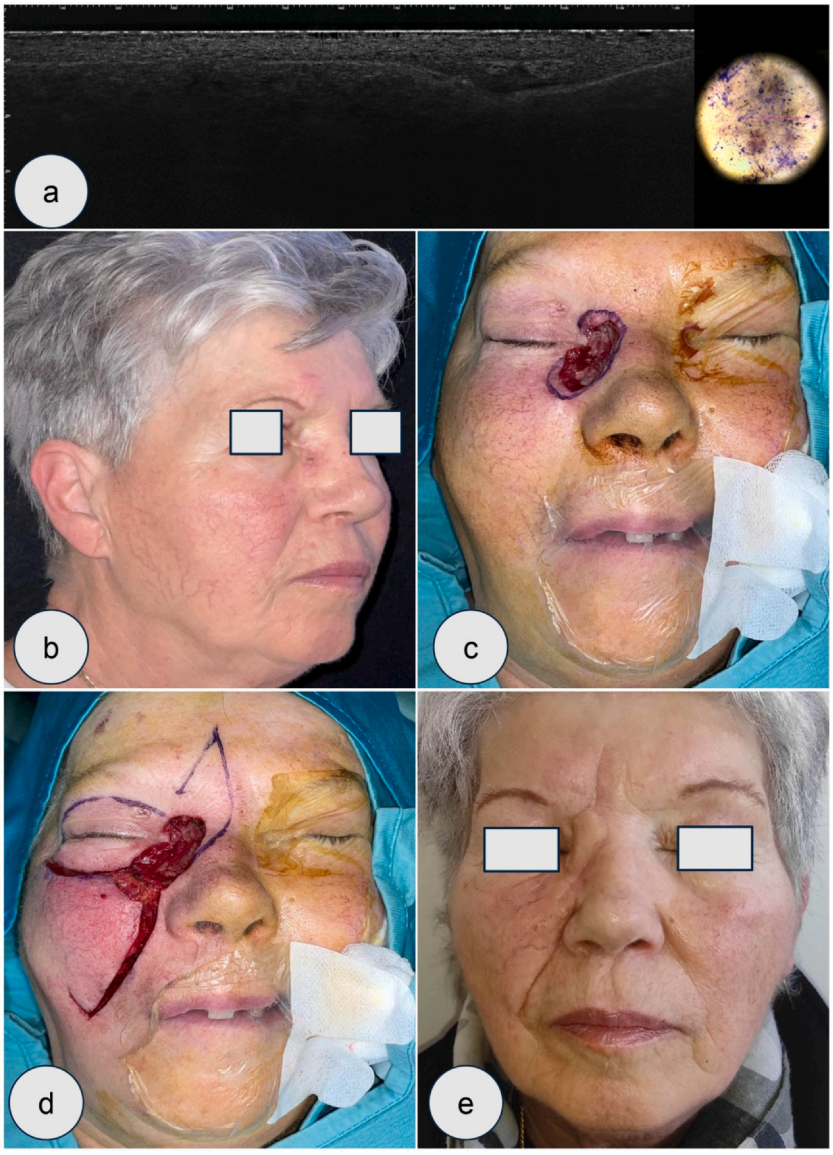

Fig. 1. Line-field confocal–optical coherence tomography (LC-OCT)-guided planning, excision, and reconstruction with a modified glabellar and cheek flap. Representative case of H-zone basal cell carcinoma with unclear clinical margins. (a) Preoperative imaging. Left: LC-OCT vertical section demonstrating subtle hyporeflective dermal changes suggestive of tumour extension beyond the clinically estimated margin. Right: corresponding dermatoscopic image with marking indicating the initial clinical margin. (b, c) Preoperative clinical appearance. (d) Intraoperative view showing planned lateral margin and deep margin to subcutaneous tissue as appropriate. (e) Early follow-up outcome after modified glabellar and cheek flap reconstruction.

morpheaform 2 vs 0, superficial 1 vs 3; $P = 0.00015$). Accordingly, aggressive BCC (i.e infiltrative and morpheaform) was less frequent in the LC-OCT cohort: 5/18 (27.8%) vs 44/68 (64.7%) in controls ($P = 0.006$). Positive histological margins in BCC lesions were found in 4/21 (19%) LC-OCT patients and 18/73 (24.6%) control patients ($P = 0.772$). Of the positive histological margins in the LC-OCT group, one concerned depth margin, while the other three concerned lateral margins. For the control group the positive histological margins concerned depth in six cases and periphery in 12 cases. Among the few BCCs with recorded distances, the minimum lateral negative margin was larger in LC-OCT cases (3.38 ± 3.07 mm; $n = 9$) than in controls (1.57 ± 1.32 mm; $n = 7$), but this difference was not statistically significant ($P = 0.220$). Reintervention for residual tumour was proposed to all patients: in LC-OCT group it was performed in 2/23 (8.7%) and in control group in 4/75 (5.3%) cases in controls ($P = 0.13$). Recurrence after surgery occurred in none of LC-OCT patients and in 4/75 (5.2%) of control patients ($P = 0.573$). Manchester scale was on average 4.6 ± 1.9 in the LC-OCT group and 5.6 ± 2.5 in the control group ($P = 0.138$).

In the multivariable logistic regression (Table 3), H-zone location and aggressive histology were independently associated with higher odds of lateral margin positivity (H-zone vs other: aOR 3.96, 95% CI 1.06–14.80, $P = 0.041$; aggressive vs non-aggressive: aOR 6.39, 95% CI 1.43–28.61, $P = 0.015$). LC-OCT use was not associated with lateral positivity (aOR 1.61, 95% CI 0.32–8.17, $P = 0.565$). Model fit was acceptable (Akaike information criterion 91.2, Bayesian information criterion 110, McFadden's R^2 0.257) with good discrimination (area under the receiver operating characteristic curve (AUC) 0.774). Collinearity was not problematic (maximum variance inflation factor ≈ 4.3 for size and pT).

Discussion

BCC is the most common skin cancer, with more than 80% of cases occurring in the head and neck region. Surgical management in this anatomically and aesthetically complex area must balance complete oncologic clearance with tissue preservation. Standard excision and Mohs micrographic surgery are the primary treatment options. Nevertheless, as noted in the Cochrane review by Thomson et al.[16], evidence comparing excision strategies—particularly regarding long-term outcomes and optimal margin assessment—remains limited. Achieving clear margins in cosmetically and functionally critical sites continues to be a challenge, often requiring complex reconstruction[17]. LC-OCT has emerged as a promising non-invasive imaging tool to aid preoperative planning. A recent meta-analysis by Razi et al.[18] reported high pooled sensitivity (86.9%) and specificity (91.1%) for detecting malignant skin tumours, including BCC. However, most published studies have focused on lesion-level



Fig. 2. Line-field confocal–optical coherence tomography (LC-OCT)-guided planning, excision, and reconstruction with a paramedian forehead flap. (a) Preoperative imaging. Left: LC-OCT vertical section showing dermal basaloid tumour islands with peripheral clefting beneath the epidermis. Right: corresponding dermatoscopic image with blue marking indicating the clinically estimated tumour margin. (b) Preoperative lesion on the nasal unit. (c) Intraoperative stage with planned lateral margin and deep margin to subcutaneous tissue as appropriate. (d) Intraoperative stage with pedicled forehead flap harvested. (e) Follow-up view after pedicle cutting.

detection rather than its use in guiding surgical decision-making. Evidence specific to its application in head-and-neck oncology is still scarce and largely descriptive.

In this regard, our study represents a novel contribution on the clinical impact of LC-OCT in the preoperative evaluation of BCC in the head and neck region. While patients in both cohorts were broadly comparable in terms of key clinical and tumour characteristics, some differences in baseline variables were observed. The LC-OCT cohort was younger and had slightly larger tumours, reflecting its selection for clinically challenging cases; although a higher proportion of pT2/pT3 lesions was observed, this difference did not reach statistical significance. At the histopathology analysis, the LC-OCT cohort contained fewer aggressive histological subtypes which may confound margin outcomes.

Regarding the primary outcomes, the integration of LC-OCT did not yield statistically significant differences. The observed directional patterns of lower positive histological margins (19.0% vs 24.6%) and recurrence (0% vs 5.2%) in the LC-OCT group should be interpreted cautiously given limited events and cohort differences. These differences may reflect residual confounding and measurement/workflow factors rather than an independent contribution of LC-OCT. However, the inclusion of these non-BCC histotypes may have also limited the apparent effectiveness of LC-OCT, as the technology is primarily optimized for BCC and is less reliable for delineating the margins of SCC or other non-basal lesions[18]. Similarly, of the four cases that presented positive histological margins in the LC-OCT patients, two were recurrent BCC lesions. LC-OCT BCC detection has primarily been evaluated on primary lesions and is less reliable on recurrent lesions. This factor potentially undermines the power of LC-OCT in the overall outcome analysis of our cohort and should be considered in future stratified investigations. Another case of positive histological margins in the LC-OCT concerned a deep margin positivity. In this instance, the lesion was not detected by LC-OCT, possibly due to limitations in penetration depth, which is typically confined to the superficial dermis. The last lesion with positive histological margins in the LC-OCT was located on the lower eyelid margin, where accurate margin assessment was hindered by the complex local anatomy. In this case, intraoperative frozen section analysis revealed residual tumour, underscoring the challenges of applying LC-OCT in certain anatomical subunits (Fig. 1). Finally, the between-cohort differences in positive margins and recurrence should be interpreted in light of histologic case-mix: the historical cohort included a substantially higher proportion of aggressive subtypes, which are characterized by infiltrative growth patterns that contribute to both lateral and deep margin involvement[19].

In terms of secondary outcomes, LC-OCT did not significantly alter the surgical duration, reconstructive approach, or aesthetic results. However, patients in the LC-OCT group underwent surgery with greater frequency under local anaesthesia (73.9% vs 49.4%) and exhibited a trend toward shorter operative times and better cosmetic outcomes (lower mean Manchester score), though these differences did not reach statistical significance. The only statistically significant drawback associated with LC-OCT use was a longer time interval between diagnosis and surgical treatment likely reflecting the logistical complexity of incorporating LC-OCT into preoperative workflows. LC-OCT margin delineation was performed exclusively by a single expert dermatologist (E.C.), which often resulted in longer delays between diagnostic exam and surgery due to the expert's availability, thus representing an additional limitation of the protocol. A non-significant trend was observed toward



Fig. 3. Conventional planning, excision, and retroauricular 'revolving-door' island flap reconstruction. (a) Preoperative clinical appearance. (b) Intraoperative clinical margin assessment. (c) Excision to the subcutaneous plane. (d) Retroauricular revolving-door island flap inset.

greater histologic clearance with LC-OCT, consistent with a targeted 'precision-on-the-safe-side' mapping effect. Due to the small numbers and potential selection/measurement differences, this signal should be interpreted cautiously; a larger, prospective series with standardized margin-distance extraction is needed to determine whether LC-OCT reliably increases clearance without sacrificing tissue. In our multivariate analysis, anatomical risk (H-zone) and aggressive histology were the dominant determinants of lateral margin positivity, consistent with the clinical difficulty of defining subclinical spread in high-risk facial subunits and infiltrative patterns, as reported in literature[20]. LC-OCT use was not associated with a statistically significant reduction in lateral positive margins after adjustment, suggesting that—within the constraints of sample size and workflow—its effect on oncologic margin status may be modest or confounded by case mix. Overall, the model's discrimination (AUC ~0.77) supports its utility for risk stratification, while highlighting subsite and histotype as the clearest targets for preoperative planning refinements (e.g. systematic use of frozen sections, wider planned lateral cuffs, or Mohs referral in selected H-zone/aggressive cases). In the multivariable model, tumour size showed an inverse association with lateral margin positivity, a finding that appears counterintuitive and should be interpreted cautiously. One plausible explanation is that larger lesions may prompt surgeons to deliberately plan wider lateral excisions, thereby reducing the likelihood of peripheral margin involvement. Given the limited number of outcome events, this finding should be regarded as exploratory rather than definitive (Fig. 2).

Taken together, available studies and our findings support LC-OCT as a preoperative planning adjunct rather than as a stand-alone margin-control tool. Previous reports[8–10] have shown its ability to refine incision lines, visualize canonical BCC features, and reduce Mohs stages, though performance remains limited in complex subsites and by shallow imaging depth[21,22], consistent with the impact observed in our cohort (Fig. 3).

A major strength of this study is its real-world design, reflecting the practical integration of LC-OCT into a high-volume, multidisciplinary head-and-neck oncology service. The comprehensive clinical, histological, and surgical dataset enabled evaluation of both oncological and procedural endpoints. However, several limitations must be acknowledged. The retrospective nature of the control group and the prospective selection of clinically challenging lesions for LC-OCT may have introduced selection bias and confounding by indication. Baseline differences between cohorts—including age and histologic subtype distribution—may have influenced outcomes and obscured the independent contribution of LC-OCT. The relatively small sample—particularly in the LC-OCT cohort—limited statistical power and the possibility of a type II error cannot be excluded. In addition, follow-up duration was insufficient to fully capture late events, particularly for long-term endpoints such as recurrence. Finally, the LC-OCT workflow was not optimized: in several cases, the delineation marks had faded by the time of surgery. Future studies should avoid these limitations and leverage recently developed colocalization functions and AI-based LC-OCT tools (Fig. 4).

In conclusion, preoperative LC-OCT was feasible in a real-world head-and-neck BCC treatment pathway but did not independently reduce lateral positive margins. LC-OCT cases showed a non-significant trend towards larger negative lateral clearances and no penalty in operative time or reconstruction profile, but time to surgery was longer, reflecting a multi-institute, specialty-operator, two-day workflow. These findings support LC-OCT as a targeted mapping adjunct rather than as a standalone solution for margin control. Prospective 'LC-OCT to knife in the same day' studies are



Fig. 4. Conventional planning and reconstruction with local flap. (a) Preoperative appearance. (b) Intraoperative marking of excision and local flap design. (c) Flap inset. (d) Early postoperative appearance.

warranted to define clinical benefit and cost-effectiveness.

Ethical approval

Approved by the Ethical Committee for Clinical Research of the University Hospital of Siena (No. 16/2023).

Funding

None.

Data availability

De-identified data underlying the findings are available from the corresponding author on reasonable request.

Competing interests

None.

Acknowledgement. We thank Sophie Alt for her support in the literature review and editing of the manuscript.

Patient consent

Obtained.

References

1. Ferrante di Ruffano L, Dinnes J, Deeks JJ, Chuchu N, Bayliss SE, Davenport C, Takwoingi Y, Godfrey K, O'Sullivan C, Matin RN, Tehrani H, Williams HC, Cochrane Skin Cancer Diagnostic Test Accuracy Group. Optical coherence tomography for diagnosing skin cancer in adults. *Cochrane Database Syst Rev* 2018;**12**(12):CD013189. https://doi.org/10.1002/14651858.CD013189
2. Reddy N, Nguyen BT. The utility of optical coherence tomography for diagnosis of basal cell carcinoma: a quantitative review. *Br J Dermatol* 2019;**180**:475–83. https://doi.org/10.1111/bjd.17201
3. Holm KBE, Nielsen LJ, Lock-Andersen J, Behrendt N, Svensson MS, Themstrup L, Jemec GBE. Optical coherence tomography for presurgical delineation of basal cell carcinomas on the face—a comparison with histopathology. *J Cutan Pathol* 2023;**50**:441–9. https://doi.org/10.1111/cup.14412
4. Dubois A, Levecq O, Azimani H, Davis A, Ogien J, Siret D, Barut A. Line-field confocal time-domain optical coherence tomography with dynamic focusing. *Opt Express* 2018;**26**:33534–42.
5. Suppa M, Fontaine M, Dejonckheere G, Cinotti E, Yélamos O, Diet G, Tognetti L, Miyamoto M, Orte Cano C, Perez-Anker J, Panagiotou V, Trepant AL, Monnier J, Berot V, Puig S, Rubegni P, Malvehy J, Perrot JL, Del Marmol V. Line-field confocal optical coherence tomography of basal cell carcinoma: a descriptive study. *J Eur Acad Dermatol Venereol* 2021;**35**:1099–110. https://doi.org/10.1111/jdv.17078
6. Cinotti E, Brunetti T, Cartocci A, Tognetti L, Suppa M, Malvehy J, Perez-Anker J, Puig S, Perrot JL, Rubegni P. Diagnostic accuracy of line-field confocal optical coherence tomography for the diagnosis of skin carcinomas. *Diagnostics* 2023;**13**:361. https://doi.org/10.3390/diagnostics13030361
7. Gust C, Schuh S, Welzel J, Daxenberger F, Hartmann D, French LE, Ruini C, Sattler EC. Line-field confocal optical coherence tomography increases the diagnostic accuracy and confidence for basal cell carcinoma in equivocal lesions: a prospective study. *Cancers* 2022;**14**:1082. https://doi.org/10.3390/cancers14041082
8. Paradisi A, Cornacchia L, Cappilli S, Abeni D, Federico F, Di Stefani A, Mannino M, Peris K. Preoperative evaluation of high-risk basal cell carcinoma with line-field confocal optical coherence tomography (LC-OCT) reduces Mohs micrographic surgery stage number: a case–control study. *EJC Skin Cancer* 2023;**2**:100015https://doi.org/10.1016/j.ejcskn.2023.100015
9. Deußing M, Eijkenboom QL, Thamm J, Desch A, Fünfer K, Mozaffari M, Wirsching H, Mayer O, Schlingmann S, French LE, Hartmann D, Welzel J, Schuh S, Sattler EC. Unveiling the hidden boundaries: AI-assisted line-field optical coherence tomography margin mapping for precise excision of basal cell carcinoma—step-by-step tutorial. *Skin Res Technol* 2024;**30**:e13594. https://doi.org/10.1111/srt.13594
10. Jacobsen K, Wenande E, Glud M, Haedersdal M, Ortner VK. Line-field confocal optical coherence tomography image markers of basal cell carcinoma in excised Mohs micrographic surgery tissue: a case series. *Dermatol Pract Concept* 2025;**15**:5031. https://doi.org/10.5826/dpc.1501a5031
11. Benedetti S, Frosolini A, Catarzi L, Marsiglio A, Gennaro P, Gabriele G. Impact of the COVID-19 pandemic on the diagnosis and management of non-melanoma skin cancer in the head and neck region: a retrospective cohort study. *Healthcare* 2024;**12**:501. https://doi.org/10.3390/healthcare12040501
12. Dourmishev LA, Rusinova D, Botev I. Clinical variants, stages, and management of basal cell carcinoma. *Ind Dermatol Online J* 2013;**4**:12–7. https://doi.org/10.4103/2229-5178.105456
13. Pogorzelska-Dyrbuś J, Salwowska N, Bergler-Czop B. Dermoscopic pattern of basal cell carcinoma in H- and non-H-zones. *Dermatol Pract Concept* 2023;**13**:e2023125. https://doi.org/10.5826/dpc.1303a125
14. Baker SR. *Local flaps in facial reconstruction e-book*. Paesi Bassi: Elsevier; 2021.
15. The Jamovi project. Sydney, Australia. ⟨https://www.jamovi.org⟩ [Accessed 29 July 2025].
16. Thomson J, Hogan S, Leonardi-Bee J, Williams HC, Bath-Hextall FJ. Interventions for basal cell carcinoma of the skin. *Cochrane Database Syst Rev* 2020;**11**(11):CD003412. https://doi.org/10.1002/14651858
17. Kannan RY, Mathur BS. Perforator flaps of the facial artery angiosome. *J Plast Reconstr Aesthet Surg* 2013;**66**:483–8.
18. Razi S, Kuo YH, Pathak G, Agarwal P, Horgan A, Parikh P, Deshmukh F, Rao BK. Line-field confocal optical coherence tomography for the diagnosis of skin tumors: a systematic review and meta-analysis. *Diagnostics* 2024;**14**:1522. https://doi.org/10.3390/diagnostics14141522
19. Conte S, Ghezelbash S, Nallanathan B, Lefrançois P. Clinical and molecular features of morpheaform basal cell carcinoma: a systematic review. *Curr Oncol* 2023;**30**:9906–28. https://doi.org/10.3390/curroncol30110720
20. Gürsel Ürün Y, Can N, Bağış M, Sarıkaya Solak S, Ürün M. Adequacy of surgical margins, re-excision, and evaluation of factors associated with recurrence: a retrospective study of 769 basal cell carcinomas. *An Bras Dermatol* 2023;**98**:449–59. https://doi.org/10.1016/j.abd.2022.07.005
21. Di Stefani A, Cappilli S, Cuffaro G, Fionda B, Pagliara MM, Paradisi A, Ricci C, Rossi E, Sammarco MG, Schinzari G, Tagliaferri L, Blasi MA, Cinotti E, Moro A, Savino G, Suppa M, Peris K. Line-field confocal optical coherence tomography evaluation of eyelid skin lesions. *Diagnostics* 2023;**13**:3590. https://doi.org/10.3390/diagnostics13233590
22. Donelli C, Suppa M, Tognetti L, Perrot JL, Calabrese L, Pérez-Anker J, Malvehy J, Rubegni P, Cinotti E. Line-field confocal optical coherence tomography for the diagnosis of skin carcinomas: real-life data over three years. *Curr Oncol* 2023;**30**:8853–64. https://doi.org/10.3390/curroncol30100639

Correspondence to: Vittorio Chiantini
Maxillofacial Surgery Unit, University Hospital of Siena, Italy. Tel.: +39 (0)5775 85777.
E-mail: v.chiantini4@gmail.com