



## **Dermoscopy vs. reflectance confocal microscopy for the diagnosis of lentigo maligna**

This is the peer reviewed version of the following article:

*Original:*

Cinotti, E., Labeille, B., Debarbieux, S., Carrera, C., Lacarrubba, F., Witkowski, A.M., et al. (2018). Dermoscopy vs. reflectance confocal microscopy for the diagnosis of lentigo maligna. JOURNAL OF THE EUROPEAN ACADEMY OF DERMATOLOGY AND VENEREOLOGY, 1-8 [10.1111/jdv.14791].

*Availability:*

This version is available <http://hdl.handle.net/11365/1034766> since 2018-02-27T18:40:54Z

*Published:*

DOI:10.1111/jdv.14791

*Terms of use:*

Open Access

The terms and conditions for the reuse of this version of the manuscript are specified in the publishing policy. Works made available under a Creative Commons license can be used according to the terms and conditions of said license.

For all terms of use and more information see the publisher's website.

(Article begins on next page)

## **Dermoscopy versus reflectance confocal microscopy for the diagnosis of lentigo maligna**

E. Cinotti, MD,PhD<sup>1,2</sup>; B. Labeille, MD<sup>1</sup>; S. Debarbieux, MD<sup>3</sup>; C. Carrera, MD,PhD<sup>4</sup>; F. Lacarrubba, MD<sup>5</sup>; A.M. Witkowski, MD, PhD<sup>6</sup>; E. Moscarella, MD<sup>7</sup>; E. Arzberger, MD<sup>8</sup>; H.Kittler, MD<sup>9</sup>; P. Bahadoran, MD,PhD<sup>10</sup>; S. Gonzalez, MD, PhD<sup>11</sup>; P. Guitera, MD,PhD<sup>12</sup>; M. Agozzino, MD<sup>7</sup>; F. Farnetani, MD<sup>6</sup>; R. Hofmann-Wellenhof, MD<sup>8</sup>; M. Ardigò, MD<sup>13</sup>; P. Rubegni, MD, PhD<sup>2</sup>; L. Tognetti, MD<sup>2,14</sup>; J. Łudzik, MD<sup>15</sup>; I.Zalaudek, MD,PhD<sup>8</sup>; G. Argenziano, MD,PhD<sup>7</sup>; C. Longo, MD,PhD<sup>16</sup>; S. Ribero, MD, PhD<sup>17</sup>; J. Malvehy, MD, PhD<sup>4</sup>; G.Pellacani, MD, PhD<sup>6</sup>; F. Cambazard, MD,PhD<sup>1</sup>; J.L. Perrot, MD<sup>1</sup>

<sup>1</sup>Department of Dermatology, University Hospital of St-Etienne, Saint-Etienne, France,

<sup>2</sup>Department of Medical, Surgical and Neurological Science, Dermatology Section, University of Siena, S. Maria alle Scotte Hospital, Siena, Italy,

<sup>3</sup>Departments of Dermatology, Centre Hospitalier Lyon Sud, Pierre Benite, France,

<sup>4</sup>Melanoma Unit, Department of Dermatology, Hospital Clínic de Barcelona, IDIBAPS, Barcelona University, Barcelona, Spain,

<sup>5</sup>Dermatology Clinic, University of Catania, Italy,

<sup>6</sup>Department of Dermatology, University of Modena and Reggio Emilia, Modena, Italy,

<sup>7</sup>Dermatology Unit, Second University of Naples, Nuovo Policlinico, Naples, Italy

<sup>8</sup>Department of Dermatology and Venerology, Medical University of Graz, Graz, Austria,

<sup>9</sup>Department of Dermatology, Medical University of Vienna, Vienna, Austria

<sup>10</sup>Department of Dermatology, Clinical Research Center, Hopital Archet 2, Nice, France,

<sup>11</sup>Medicine and Medical Specialities Department, Alcalá University, Madrid and Dermatology Department, Memorial Sloan-Kettering Cancer Center, New York, USA,

<sup>12</sup>Department of Dermatology, The University of Sydney, Sydney Melanoma Diagnostic Centre and Melanoma Institute Australia, Sydney, New South Wales, Australia,

<sup>13</sup>Clinical Dermatology, San Gallicano Dermatological Institute, Rome, Italy,

<sup>14</sup>Department of Medical Biotechnologies, University of Siena,

<sup>15</sup>Department of Bioinformatics and Telemedicine, Jagiellonian University Medical College, Krakow, Poland,

<sup>16</sup>Dermatology and skin cancer unit, Arcispedale Santa Maria Nuova-IRCCS, Reggio Emilia, Italy

<sup>17</sup>Department of medical sciences, University of Turin, Turin, Italy

This article has been accepted for publication and undergone full peer review but has not been through the copyediting, typesetting, pagination and proofreading process, which may lead to differences between this version and the Version of Record. Please cite this article as doi: 10.1111/jdv.14791

This article is protected by copyright. All rights reserved.

Running head: **Dermoscopy versus confocal microscopy for lentigo maligna**

**Conflict of Interest:** None declared

**Funding sources:** This study was supported in part by a medical educational grant from F. Hoffmann-La Roche.

Corresponding author:

Elisa Cinotti. Dermatology Section, University of Siena, S. Maria alle Scotte Hospital, 53100 Siena, Italy. Tel: 00 33 (0)4.77.82.84.21 Fax: 00 33 (0)4.77.82.84.01; elisacinotti@gmail.com

## **Abstract**

**BACKGROUND:** Several dermoscopic and *in vivo* reflectance confocal microscopy (RCM) diagnostic criteria of lentigo maligna (LM)/lentigo maligna melanoma (LMM) have been identified. However, no study compared the diagnostic accuracy of these techniques.

**OBJECTIVE:** We evaluated the diagnostic accuracy of dermoscopy and RCM for LM/LMM using a holistic assessment of the images.

**METHODS:** 223 facial lesions were evaluated by 21 experts. Diagnostic accuracy of the clinical, dermoscopic and RCM examination were compared. Inter-investigator variability and confidence level in the diagnosis were also evaluated.

**RESULTS:** Overall diagnostic accuracy of the two imaging techniques was good (area under the curve of the sROC function: 0.89). RCM was more sensitive (80%, versus 61%) and less specific (81% versus 92%) than dermoscopy for LM/LMM. In particular RCM showed a higher sensitivity for hypomelanotic and recurrent LM/LMM. RCM had a higher inter-investigator agreement and a higher confidence level in the diagnosis than dermoscopy.

**CONCLUSION:** RCM and dermoscopy are both useful techniques for the diagnosis of facial lesions and in particular LM/LMM. RCM is particularly suitable for the identification of hypomelanotic and recurrent LM/LMM.

Key words: Reflectance confocal microscopy – *in vivo* – tumor – lentigo maligna – face – diagnosis – dermoscopy

## INTRODUCTION

Lentigo maligna (LM)/lentigo maligna melanoma (LMM) is a subtype of melanoma that occurs on chronically sun-exposed skin and mostly on the face. Its clinical diagnosis is often challenging because it shows overlapping features with benign lesions. As it is often large and located on aesthetic and functional areas, non-invasive imaging techniques such as dermoscopy and reflectance confocal microscopy (RCM) are of great interest for its diagnosis<sup>1-3</sup>.

Several dermoscopic<sup>1,4-10</sup> and RCM<sup>2,11</sup> diagnostic criteria of LM/LMM have been identified. However, there are no evaluations of the diagnostic accuracy of these two non-invasive skin imaging techniques for LM/LMM using a holistic approach to image evaluation by experts instead of single diagnostic criteria. Moreover, there is no study that compares these two single techniques and the clinical examination.

## MATERIALS AND METHODS

### *Selected lesions*

We included all consecutive clinically equivocal facial lesions in clinical differential diagnosis with LM/LMM, acquired during the years 2011-2015 at the University Hospital of Saint-Etienne (France), with available clinical, dermoscopic and RCM images and with histopathologic diagnosis.

### *Instruments and acquisition procedure*

Images were acquired by 3 experts of non invasive skin imaging (JLP, BL or EC). Dermoscopy was performed with the PowerShot® G7 camera (Canon Powershot®, Canon, New York, USA) combined with the FotoFinder Systems (FotoFinder Systems GmbH, Bad Birnbach, Germany). *In vivo* RCM examination was carried out with the hand-held VivaScope 3000® camera (Caliber Imaging and Diagnostics, New York, USA, distributed in Europe by MAVIG GmbH, Munich, Germany) which uses a laser with a wavelength of 830 nm and images up to 250 µm of depth. Each RCM image corresponds to a horizontal 920 µm x 920 µm section of the skin at a selected depth with a lateral resolution of 1 µm and axial resolution of 3–5 µm. Only images considered relevant for the diagnosis by two out of the three investigators were captured by RCM. Images of different depths (epidermis, dermal-epidermal junction and dermis) were always present.

### *Image evaluation*

Clinical, dermoscopic and RCM images were evaluated by 21 independent experts in non-invasive skin imaging in order to assess the diagnosis (benign or malignant) blindly to the histological diagnosis. 15 investigators evaluated the clinical and dermoscopic images, 12 investigators evaluated the RCM images and 6 investigators evaluated both the clinical, dermoscopic and RCM images. This distribution of roles was based on the expertise of the individual investigators.

The only provided anamnestic information was the age of the patient. Clinical images were provided together with dermoscopic or RCM images. In order to avoid an influence of dermoscopy information during RCM evaluation or the contrary, the numbering of dermoscopic images and RCM was different and the investigators that performed both RCM and dermoscopy evaluations performed the dermoscopy and RCM evaluations on different days. The evaluation of the clinical images was performed before dermoscopy evaluation. Dermatologists from the University of Saint-Etienne were excluded from the role of evaluators.

Investigators were asked 1) to state if the lesions were benign or malignant on the basis of the clinical or dermoscopic or RCM images, 2) to suggest the most likely diagnosis based on an overall evaluation of the images ("holistic approach"), 3) to point out if the diagnosis was uncertain and if a biopsy was necessary (level of confidence in the diagnosis) and 4) to declare if the images were sufficient for correct evaluation (poor quality of dermoscopic images or too few RCM images). Moreover, the presence of three RCM features was evaluated: 1) large roundish cells in the epidermis (i.e. pagetoid cells), 2) large dendritic cells in the epidermis and 3) follicular localization of atypical cells (i.e. large dendritic and large roundish cells).

### *Ethical considerations*

This study received the approval from the Ethical Committee of the University Hospital of Saint-Etienne (Institutional review board number 672016/CHUSTE).

### *Statistical analysis*

Sensitivity and specificity of the clinical, dermoscopic and RCM diagnosis for different skin lesions were calculated for each investigator and for all investigators (mean value, range, standard deviation). Overall diagnostic accuracy for malignancy and LM/LMM was measured by the area under the curve (AUC) for the sROC function. Diagnostic odds ratio for malignancy and LM/LMM of dermoscopy and RCM were also calculated.

The concordance of dermoscopy or RCM with the histological diagnosis (percentage of cases with the same diagnosis), the level of confidence in performing the diagnosis (percentage of images for which the level of confidence was high) and the number of cases with good image quality (percentage of cases for which the quality of the images was considered good in order to perform the diagnosis) were also calculated.

Inter-investigator agreement on RCM and dermoscopic image quality and on the presence of RCM diagnostic criteria was evaluated by the kappa of Fleiss coefficient.

## RESULTS

### *Demographic characteristics of the studied population and histological diagnoses*

The study population comprised a total of 201 patients, corresponding to 96 women and 105 men (mean age of 70.9 years, range 29-97). 223 lesions were evaluated: 115 LM/LMM (including 92 LM and 23 LMM and 17 recurrences, 1 amelanotic and 17 hypomelanotic cases), 20 basal cell carcinomas (BCCs), 37 solar lentigines (SL), 23 seborrheic keratoses (SK), 15 pigmented actinic keratosis (PAK), 8 nevi, 2 lichenoid keratoses, 2 scars and 1 pigmented Bowen's disease.

### *Diagnostic accuracy of dermoscopy and reflectance confocal microscopy for malignancy*

Overall diagnostic accuracy for malignancy and LM/LMM measured by AUC was good and equal (AUC 0.86 and 0.89 respectively) for dermoscopy and RCM (Fig. 1). The overall mean concordance with histological diagnoses of facial lesions was higher (67%, range 55-72, SD 5) for RCM than dermoscopy (62%, range 49-73, SD 7). The mean sensitivity for malignancy of the clinical, dermoscopic and RCM examinations was 72% (range 52-85, SD 8), 69% (range 51-86, SD 10) and 84% (range 75-92, SD 5) respectively; the mean specificity for malignancy of the clinical, dermoscopic and RCM examinations were 78% (range 60-91, SD 8), 85% (range 74-95, SD 6) and 75% (range 62-84, SD 6) respectively. Diagnostic odds ratio are reported in Figure 2. Mean sensitivity and specificity of the dermoscopic and RCM evaluations for the different facial lesions are reported in Table 1. RCM was more sensitive and less specific than dermoscopy for LM/LMM. Considering only the hypomelanotic/amelanotic LM/LMM and LM/LMM recurrence, the difference in sensitivity was even more pronounced (Table 1). In case of invasive LM (i.e. LMM) both RCM and dermoscopy increased their sensitivity (82%, range 70-87 SD 5 for RCM versus 69%, range 43-87, SD 14 for dermoscopy).

### *Investigator's diagnostic level of confidence*

Investigators declared to have a high level of confidence in the dermoscopic and RCM diagnosis in a mean of 56% (range 26-78, SD 14) and 66% (range 46-79, SD 10) of cases respectively.

### *Evaluation of the image quality*

The quality of RCM and dermoscopic images was considered good for the diagnosis in 81% (range 57-96, SD 11) and 87% (range 78-92, SD 8) of cases respectively.

If we considered only the cases for which all investigators found a sufficient quality of the images (91 dermoscopic and 63 RCM cases) the mean sensitivity and specificity for LM/LMM were 72% (range 41-89, SD 16) and 96% (range 49-73, SD 8) for dermoscopy and both 80% (range 61-89, SD 7 and range 61-89, SD 8) for RCM respectively.

### *Reflectance confocal microscopy features*

Large roundish pagetoid cells, large dendritic cells in the epidermis and a follicular localization of atypical cells were found in 37% (range 9-70%, SD 20), 81% (range 66-91%, SD 9) and 62% (range 55-75%, SD 8) of LM/LMM and in 5% (range 1-13%, SD 4), 13% (range 8-20%, SD 4), and 7% (range 3-11%, SD 2) of benign lesions respectively.

### *Inter-investigator agreement*

The inter-investigator agreement is reported in Table 2.

## DISCUSSION

This study showed a good and similar diagnostic accuracy for facial LM/LMM of both dermoscopy and RCM. Interestingly, RCM was more sensitive than dermoscopy for the diagnosis of facial malignancy (represented mainly by LM/LMM in our study) and LM/LMM and especially hypomelanotic and recurrent LM/LMM, whereas dermoscopy was more specific. These results could have been derived by a different attitude between RCM and dermoscopy readers. In fact, it seems that RCM readers had a threshold that maximized sensitivity (most readings are on the right upper part of the sROC curve) and that most dermoscopy readers chose a threshold that maximized specificity (more readings are on the left lower part of the sROC curve). The different thresholds could be related to intrinsic differences of the two techniques. In fact the difference in sensitivity and specificity was found for the overall evaluations and was also confirmed by the evaluations of the single investigators that analyzed both dermoscopic and RCM images. Transposed to practical, this concept highlights that whereas dermoscopy gives clear pictures for patterns related to benign lesions, features for LM/LMM are not always clear. On the other hands, RCM clues of LM/LMM are easy to be identified (returning a confident diagnosis of malignancy in most cases), but in some instances these features are also seen in benign lesions.

Most cases that were considered benign under dermoscopy and malignant under RCM corresponded to early LM with a dermoscopic aspect of SL, SK or PAK. In these cases dermoscopic features of LM/LMM were barely visible, whereas RCM showed hyper-reflective pagetoid cells (Fig. 3). Therefore, RCM could be useful in order to identify an initial proliferation of few malignant melanocytes that does not manifest with the corresponding



Accepted Article

dermoscopic changes. As showed by our study, this is particularly interesting in case of recurrent or hypomelanotic LM/LMM where atypical cells less frequently have a dermoscopic expression. However, it should be noticed that the identification of malignant melanocytes in our study could have been facilitated by the fact that the images were captured by RCM experts.

Surprisingly, also the clinical examination alone was associated with a good diagnostic accuracy, showing a slightly better mean sensitivity for malignancy than dermoscopy. Therefore, our study supported that clinical criteria are extremely important for LM/LMM<sup>9,12</sup>. In particular, the 20 lesions that were clinically correctly diagnosed as LM/LMM by all the investigators were intensively pigmented and/or raised and/or large and/or isolated.

The overall concordance with histologic diagnoses for all the facial lesions was much higher for RCM than for dermoscopy. However, different from our expectations, RCM showed a lower specificity than dermoscopy. This fact was probably related to the presence of hyper-reflective dendritic Langerhans cells and of large hyper-reflective keratinocytes mistaken for neoplastic melanocytes in the epidermis of misdiagnosed benign lesions (Fig. 4). It should also be considered that the RCM evaluation was made more difficult by the fact that it was performed in blind to dermoscopy and with preselected images of the hand-held device, situations which do not occur in the clinical practice. Moreover, the evaluation of hand-held RCM registered images did not allow to exactly localize the different cells (rendering more difficult the distinction among melanocytes, pigmented keratinocytes and inflammatory cells) and quantify atypical cells (because the lesions were not entirely visible), with the possibility of overestimating their presence. Concerning RCM features of LM/LMM, large pagetoid cells were mainly dendritic (81%) than roundish (37%) differently from what has been previously reported in LM/LMM<sup>2</sup>. Interestingly, a follicular localization of atypical cells, which is a clue for LM/LMM<sup>2</sup>, was found in more than half of LM/LMM.

Notably, the inter-observer agreement was strong for the presence of large dendritic cells but fair for the presence of large roundish pagetoid cells. The different evaluation of the size could be responsible for this variability. In fact the size of the cells is important under RCM because small hyper-reflective dendritic cells are in favor of Langerhans cells and small hyper-reflective roundish cells are in favor of pigmented keratinocytes, whereas large hyper-reflective dendritic or roundish cells are in favor of malignant melanocytes. However, in the clinical practice numerous dendritic cells are considered malignant independently from their size, whereas the concept of large roundish cells can vary depending on the observers (>20  $\mu\text{m}$  or larger or the double than a basal keratinocyte). This study thus highlighted the need to establish a consensus on this issue. A solution to this problem would be to insert a scale bar in the confocal images in order to measure cell size directly.

Our study also confirmed the difficulty of diagnosing PAK<sup>13,14</sup>, with both dermoscopy and RCM showing low diagnostic accuracy. Concerning the facial lesions different from LM/LMM, SK, SL and PAK, sensitivity and specificity of RCM and dermoscopy were similar.

The images of our study were not initially acquired with the purpose of an external evaluation, but only for clinical documentation. For this reason investigators were asked to judge image quality. In most cases the evaluators judged that the provided RCM and dermoscopic images were sufficient for the diagnosis. Interestingly, the inter-investigator agreement on the quality of the images was fair. This means that there are no standards for



the image quality. In particular, protocols of RCM image acquisition have been described for the stationary VivaScope 1500® reflectance confocal microscope for use in teledermatology but image acquisition standards for the hand-held VivaScope 3000® reflectance confocal microscope should be validated for potential future usage of the images for an external reading platform. Overall, the RCM cases judged insufficient represented few areas of one lesion, whereas the dermoscopic images judged insufficient corresponded to only one part of a large lesion or had air bubbles or scales. If we considered only the cases for which all investigators found a sufficient quality of the images (91 dermoscopic and 63 RCM cases), dermoscopy but not RCM highly increased their diagnostic accuracy for LM/LMM.

The level of confidence of the investigators in the diagnosis was higher with RCM than with dermoscopy. This indicates that dermoscopy more often leaves doubts in case of facial lesions and requires additional biopsies in order to confirm the diagnosis, whereas RCM provides a type of information closer to the gold standard of histology, supplying more elements to make a more confident diagnosis. This is in accordance with the fact that RCM readers had a threshold that maximized sensitivity and most dermoscopy readers chose a threshold that maximized specificity. Moreover, the evaluations of the RCM readers deviated less than the evaluations of the dermoscopy readers suggesting that RCM features could be more objective and easy to be identified than dermoscopic ones.

In conclusion, this study showed that both dermoscopy and RCM are good techniques for the identification of LM/LMM. Their use should be complementary in order to achieve the best accuracy. In particular RCM might also be considered for dermoscopically non suspicious facial lesions considered for aesthetic/physical treatments, in order to detect early or difficult to diagnose LM and avoid mistreatments. However, it should be noticed that RCM can over-diagnose LM in case of SK, SL and PAK presenting dendritic cells. In case, long-term digital follow-up could be proposed to rule out a featureless early melanoma.

Further investigations should be performed in order to compare dermoscopy and RCM alone with the combination of the two techniques which probably increases their diagnostic accuracy as it has been already reported in other studies not limited to facial lesions.

**Acknowledgment:**

**Funding/Support:** This study was supported in part by a medical educational grant from F. Hoffmann-La Roche. The Funding/Sponsor was not involved in the design and conduct of the study, was not involved in the collection, management, analysis and interpretation of data, was not involved in the preparation, review, or approval of the manuscript and was not involved in the decision to submit the manuscript for publication

**Financial Disclosure:** None reported.

## References

1. Pralong P, Bathelier E, Dalle S, Poulalhon N, et al. Dermoscopy of lentigo maligna melanoma: report of 125 cases. *Br J Dermatol*. 2012;**167**:280-7.
2. Guitera P, Pellacani G, Crotty KA, et al. The impact of in vivo reflectance confocal microscopy on the diagnostic accuracy of lentigo maligna and equivocal pigmented and nonpigmented macules of the face. *J Invest Dermatol*. 2010;**130**:2080-1.
3. Borsari S, Pampena R, Lallas A, et al. Clinical Indications for Use of Reflectance Confocal Microscopy for Skin Cancer Diagnosis. *JAMA Dermatol*. 2016;**152**:1093-8.
4. Cengiz FP, Cengiz AB, Emiroglu N, et al. Dermoscopic and clinical features of head and neck melanoma. *An Bras Dermatol*. 2015;**90**:488-93.
5. Schiffner R, Schiffner-Rohe J, Vogt T, et al. Improvement of early recognition of lentigo maligna using dermoscopy. *J Am Acad Dermatol*. 2000;**42**:25-32.
6. Stolz W, Schiffner R, Burgdorf WHC. Dermoscopy for facial pigmented skin lesions. *Clin Dermatol*. 2002;**20**:276-8.
7. Sahin MT, Oztürkcan S, Ermertcan AT, Güneş AT. A comparison of dermoscopic features among lentigo senilis/initial seborrheic keratosis, seborrheic keratosis, lentigo maligna and lentigo maligna melanoma on the face. *J Dermatol*. 2004;**31**:884-9.
8. Goncharova Y, Attia EAS, Souid K, Vasilenko IV. Dermoscopic features of facial pigmented skin lesions. *ISRN Dermatol*. 2013;**2013**:546813.
9. Lallas A, Tschandl P, Kyrgidis A, et al. Dermoscopic clues to differentiate facial lentigo maligna from pigmented actinic keratosis. *Br J Dermatol*. 2016;**174**:1079-85.
10. Tschandl P, Rosendahl C, Kittler H. Dermoscopy of flat pigmented facial lesions. *J Eur Acad Dermatol Venereol*. 2015;**29**:120-27.
11. de Carvalho N, Farnetani F, Ciardo S, et al. Reflectance confocal microscopy correlates of dermoscopic patterns of facial lesions help to discriminate lentigo maligna from pigmented nonmelanocytic macules. *Br J Dermatol*. 2015;**173**:128-33.
12. Todorovic-Zivkovic D, Argenziano G, Lallas A, et al. Age, gender, and topography influence the clinical and dermoscopic appearance of lentigo maligna. *J Am Acad Dermatol*. 2015;**72**:801-8.

13. Akay BN, Kocyigit P, Heper AO, Erdem C. Dermatoscopy of flat pigmented facial lesions: diagnostic challenge between pigmented actinic keratosis and lentigo maligna. *Br J Dermatol*. 2010;**163**:1212-17.
14. Moscarella E, Rabinovitz H, Zalaudek I, et al. Dermoscopy and reflectance confocal microscopy of pigmented actinic keratoses: a morphological study. *J Eur Acad Dermatol Venereol*. 2015;**29**:307-14.

#### **Legend for figures**

**Figure 1 Overall diagnostic accuracy for malignancy and lentigo maligna of dermoscopy and reflectance confocal microscopy.** The area under the curve (AUC) of the summary receiver operating characteristics (sROC) is shown; red dots indicate the diagnostic accuracy for each investigator.

**Figure 2 Diagnostic odds ratio (OR) for malignancy and lentigo maligna of dermoscopy and reflectance confocal microscopy.** Red dots indicate the diagnostic odds ratio (OR) for each investigator.

**Figure 3 Lentigo maligna that was diagnosed as a benign lesion under dermoscopy by all the investigators.** Clinical (a, black arrow), dermoscopic (b) and reflectance confocal microscopy (RCM) (c) aspect. Dermoscopy shows only initial signs of lentigo maligna (red arrow, brown semicircles). RCM shows numerous hyper-reflective pagetoid cells (red arrow) around hair follicles (yellow asterisk) and pigmented keratinocytes (yellow circle).

**Figure 4 Benign lesions that were diagnosed as lentigo maligna under reflectance confocal microscopy by all investigators.** Clinical (a,d, black arrow), dermoscopic (b,e) and reflectance confocal microscopy (c,f) aspect of pigmented actinic keratosis (a-c) and solar lentigo (d-f). Hyper-reflective dendritic cells corresponding to Langerhans cells are numerous in the epidermis (c,f, red arrow) and mimic malignant melanocytes.

**Table 1 Sensitivity and specificity for the different facial lesions of dermoscopy and reflectance confocal microscopy.**

	Dermoscopy		RCM	
	Sensitivity	Specificity	Sensitivity	Specificity
LM/LMM				
Mean (%)*	61	92	80	81
Range	35-83	84-98	66-90	73-90
SD	15	5	7	5
Hypomelanotic LM/LMM				
Mean (%)*	37	92	69	80
Range	nov-72	84-98	50-90	62-90
SD	19	5	13	8
Recurrent LM/LMM				
Mean (%)*	55	56	75	46
Range	29-82	0-100	59-94	0-50
SD	17	25	11	14
Basal cell carcinoma				
Mean (%)*	81	98	82	97
Range	70-90	95-100	65-95	94-99
SD	5	2	8	2
Solar lentigo				

Mean (%)*	60	87	51	93
Range	43-76	80-93	35-70	84-97
SD	11	4	9	3
Seborrheic keratosis				
Mean (%)*	81	93	62	95
Range	65-100	84-99	35-83	92-98
SD	10	4	13	2
Pigmented actinic keratosis				
Mean (%)*	30	94	17	96
Range	0-55	89-99	0-40	92-100
SD	16	3	11	3
Nevus				
Mean (%)*	53	98	54	99
Range	13-88	97-100	25-88	97-100
SD	21	1	23	1

\*mean value of all the investigators; sensitivity and specificity have been calculated for the specific diagnoses having in the differential diagnosis both benign and malignant lesions

LM/LMM: lentigo maligna/ lentigo maligna melanoma; RCM: reflectance confocal microscopy; SD: standard deviation

**Table 2 Inter-investigator agreement**

	Agreement	Fleiss Kappa	SE	95%CI
Dermoscopy image quality	poor	0.1931	0.0082	0.1769 - 0.2093
RCM image quality	fair	0.3133	0.0065	0.3005 - 0.3261
Large roundish pagetoid cells	fair	0.2870	0.0082	0.2709 - 0.3031
Large dendritic cells in the epidermis	strong	0.6265	0.0082	0.6104 - 0.6426
Follicular localization of atypical cells	moderate	0.5624	0.0082	0.5463 - 0.5785

RCM: reflectance confocal microscopy; SE: standard error

**Abbreviation and acronym list:**

AUC: area under the curve

BCC: basal cell carcinomas

LM: lentigo maligna

LMM: lentigo maligna melanoma

OR: odds ratio

PAK pigmented actinic keratosis

RCM: reflectance confocal microscopy

SD: standard deviation

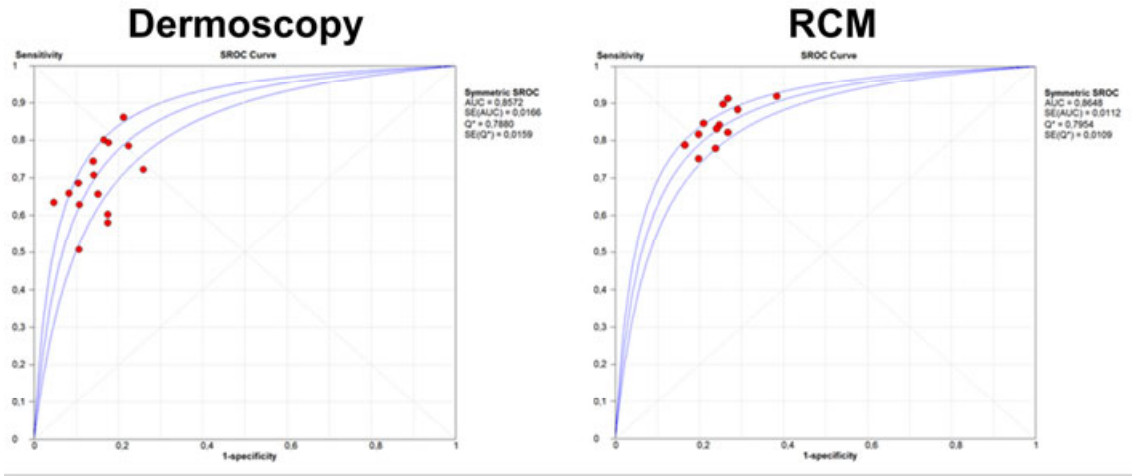
SE: standard error

SK seborrheic keratosis

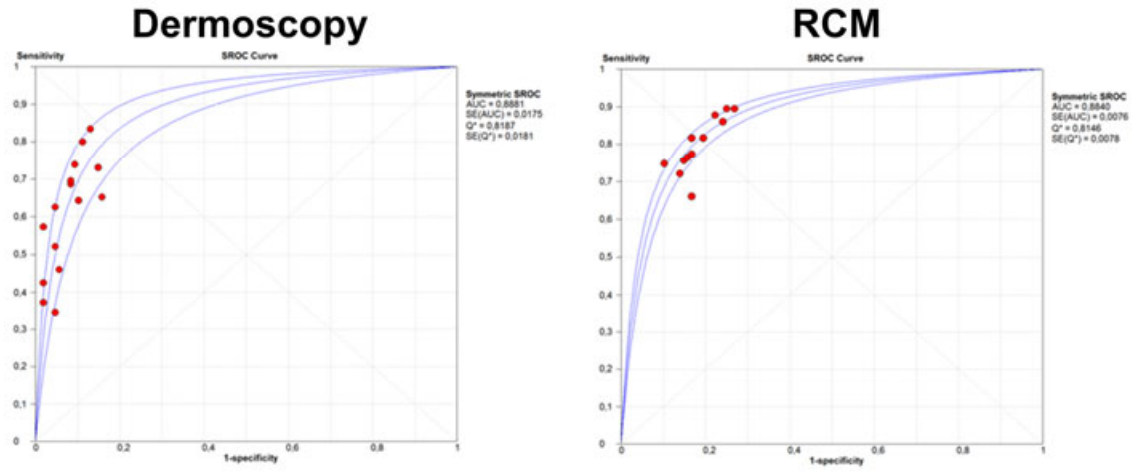
SL: solar lentigo

sROC: summary receiver operating characteristics

# MALIGNANCY



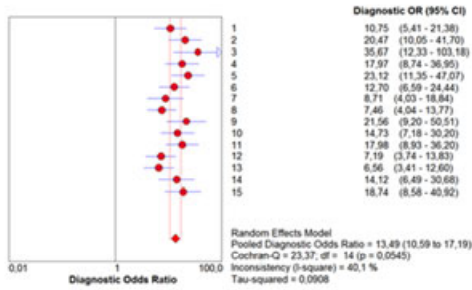
# LM/LMM



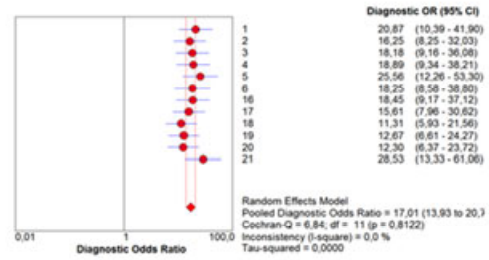


## MALIGNANCY

### Dermoscopy

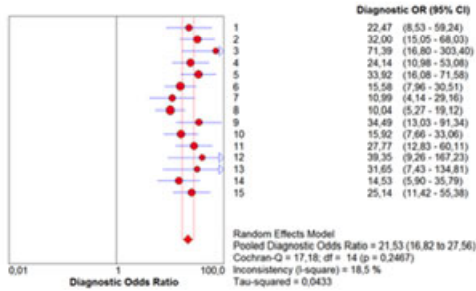


### RCM



## LM/LMM

### Dermoscopy



### RCM

