



## Robotic-assisted thoracoscopy thymectomy for juvenile myasthenia gravis

F. Grasso<sup>\*</sup>, L. De Leonibus, M. Bertozzi, M. Sica, R. Angotti, L. Luzzi, F. Molinaro, M. Messina, P. Paladini

Università Degli Studi di Siena, Italy

### ARTICLE INFO

#### Keywords:

Thyme  
Myasthenia gravis  
Pediatric surgery  
Robot-assisted thoracoscopic thymectomy  
Juvenile myasthenia gravis

### ABSTRACT

**Introduction:** Juvenile myasthenia gravis (JMG) is a rare debilitating and potentially fatal autoimmune disease, with unclear pathogenesis. Surgical immunomodulation with thymectomy has been repeatedly demonstrated to be a safe and effective treatment for JMG in both adult and pediatric patients. In the last few years, minimally invasive approach and above all robotic assisted thoracoscopy, replaced sternotomy which is widely used in adult patients. We report our experience in a case of robot-assisted thoracoscopic thymectomy approach in a 12 years old boy for juvenile myasthenia gravis (JMG).

**Case report:** Procedure was performed with the Da Vinci surgical robot (Xi) using left-sided approach. Left lung was kept out from mechanic ventilation. A 8 mm port for the 3-D camera was introduced on the V intercostal space on the anterior axillary line. Others two 8mm thoracic ports were placed under vision after the induction of a low-pressure pneumothorax, respectively on the midaxillary line on the III intercostal space and on the parasternal space on the V intercostal space. Bulk resection of gland was made using Maryland grasper and Harmonic scalpel, starting at level of the left pericardiophrenic angle and continuing cranially. Thymus was unstuck from the posterior face of the sternum until the right pleura releasing lower thymic horns. After that, contralateral right-side thymectomy was continued into the neck to include the upper horns and finally it was removed with an endocatch bag. Histopathological examination showed a benign thymic hyperplasia. There were no perioperative and postoperative complications. The discharge was on IV post-operative day. After thymectomy, patient reported an improvement in symptoms and stopped medical therapy with pyridostigmine.

**Conclusions:** VATS and Robotic thoracoscopic thymectomy have increasingly taken hold in recent years. The surgical treatment offered to patient an improvement in clinical status. Surgery by robotic assistance has demonstrable advantages, including three-dimensional visualization and articulating instruments. Left lateral approach provided excellent visualization of the thymic veins, anomalous vessels and phrenic nerves. Three-dimensional visualization as well as articulating arms greatly facilitated the dissection compared with standard thoracoscopic technique. In Literature very few series of robotic approach for surgical treatment of JMG in children are reported, for these reasons further studies are needed.

### 1. Introduction

Juvenile myasthenia gravis (JMG) is a debilitating and potentially fatal autoimmune disease that occurs with an incidence of 0.9–2.2 cases per million person-years [1]. Given its rarity, treatment strategies for JMG largely stem from the experience in adults with myasthenia gravis using acetylcholinesterase inhibitors and immunomodulatory therapies [2].

Despite uncertainties regarding the exact pathogenesis of myasthenia gravis (MG), it is generally agreed that the thymus plays a central role in the disease [3]. Surgical immunomodulation with thymectomy

has been repeatedly demonstrated to be safe and effective treatment for myasthenia gravis (MG) in both, adult and pediatric patients [4]. This treatment was inadvertently introduced in 1911 when thymectomy was performed as an attempted remedy of hyperthyroidism and also in myasthenia gravis cases. Post-operatively, while hyperthyroid state persisted, myasthenic symptoms improved [5]. Traditionally, thymectomies have been performed by either a median sternotomy or trans-cervical approach in both pediatric and adult patients. Transsternal thymectomy has been historically preferred, as it is thought to allow for a more complete resection of the diseased thymus [6]. However the advantages of minimally invasive approach to thymectomy,

<sup>\*</sup> Corresponding author.

E-mail address: [francesco.grasso@student.unisi.it](mailto:francesco.grasso@student.unisi.it) (F. Grasso).

<https://doi.org/10.1016/j.epsc.2020.101541>

Received 27 May 2020; Received in revised form 14 June 2020; Accepted 15 June 2020

Available online 30 July 2020

2213-5766/© 2020 Published by Elsevier Inc. This is an open access article under the CC BY-NC-ND license (<http://creativecommons.org/licenses/by-nc-nd/4.0/>).

video-assisted (VATS) or robotic-assisted thoracoscopy, have increasingly taken hold in recent years [7]. We report a case of robot-assisted thoracoscopic thymectomy approach in a child with juvenile myasthenia gravis.

## 2. Case report

A 12-year-old male child with anterior mediastinal mass was referred to our Department of pediatric Surgery in Siena. In the previous 5 months, he presented rhinolalia, dysarthria, asthenia, impaired communication skills, dyspnea and weight loss, about 6 kg in few weeks, symptoms suggestive of bulbar muscle weakness. On the basis of specific clinical symptoms, neurophysiological findings and acetylcholine receptor antibody (anti-AChR) test positive, diagnosis of JMG was made. He was assigned to Group II according to Osserman and Genkins disease classification (Table 1). Subsequent chest radiograph and magnetic resonance imaging (MRI) chest revealed homogenous enlargement in the anterior mediastinum suggestive of hypertrophied thymus, dimension 100×50 × 15mm, without any other abnormalities. Daily medical therapy in the form of oral pyridostigmine, 90 mg every 4 hours, was initiated. The child had good compliance to medication, his generalized weakness improved so he was scheduled for robotic-assisted thoracoscopic thymectomy. Duration of surgical procedure was 90 minutes. After surgery he was transferred in the intensive care department for the first 24 hours, then he was transferred into pediatric surgery department. There were no perioperative and postoperative complications. Urinary catheter was removed in first postoperative day, thoracic drainage (30 Ch) was removed after 48 hours, and central venous catheter at 72 hours. He has no fever during hospital stay and antibiotic treatment was not needed. Analgesic therapy was based on morphine for the first 2 days on postoperative period, switched with paracetamol after that. Feeding was gradually resumed. Hospital stay was of 4 days, time to return to normal activities was about 10 days. Histopathological examination reported a benign thymic hyperplasia (Fig. 1) and mediastinal tissue biopsies showed no pathological abnormalities. Follow-up was performed by the neurologist. One month postoperatively, at the surgical follow-up, he reported an improvement in symptoms and reduction of dosage of pyridostigmine. Two months postoperatively, the neurological follow-up reported a clear improvement in his basic condition. He was appointed to Class I according to De Filippi classification of remission because he was totally asymptomatic and he stopped pyridostigmine administrations (Table 2).

### 2.1. Surgical technique

Patient was positioned in a supine position with a 30° tilt towards the right side. Right lung mechanic ventilation was established by mainstem intubation and left lung was kept out. Whole thymectomy was performed by a left-sided approach. Through an incision on the fifth intercostal space on the anterior axillary line, a 8 mm port for the 3-D camera was introduced. A low-pressure pneumothorax was used. Carbon dioxide was inflated in the hemithorax to improve exposure, achieving a clear view within the pleural cavity and enlarging mediastinal space. It allowed an easier dissection. After that, others two incisions were performed, respectively on the midaxillary line on the third intercostal space and on the parasternal region on the fifth intercostal space and two 8mm thoracic ports were inserted (Fig. 2). An assistant surgeon was needed at surgical table to help the first surgeon for setting

up surgical accesses and managing instruments during the whole surgery time. Da Vinci surgical robot (Xi) was used to perform a total thymectomy with resection en bloc of all thymic tissue. Once the robot was docked, a Maryland grasper was placed through the left working port and harmonic scalpel through the right one. Dissection began at the level of the left pericardiophrenic angle and continued cranially, following the anterior border of the phrenic nerve, until all the mediastinal tissue was isolated from it. Subsequently, thymic gland was dissected from the posterior wall of the sternum until the right pleura was found and lower thymic horns were dissected. Left lateral approach provided excellent visualization of the thymic veins that drain into the left innominate vein. Contralateral right-side dissection was undertaken in an inferomedial to supero-lateral way, taking great care to preserve the right phrenic nerve. Three-dimensional visualization as well as articulating arms greatly facilitated this time of the dissection compared with standard thoracoscopic techniques. Dissection was continued into the neck, including the upper horns of the gland. Once the dissection was completed, after biopsy of mediastinal adipose tissue, robot was undocked and thymus was removed with an endocatch bag through the upper port which has been previously enlarged (Fig. 3). Left lung was allowed to re-inflate, and air in the pleural space was evacuated thanks to the positioning of a pleural drainage, prior to closure of the others incisions in layers.

## 3. Discussion

Myasthenia gravis (MG) is an autoimmune disease characterized by production of antibodies against acetylcholine receptors (AChR) in the neuromuscular junction. In childhood, this disease presents into two forms, transient neonatal MG and juvenile MG (JMG). JMG clinically associated with easy muscular fatigability before the age of 19 years, is diagnosed by clinical presentation supported by laboratory assessment of antibodies (predominantly AChR, but also muscle-specific kinase MuSK) and neuromuscular testing to evaluate the electrodecrement on repetitive nerve stimulation [8]. Given its rarity, treatment strategies for JMG largely stem from the experience in adults with myasthenia gravis using acetylcholinesterase inhibitors and immunomodulatory therapies [2]. Long-term administration of steroids and immuno-suppressant treatments has a number of significant side effects in children, including decreased growth velocity, diabetes, hyperlipidemia, central obesity, immunocompromised state, and pathologic bone fractures [9]. Thymectomy for patients with seropositive JMG has been evaluated and has been found to be associated with improved remission rates and minimized of medical therapy dosage and duration. Therefore, thymectomy may have a role for children who are unresponsive to medical therapy or who cannot undergo standard immunosuppression, although long-term effects of thymectomy in children are however unclear [10]. The role of thymectomy in prepubertal age, especially in very young children is still controversial because of thymus gland role in the development of our immune system with possible immunological alterations [11]. Up to now, there has been no evidence of negative effects of thymectomy on T-cell function and acquired immune function. Furthermore, any procedure in which sternotomy is needed for thymectomy, later in life redo procedure would probably be associated with other complications [12]. In any case all patients, barring rare exceptions with MG and thymoma should undergo surgery to remove tumor [13]. Thymectomy in pediatric population, performed in the centers with appropriate experience is being accomplished with low rates of morbidity and zero mortality [4]. Therefore, a long follow-up is required to evaluating the effect of thymectomy in JMG, because of a gradual response standard outcome measure for adults comprised a period of at least 1 year (Myasthenia Gravis Foundation of America post-operation status, MGFA-PIS) [14]. Osserman and Genkins criteria are used to classify the severity of disease preoperatively while the status on post-operatively is assessed by using DeFilippi's classification. Traditionally, thymectomies have been performed by either a median sternotomy or

**Table 1**  
Disease classification preoperatively. Osserman and Genkins criteria.

Group I	Ocular symptoms
Group IIA	Mild, generalized symptoms (including bulbar)
Group IIB	Moderate generalized symptoms
Group III	Acute, fulminating symptoms



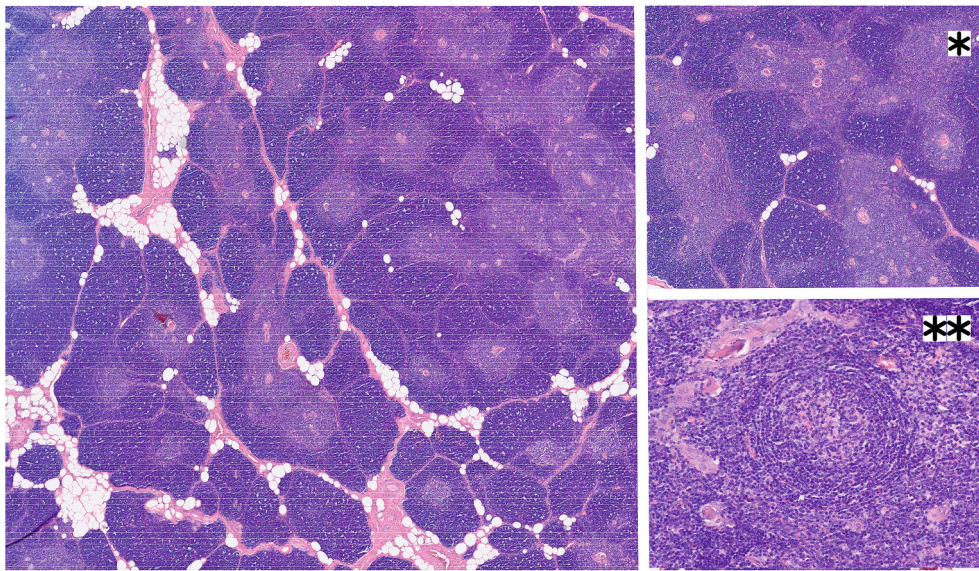


Fig. 1. Microscopic aspect shows a benign thymic hyperplasia.

**Table 2**  
DeFilippi classification of postoperatively remission.

Class 1	Complete remission, no medication requirements
Class 2	Asymptomatic; decreased medication requirements
Class 3	Improvement in symptoms; decreased medication requirements
Class 4	No change in symptoms or medication requirements
Class 5	Worsening symptoms

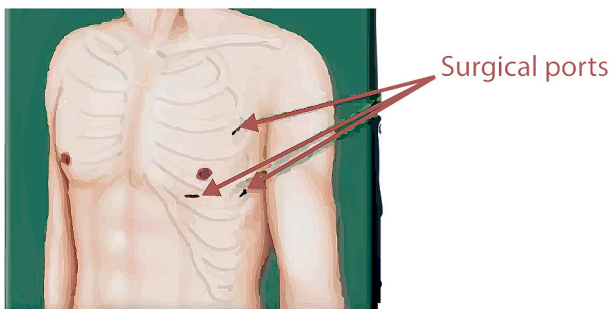


Fig. 2. Surgical ports performed for left approach robotic surgery.

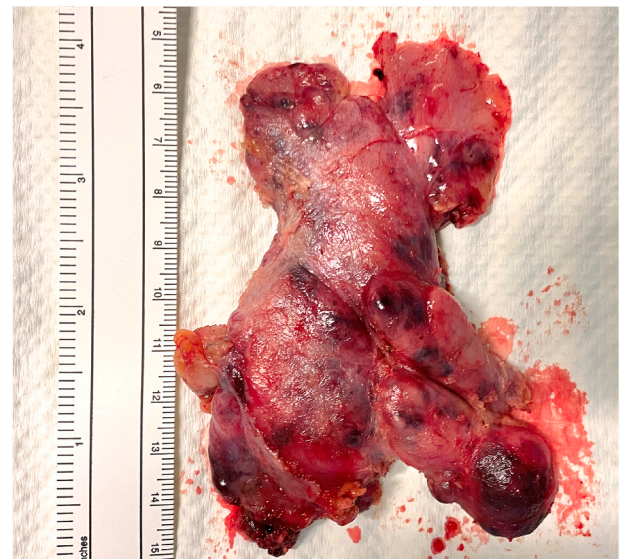

Fig. 3. Macroscopic aspect of thymic gland after surgical resection en block.

transcervical approach in both pediatric and adult patients. Minimally invasive approach to thymectomy, VATS or robotic, has increasingly taken hold in recent years. Compared with open approaches potential benefits of minimally invasive thymectomy include: less of post-operative pain, decreased length of hospital stay, maintaining a very low postoperative mortality, fewer post-surgical functional problems and better aesthetic results [15]. Furthermore any procedure who needs a sternotomy later in life, after a sternotomy for thymectomy would then mean a redo procedure with possible associated complications. In contradistinction, major disadvantage of minimally invasive approach is the greater challenge in completely removing all thymic tissue, especially compromised by technical details difficulty in the approach of the superior and contralateral portions of the gland [16]. Robotic assisted thoracoscopy has demonstrable advantages, including three-dimensional visualization and articulating instruments. They are particularly useful in the dissection of the superior region and in the contralateral (right) side of the thymus. Disadvantage also are present in this technique, such as excessive costs associated with purchasing and

maintaining a unit as well as the time to dock and set up for robotic arms. Moreover current trends appear to suggest that pediatric robotic surgery is useful and indicated in a select group of procedures and a select group of patients in additional study [17]. Surgical treatment offered to patient an improvement in clinical conditions and robotic's approach was a safe and advantageous surgical way to perform this kind of surgery.

In conclusion, thymectomy should be offered as a part of multimodal therapy when treating children and adolescents with AchR antibody positive JMG with generalized presentation.

There is an urgent need for standardized therapy protocols for JMG that would permit comparison of the data and outcome among different study centers. The possibility of persisting but mild myastenic symptoms of a long duration may need to be considered when counseling patients and families. Actually, the existing quality of data are poor and prone to several sources of bias so prospective, multicenter studies of thymectomy for JMG are warranted.

## Patient consent

Consent to publish the case report was not obtained. This report does not contain any personal information that could lead to the identification of the patient."

## Funding

No funding or grant support.

## Authorship

All authors attest that they meet the current ICMJE criteria for Authorship.

## Declaration of competing interest

The authors declare that they have no known competing financial interests or personal relationships that could have appeared to influence the work reported in this paper.

## References

- [1] VanderPluym J, Vajsar J, et al. Clinical characteristics of pediatric myasthenia: a surveillance study. *Pediatrics* 2013;132:e939–44.
- [2] Liew WKM, Kang PB. "Update on juvenile myasthenia gravis". *Curr Opin Pediatr* 25:694–700.
- [3] Gronseth GS, Barohn RJ. Practice parameter: thymectomy for autoimmune myasthenia gravis (an evidence-based review): report of the quality standards subcommittee of the american academy of neurology. *Neurology* 2000;55(1):7–15.
- [4] Catalano Michael A, Mullan Clancy W, et al. Pediatric thymectomy: a study of national trends in demographics, short-term outcomes, and cost. *Pediatr Surg Int* 2019;35:749–57.
- [5] Keeseey JC. A history of treatments for myasthenia gravis. *Semin Neurol* 2004;24: 5–16.
- [6] Jurado J, Javidfar J, Newmark A, et al. Minimally invasive thymectomy and open thymectomy: outcome analysis of 263 patients. *Ann Thorac Surg* 2012;94(3): 974–81.
- [7] Hartwich J, Tyagi S, Margaron F, et al. Robot-assisted thoracoscopic thymectomy for treating myasthenia gravis in children'. *J Laparoendosc Adv Surg Tech* 2012; 22:925–9.
- [8] Aimee G, Kim1, Sydney A, Upah1, et al. Thoracoscopic thymectomy for juvenile myasthenia gravis'. *Pediatr Surg Int* 2019;35:603–10.
- [9] Masaoka A, Yamakawa Y, Niwa H, Fukai I, Kondo S, Ko- bayashi M, Fujii Y, Monden Y. Extended thymectomy for myasthenia gravis patients: a 20-year review. *Thorac Surg* 1996;62:853–9.
- [10] Jason H, Peragallo. Pediatric myasthenia gravis. *Semin Pediatr Neurol* 2017;24: 116–21.
- [11] Sauce D, Larsen M, Fastenackels S, et al. Evidence of premature immune aging in patients thymectomized during early childhood. *J Clin Invest* 2009;119(10): 3070–8.
- [12] Cao Q, Yin M, Zhou Y, Liu J, Sun K, Li B. Effect of thymectomy on cellular immune function. *Front Biosci* 2011;16:3036–42.
- [13] Sanders Donald B, Wolfe Gil I, Benatar Michael, et al. International consensus guidance for management of myasthenia gravis. *Am Acad Neurol* 2016;87(4): 419–25.
- [14] Adela Della Marina, Kölbl Heike, Müllers Maximilian, et al. Outcome after Robotic-assisted thymectomy in children and adolescents with acetylcholine receptor antibody-positive juvenile myasthenia gravis. *Neuropediatrics* 2017;48 (4):315–22.
- [15] Molinaro F, Garzi A, Cerchia E, et al. Thoracoscopic thymectomy in children: our preliminary experience. *J Laparoendosc Adv Surg Tech* 2013;23(6):556–9.
- [16] Hartwich J, Tyagi S, Margaron F, et al. Robot-assisted thoracoscopic thymectomy for treating myasthenia gravis in children. *J Laparoendosc Adv Surg Tech* 2012;22: 925–9.
- [17] Joseph Hartwich, Tyagi Sanjeev, et al. Robot-Assisted thoracoscopic Thymectomy for treating myasthenia Gravis in children. *J Laparoendosc Adv Surg Tech* 2012;22 (Number 9).