

# A rare cause of acute scrotum in a child: torsion of an epididymal cyst. Case report and review of the literature

Mario Messina, Giulia Fusi, Francesco Ferrara, Edoardo Bindi, Chiara Pellegrino, Francesco Molinaro, Rossella Angotti

Division of Pediatric Surgery, Department of Medical, Surgical and Neurological Sciences, University of Siena, Siena, Italy

## Abstract

Torsion of an epididymal cyst is an extremely rare cause of acute scrotum in children and in young boys. Its reported incidence is 5-20%. The treatment is usually conservative. Many cases (up to 60%) regress spontaneously, especially if below 3 cm. Few cases have been reported in Literature (7 cases/2018). We add our patient as eighth case. He was a 13-year-old boy who was admitted for acute scrotum. Ultrasound excluded torsion of the testis and he was managed for 5 day conservatively. Based on clinical history and physical exam, we decided to perform a prompt surgery that revealed a torsion of epididymal cyst that was confirmed by histological exam.

## Introduction

Epididymal cyst is a benign mass localized most frequently in the head of the epididymis. Its reported incidence is 5-20%.<sup>1</sup> Rarely it is involved in a trauma or torsion requiring a surgical

approach. Torsion of an epididymal cyst is an extremely rare cause of acute scrotum in children and in young boys. Few cases have been reported in Literature (7 cases/2018).<sup>2</sup> We add our patient as eighth case.

## Case Report

A 13-year-old boy has been referred to our hospital with a 5-days history of erythema, swelling, and pain in left hemiscrotum. He has been evaluated to other hospital where the color doppler ultrasonography showed both testes with normal echogenicity and perfusion and an echo-free cystic area of 3.15×1.15 cm with no perfusion in the upper pole of the left testis. Patient has been treated conservatively for 3 days. Due to the persistence of symptoms, child was admitted to our hospital. He did not report a history of scrotal trauma, no fever and no urinary symptoms. Abdominal examination was negative. The inguinal canal was not involved. Physical examination showed the left scrotum red, swollen and tough. Based on clinical history and physical exam, we decided to perform a prompt surgery. The scrotal exploration under general anesthesia was made. After opening of tunica vaginalis, which it was tough and edematous, we found a necrotic mass with a hemorrhagic and taut surface, sited to the superior pole of testicle with an evident twist. Testis and appendix testis were normal. The cyst was untwisted and excised (Figure 1) and we performed testicular fixation. Histological examination showed a congested and hemorrhagic epididymal cyst. The postoperative course was normal. The patient was discharged on third postoperative day with antibiotic therapy for 5 days. The length of hospital stay after this intervention could be shorter but we decided for a longer hospital stay because patient came from other region. The follow-up at 1 month is normal.

We obtained the consent form from the parents.

## Discussion and Conclusions

Acute scrotal pain is a common clinical situation in children. It is always mandatory a surgical consultation to rule out conditions that can damage testis. The main goal in patients with an acute scrotum, indeed, is to rule out torsion of the testis within 6 h from the onset of pain.<sup>3</sup> A surgical exploration is sometime the option of choice despite reassuring ultrasound features, limiting the conservative management only when the torsion of the testis has been completely ruled out. Color doppler ultrasonography has an important role but it is often not completely straight. As it

Correspondence: Rossella Angotti, Division of Pediatric Surgery, Department of Medical, Surgical and Neurological Sciences, University of Siena, Viale Bracci 16, 53100 Siena, Italy.  
Tel.: +39.0577.586502 - Fax: +39.0577.586174.  
E-mail: rossellaangotti@me.com

Key words: Acute scrotum; Child; Epididymal cyst.

Contributions: RA, substantial contributions to the conception or design of the work and its drafting; GF, EB, CP, review of literature; FF, FM, critical revision for important intellectual content; MM, final approval of the version to be published.

Conflict of interest: the authors declare no potential conflict of interest.

Funding: none.

Received for publication: 19 February 2019.  
Revision received: 1 June 2019.  
Accepted for publication: 3 June 2019.

This work is licensed under a Creative Commons Attribution NonCommercial 4.0 License (CC BY-NC 4.0).

©Copyright M. Messina et al., 2019  
Licensee PAGEPress, Italy  
La Pediatria Medica e Chirurgica 2019; 41:210  
doi:10.4081/pmc.2019.210

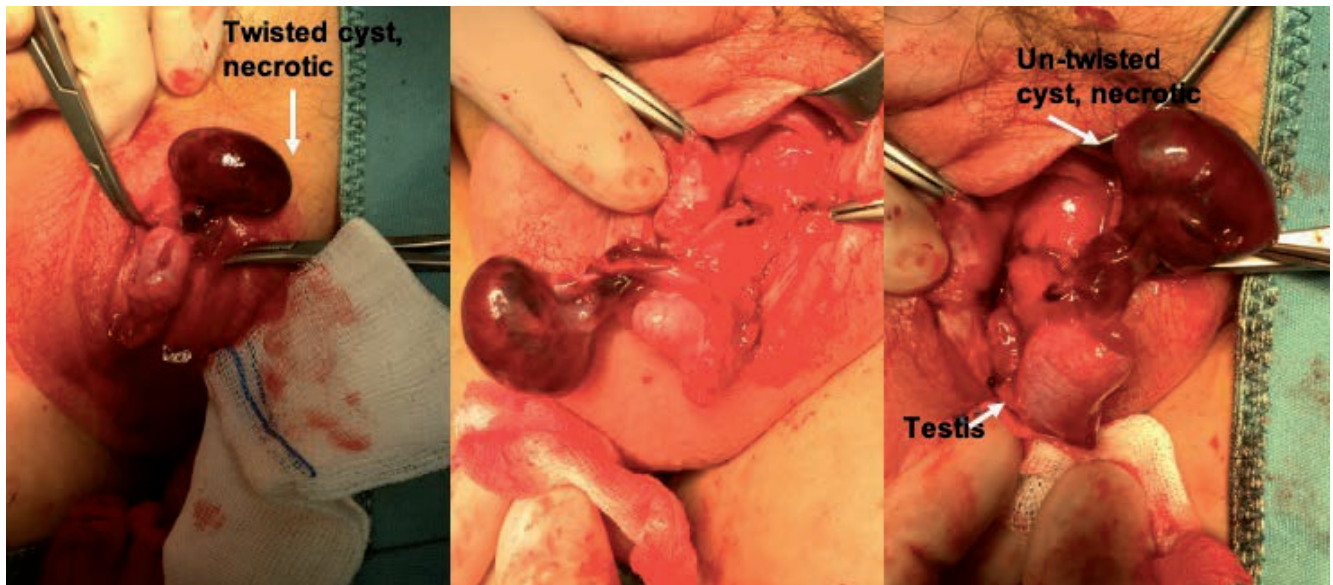


Figure 1. Intraoperative view.

is reported by Schalamon *et al.*,<sup>4</sup> indeed, the doppler ultrasound was able to differentiate between surgical emergencies and other etiologies in 84% of children with acute scrotal pain. In 16% of the cases, instead, the doppler ultrasound was unclear. Moreover, the ultrasound does not allow to make a diagnosis in unusual causes of acute scrotum. Among the unusual causes is reported the torsion of an epididymal cyst. It is an exceedingly rare painful condition that mimics testis torsion. To best of our knowledge, indeed, only seven cases have been reported in Literature.<sup>2</sup> The epididymal cysts are usually painless and asymptomatic; they are often an incidental discovery during testis ultrasound for other reasons. They are known also as *spermatocele*, however they are different lesions, because of *spermatocele* is seen after puberty and contains sperm.<sup>5</sup> Epididymal cyst is usually acquired rather than congenital and it is related to scrotal trauma especially in pediatric age. The treatment is usually conservative. Many cases (up to 60%) regress spontaneously, especially if below 3 cm.<sup>6,7</sup> Surgery is mandatory in case of torsion or in case of unclear ultrasonographic appearance. Although it is a rare event, indeed, it should be considered the differential diagnosis with cystic tumor of epididymis, even if the ultrasound can be help. There is no consensus about the management of epididymal cyst discovered during other surgery of testis. We always remove it if we found it. Due to its rarity, we decided to report our patient who is the eighth case reported in literature. Our boy had no medical complaint for his cyst before surgery and he did not report a scrotal trauma. Ultrasound has been efficient to diagnosis, but the certain diagnosis was made during surgery. In this case we decided to perform an emergency surgery because, when the patient came to our Clinic, we were not sure to exclude the torsion of testis. We did not suppose the torsion of epididymal cyst. In conclusion, torsion of an epididymal cyst should be considered as rare cause of acute

scrotum in children, especially in patient with known cyst or with history of previous trauma. In our opinion the current management of small and no symptomatic epididymal cyst should be conservative, but patient should be educated to recognize signs of acute scrotum. After this case, however, we are questioning about the possibility to plan an elective surgery for epididymal cysts over 10 mm in diameter as suggested by Erikci *et al.*<sup>6</sup> even if it is reported the risk of recurrence after surgical excision.<sup>7</sup> We confirm our surgical management of incidental epididymal cyst during other surgery of testis.

## References

1. Erikci V, Hosgor M, Yildiz M, et al. Torsion of an epididymal cyst: a case report and review of the literature. *Turk J Pediatr* 2013;55:659-61.
2. Bleve C, Conighi ML, Bucci V, et al. Torsion of huge epididymal cyst in a 16-year-old boy: case report and review of the literature. *Pediatr Med Chir* 2018;40:20-2.
3. Takimoto K, Okamoto K, Wakabayashi Y, Okada Y. Torsion of spermatocele: a rare manifestation. *Urol Int* 2002;69:164-5.
4. Schalamon J, Ainoedhofer H, Schlee J, et al. Management of acute scrotum in children-the impact of Doppler ultrasound. *J Pediatr Surg* 2006;41:1377-80.
5. Karaman A, Afşarlar CE, Arda N. Epididymal cyst: not always a benign condition. *Int J Urol* 2013;20:457-8.
6. Erikci V, Hoşgör M, Aksoy N, et al. Management of epididymal cysts in childhood. *J Pediatr Surg* 2013;48:2153-6.
7. Homayoon K, Suhre CD, Steinhardt GF. Epididymal cysts in children: natural history. *J Urol* 2004;171:1274-6.