



Robot-assisted Heller myotomy for achalasia

Giulia Fusi, Francesco Molinaro, Francesco Ferrara, Edoardo Bindi, Chiara Pellegrino, Chiara Calani, Mario Messina, Rossella Angotti*

Division of Pediatric Surgery, Department of Medical, Surgical and Neurological Sciences, University of Siena, Siena, 53100, Italy



ARTICLE INFO

Keywords:

Achalasia
Child
Dysphagia
Myotomy
Robotic surgery

ABSTRACT

Achalasia is a rare neuromuscular esophageal disorder in children. There are many surgical options to treatment including botulinum toxin (Botox) injections, oral pharmacologic therapies with nitrates and calcium channel blockers, pneumatic dilation (PD), and surgical myotomy (open surgery, endoscopy, laparoscopy and recently robotic approach). In pediatric age, usually, Heller's myotomy is the main choice. Laparoscopic approach is known and standardized. Few robotic have been published. We decided to report our first case to share our experience with scientific community.

1. Introduction

The term "Achalasia" (Greek, *khalasis*) defines an inability of the lower esophageal sphincter to relax in the setting of absent peristalsis [1]. The reported incidence is of 0.1–0.18/105 population/year in the pediatric age group, even if very few epidemiological studies have been conducted for achalasia in pediatric patients. Many surgical options have been described in literature. The aim of this communication is to share our preliminary experience with robotic approach introduced six months ago.

2. Case report

A 15-year-old boy was admitted to our institute for 6 months history of dysphagia, primarily to liquids and then to solid, anorexia and unintentional weight loss. This last one was the primary symptom, including a 13 kg weight loss equal to 18% of patients. The diagnosis of achalasia was confirmed via upper gastrointestinal contrast study and gastroscopy (Fig. 1). We didn't perform an esophageal manometry because it is no routinely done in our institution. According to parents and patient we plan Heller's myotomy robot-assisted. Under general anesthesia, the patient was in a supine position. The DaVinci Xi Surgical System was used. The surgical console was in the operating room, the robotic arms were positioned over the head of the patient and the monitor is positioned on the left side of the patient. Five trocars were placed, 3 robotic ports and 2 accessory. Robotic ports were placed: one for camera in the umbilicus, two for robotic arms in the same line left and right lateral. The accessory 12 mm port was placed in right flank for

liver retraction; the accessory 5 mm port was placed on the left of umbilicus in the same line for stomach retraction (Fig. 1). The procedure was Heller's extramucosal myotomy associated with Dor antireflux plastic (Fig. 1). A nasogastric tube was placed in the esophagus to assist in the myotomy. After adequate myotomy, air was introduced to check for mucosal perforation through a nasogastric tube. No intra or post-operative complications. Operative time was 240 min. Patient required oral paracetamol for 72 h and opioid for 24 h for analgesia. The nasogastric tube was removed in 2nd postoperative day and oral feeding was started in 3rd day postop. Hospital length of stay was 7 days. The symptoms had disappeared, except occasional dysphagia to solid food, and patient taken up 2 kg after 3 months. A contrast upper gastrointestinal study 1 month later, due to chest pain and dyspnea of patient, revealed a normal profile of esophagus. The last follow-up, 6 months after surgery, was normal.

3. Discussion

Is there a gold standard treatment for achalasia in children?

No. Due to his extremely rarity in children and to the multiple modalities of treatment existing, there is no agreement about the gold standard of treatment for achalasia in children. Moreover, for the reasons of above, randomized controlled studies in this kind of population are actually missing. The symptomatic easement is the main goal of treatment of achalasia. There are multiple treatment modalities beside surgical myotomy, including oral medications, botulinum toxin injection to the lower esophageal sphincter, pneumatic or mechanical esophageal dilatation and endoscopic myotomy. In our center, we plan

* Corresponding author. viale Bracci 16, 53100, Siena, Italy. Tel.: +390577586502; fax: +390577586174.
E-mail address: rossellaangotti@me.com (R. Angotti).

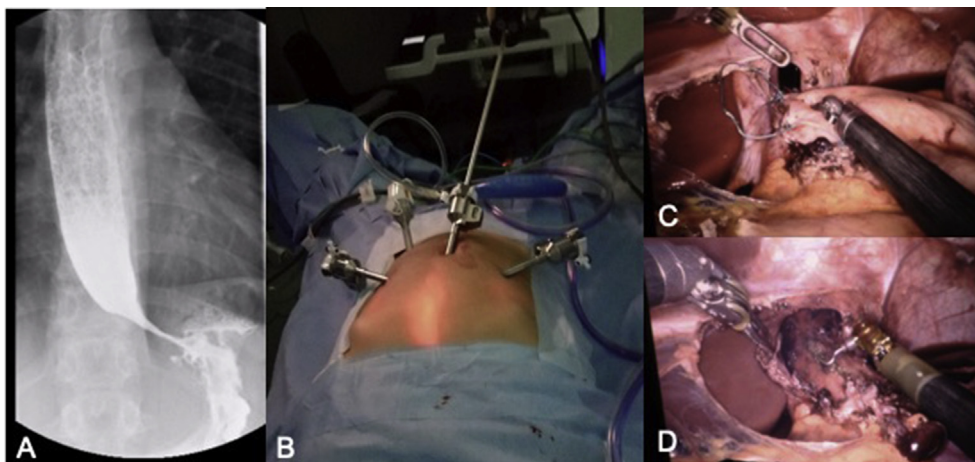


Fig. 1. A: preoperative contrast upper gastrointestinal study. B: ports set up. C: Dor antireflux plastic procedure. D: Heller's extramucosal myotomy.

directly surgery [1]. We do not perform any endoscopic dilatation or botox injection, probably because the needing of a skilled pediatric endoscopic team, at the moment is missing.

Is there a gold standard surgical technique?

No. The Heller extramucosal myotomy is the main surgical treatment of choice for achalasia. The addition of an anti-reflux plastic in order to reduce the risk of gastroesophageal reflux after surgery is still controversial and once again a consensus in literature is missing. We systematically perform Heller's procedure associated with Thal/Dor antireflux plastic.

Is there a gold standard approach to perform Heller's procedure?

No. Despite the lack of a unique agreement, the laparoscopic Heller's myotomy is described as effective procedure, with low rate of complications and a high rate of success; for these reasons over the last 15 years has been used as first line treatment for achalasia in adults and in children. However, in literature, some series shows the feasibility of using computer-assisted robot-enhanced surgery to perform fundoplication and Heller's myotomy in children. In our Center, we have performed laparoscopic approach up to 2016 despite our good learning curve in thoracoscopy [2]. In the last year, the advent of the robotic, the increased of learning curve of our staff [3] and the features of this specific patient pushed us to shift our approach to robotic assisted surgery that revealed a safe and efficient option. We decided to report our preliminary experience because of only 20 pediatric cases have been published in literature to date [4–10].

Are there any differences between laparoscopic and robotic patients?

The main bias of this point is the difference of samples, that are no comparable. We know, indeed, that a valid statistical comparison is impossible. However, we retrospectively analyzed our series. We did not record any difference in terms of occurrence of complications or recurrences comparing with the laparoscopic cases. Also, the intraoperative comparison doesn't show any difference in terms of operating times between laparoscopic and robotic procedures. The major advantage is represented by the ease and confidence felt by surgeons related to the magnified three-dimensional vision and the extra degree of freedom at the wrist of instrument which, added to the tremor filtration provided by the computer interface, can reduce the risk of mucosal perforation (that remains the most serious complication of this kind of procedures). Another advantage/benefit is the improvement of postoperative course, in terms of postoperative pain, that was managed using only paracetamol, without the needing of addition of any second level drugs after the first 24 h, and in terms of length of stay in hospital (only 7 days). Some Authors suggest that the main limit of this technique remains the cost effectiveness.⁷ With regarding at this, we can conclude that in a center in which exist a robotic platform, shared by different specialist surgeons, there aren't additional costs and the cost-

benefit ratio is not so high. In our opinion, the robotic approach for Heller myotomy is safety and feasible, also in term of cost-benefit ratio.

Funding

This research did not receive any specific grant from funding agencies in the public, commercial, or not-for-profit sectors.

Conflict of interest

No conflicts of interest.

Ethical approval

No ethical approval is requested.

Consent

Consent form is included as separated file.

Appendix A. Supplementary data

Supplementary data to this article can be found online at <https://doi.org/10.1016/j.epsc.2019.101204>.

References

- [1] Garzi A, Valla JS, Molinaro F, Amato G, Messina M. Minimally invasive surgery for achalasia: combined experience of two European centers. *J Pediatr Gastroenterol Nutr* 2007;44(5):587–91.
- [2] Molinaro F, Garzi A, Cerchia E, Angotti R, Di Maggio G, Valla JS, Messina M. Thoracoscopic thymectomy in children: our preliminary experience. *J Laparoendosc Adv Surg Tech A* 2013;23:556–9.
- [3] Mattioli G, Molinaro F, Paraboschi I, Leonelli L, Mazzola C, Arrigo S, Mancardi M, Pini Prato A, Angotti R, Messina M, Bianchi A. Robotic assisted minimally invasive total esophagogastric dissociation for children with severe neurodisability. *J Laparoendosc Adv Surg Tech A* 2017;27:550–5.
- [4] Altokhais T, Mandora H, Al-Qahtani A, Al-Bassam A. Robot-assisted Heller's myotomy for achalasia in children. *Comput Assist Surg* 2016;21(1):127–31.
- [5] Chaer RA, Jacobsen G, Elli F, Harris J, Goldstein A, Horgan S. Robotic-assisted laparoscopic pediatric Heller's cardiomyotomy: initial case report. *J Laparoendosc Adv Surg Tech A* 2004;14:270–3.
- [6] Klein MD, Langenburg SE, Kaber M, Lorincz A, Knight CG. Pediatric robotic surgery: lessons from a clinical experience. *J Laparoendosc Adv Surg Tech A* 2007;17:265–71.
- [7] Najmaldin A, Antao B. Early experience of tele-robotic surgery in children. *Int J Med Robot* 2007;3:199–202.
- [8] Meehan JJ, Sandler A. Pediatric robotic surgery: a single-institutional review of the first 100 consecutive cases. *Surg Endosc* 2008;22:177–82.
- [9] Camps JI. The use of robotics in pediatric surgery: my initial experience. *Pediatr Surg Int* 2011;27:991–6.
- [10] Ballouhey Q, Dib N, Binet A, Carcauzon-Couvrat V, Clermidi P, Longis B, et al. How robotic-assisted surgery can decrease the risk of mucosal tear during Heller myotomy procedure? *J Robot Surg* 2016;11:255–8.