

Restenosis after Coronary and Peripheral Intervention: Efficacy and Clinical Impact of Cilostazol

Gianmarco de Donato,¹ Francesco Setacci,² Mariagnese Mele,¹ Giovanni Giannace,¹ Giuseppe Galzerano,¹ and Carlo Setacci,¹ Siena, Italy

Restenosis is one of the main complications in patients undergoing coronary or peripheral revascularization procedures and is the leading cause for their long-term failures. Cilostazol is the only pharmacotherapy that showed an adequate efficacy for preventing restenosis in randomized, controlled studies after coronary or peripheral revascularization procedures. The present review sums up the main clinical evidence supporting the use of cilostazol after revascularization interventions, focusing on all its benefits, warnings, and administration schedules.

INTRODUCTION

Restenosis is one of the main complications in patients undergoing coronary or peripheral revascularization procedures. It can be considered as a reocclusion process of the vascular-treated lumen due to an excessive proliferation of the target vessel wall. Restenosis is the leading cause for the long-term failure of revascularization procedures.¹ Clinical impact of restenosis is well reported in literature, showing a strong correlation with poor clinical outcomes after both cardiac and peripheral interventions.^{1,2}

Pathogenic mechanisms underlying restenosis development are still not entirely known, but they show similar features both at coronary and peripheral levels. In patients undergoing a revascularization intervention, mechanical lesions of the target artery wall will induce an endothelial irritation, leading to a complex series of inflammatory responses

characterized by thrombotic events, platelet activation, fibrin deposition, leukocyte migration, together with extracellular matrix build-up and smooth muscle cell hyperproliferation.³

Variable rates of restenosis after a revascularization procedure are observed based on patients and procedure characteristics. An incidence of about 15–25% after a coronary stent implantation³ and from 5% to 70% after a peripheral revascularization⁴ can be esteemed.

Until now, there are no authorized drugs for preventing a restenosis after cardiac and peripheral revascularization procedures; in fact, the only useful strategy is now represented by medical devices: drug-eluting stents releasing antiproliferative drugs.⁵ Oral antiplatelet aggregation drugs (e.g., aspirin, clopidogrel, prasugrel, ticlopidine, and ticagrelor) should be administered after a cardiac revascularization procedure for preventing the occurrence of a stent or by-pass reocclusion essentially due to thrombotic events, but they have no relevant effects on reocclusion phenomena caused by target vessel restenosis (hyperproliferative events). In addition, statins have been proposed as antirestenosis agents; however, adequate clinical findings are absent and their impact on stent restenosis is still under debate.

Cilostazol is the only pharmacotherapy that showed an adequate efficacy for preventing restenosis in randomized and controlled studies after coronary and peripheral revascularization procedures.

¹Department of Medicine, Surgery and Neuroscience, University of Siena, Siena, Italy.

²Clinica Casa di Cura Giovanni XXIII, Monastier di Treviso, Italy.

Correspondence to: Gianmarco de Donato, Department of Medicine, Surgery and Neuroscience, University of Siena, Policlinico Le Scotte, Viale Bracci 1, 53100 Siena, Italy; E-mail: dedonato@unisi.it

Ann Vasc Surg 2017; 41: 300–307

<http://dx.doi.org/10.1016/j.avsg.2016.08.050>

© 2017 The Authors. Published by Elsevier Inc. This is an open access article under the CC BY-NC-ND license (<http://creativecommons.org/licenses/by-nc-nd/4.0/>).

Manuscript received: July 12, 2016; manuscript accepted: August 26, 2016; published online: 24 February 2017

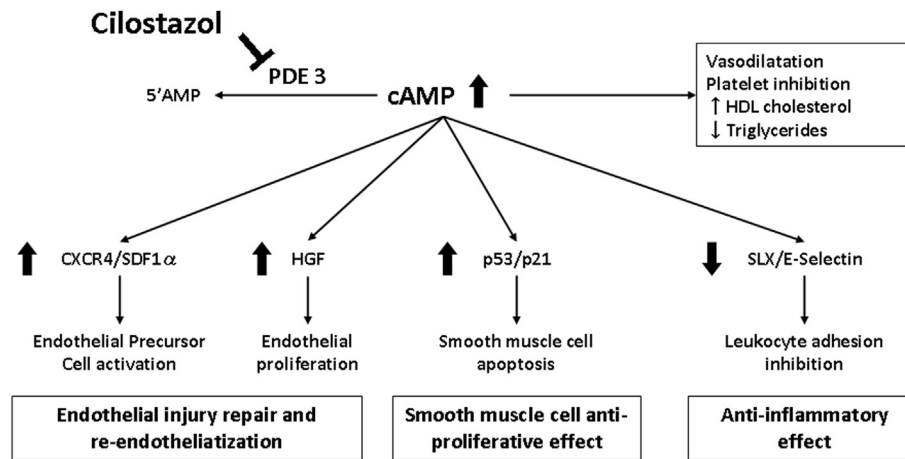


Fig. 1. Mechanism of action and pharmacological effects of cilostazol. AMP, adenosine monophosphate; PDE, phosphodiesterase; cAMP, cyclic adenosine monophosphate; CXCR4, C-X-C chemokine receptor

type 4; HDL, high-density lipoprotein; HGF, hepatocyte growth factor; SDF1 α , stromal cell-derived factor 1 α ; SLX, Sialil-Lewis^X.

The aim of the present review was to sum up the main clinical evidence supporting the use of cilostazol after revascularization interventions, focusing on all its benefits, warnings, and administration schedules, to provide clinicians with practical information for a proper use of the drug.

CILOSTAZOL

Cilostazol was launched in Italy in 2008, and it is indicated for the improvement of the maximal and pain-free walking distances in patients with intermittent claudication (peripheral arterial disease—Fontaine stage II).

Cilostazol is a selective phosphodiesterase III inhibitor with known antiplatelet, vasodilative, and antiproliferative effects on vessel smooth muscle cells and positive effects on high-density lipoprotein cholesterol and triglyceride levels. In addition, several studies evaluated its pharmacological effects for the prevention of restenosis, suggesting favorable effects on reendothelialization mediated by hepatocyte growth factor⁶ and endothelial precursor cells,⁷ as well as on the inhibition of smooth muscle cell proliferation⁸ and the inhibition of leukocyte adhesion to endothelium therefore exerting an anti-inflammatory effect⁹ (Fig. 1). These effects may, at least in part, explain the clinical efficacy of cilostazol in preventing restenosis and in promoting the long-term outcome of revascularization interventions. In fact, the antiproliferative effects on smooth muscle cells, the anti-inflammatory effects, and the endothelium

protection can counter the complex events underlying restenosis and prevent reocclusion of the vessel. On the other hand, antiplatelet agents are well known to reduce fatal or nonfatal cardiovascular disease events in patients with coronary or peripheral artery disease.

Starting from the late 1990s, cilostazol has also been studied in a large number of randomized, controlled clinical trials—mainly carried out in Asian countries or USA—for the prevention of restenosis after coronary, carotid, and lower limb revascularization.

CLINICAL EFFICACY

Table I shows the results of the main meta-analysis on the use of cilostazol after percutaneous coronary or peripheral revascularization.

Coronary Revascularization

Studies that proved the efficacy of cilostazol for preventing a restenosis and improving the clinical outcome after percutaneous revascularization enrolled the following patients: patients with stable or unstable angina or silent myocardial ischemia,¹⁵ patients with acute coronary syndrome,¹⁶ diabetic patients with angina pectoris,¹⁷ patients with long lesions,¹⁸ and patients who underwent elective balloon percutaneous transluminal coronary angioplasty.¹⁹

A meta-analysis including more than 5,000 patients randomized to receive cilostazol plus single

Table I. Main metaanalysis results

Study	Studies; patients	Cilostazol group	Control group	Intervention	Follow-up	Restenosis	TLR	MACE	In-stent thrombosis	Bleeding
Coronary revascularization										
Biondi-Zoccai et al., 2008 ¹⁹	23 RCT; 5,428	Cilostazol + standard medical therapy	Standard medical therapy	BMS, DES, PTCA, DCA	6 months (1–36)	–40%; $P \leq 0.0001$	–31%; $P \leq 0.0001$	–25%; $P \leq 0.05$	+35%; NS	–29%; NS
Bangalore et al., 2014 ¹⁰	34 RCT; 14,110	Cilostazol + DAPT	DAPT	BMS, DES	9 months (1–25)	—	–43%; $P \leq 0.05$	–32%; $P \leq 0.05$	–37%; $P \leq 0.05$	+26%; NS
Carotid revascularization										
Galyfos et al., 2015 ²⁰	1 RCT; 6 CT; 1,297	Cilostazol + standard medical therapy	Standard medical therapy	Stent	20 months (1–36)	–85%; $P \leq 0.0001$	—	–24%; NS	—	—
Lower limb revascularization										
Benjo et al., 2014 ²⁹	3 RCT; 396	Cilostazol + standard medical therapy	Standard medical therapy	Intravascular	20 months (12–24)	–20%; $P \leq 0.0001$	–17%; $P \leq 0.0001$	—	—	—
Warner et al., 2014 ¹³	2 RCT; 4 CT; 1,522	Cilostazol + standard medical therapy	Standard medical therapy	Intravascular	27 months (18–37)	–29%; $P \leq 0.0001$	Free from +36%; $P \leq 0.0001$	—	—	—

BMS, bare-metal stent; CT, controlled trial; DAPT, dual antiplatelet therapy; DCA, directional coronary atherectomy; DES, drug-eluting stent; MACE, major adverse cardiac events; NS, not statistically significant; PTCA, percutaneous transluminal coronary angioplasty; RCT, randomized controlled trial; TLR, target lesion revascularization.

or dual antiplatelet treatment versus single or dual antiplatelet treatment alone, with a follow-up from 1 to 36 months, has shown the efficacy of cilostazol for preventing angiographic restenosis and improving the clinical outcome after a stent implantation with or without eluting drugs. These results suggest a significant reduction of restenosis incidence (–40%; $P \leq 0.001$) and a decreased need for repeat revascularization (–31%; $P \leq 0.001$).¹⁰

Another meta-analysis was carried out to evaluate the clinical effects of a cilostazol treatment in more than 14,000 patients randomized to receive cilostazol plus a dual antiplatelet treatment versus dual antiplatelet treatment alone, after a stent implantation with or without eluting drugs, with a follow-up from 1 to 25 months. Results show that the cilostazol treatment has efficiently and significantly reduced the incidence of major cardiovascular events (–32%; $P < 0.05$), the need for repeat revascularization (–43%; $P < 0.05$), and the onset of stent thrombosis (–37%; $P < 0.05$).¹¹ Both studies have confirmed a satisfactory drug safety profile.

A recent randomized study has also evaluated the effect of a cilostazol treatment started 6 months after a coronary stent implantation, following the withdrawal of one of the dual standard antiplatelet treatments, versus patients continuously treated with a single antiplatelet treatment after the drug withdrawal. Results show that the cilostazol treatment has efficiently and significantly reduced the incidence of the study primary end points (death combined score for any cause, myocardial infarction, stroke, and revascularization intervention) up to 2-year follow-up (–39%, $P = 0.021$)²⁰ (Fig. 2). Of note, the rate of major or minor bleeding was not significantly different between the aspirin plus cilostazol and aspirin-only groups.

Carotid Revascularization

A recent meta-analysis with a systemic review of clinical studies—that evaluated the effects of a cilostazol treatment after a carotid stent implantation for the treatment of asymptomatic or symptomatic stenosis—included 7 controlled trials (only 1 randomized trial) for a total of 1,297 patients.¹² Meta-analysis results showed a significantly lower in-stent restenosis rate in the patients treated with cilostazol after a mean 20-month follow-up: risk –85%, $P < 0.001$. Instead, the pooled incidence of infarction, stroke, and death at 1- and 20-month follow-up suggests a statistically not significant risk reduction of 28% and 24% for the cilostazol group, respectively. This meta-analysis did not show any safety-related drug

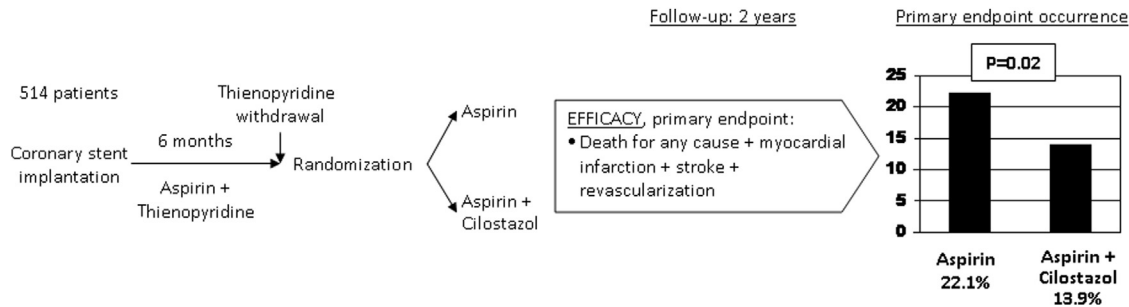


Fig. 2. Design and study results from the study by Ueda et al.²⁰ Interestingly in this study, cilostazol was started 6 months after revascularization (after discontinuation

of thienopyridine), and it was found still effective in improving the primary end point.

problems, especially for the bleeding incidence. Notably, most trials were made of observational type studies in this setting; therefore, the acquisition of more robust evidence from randomized trials would be desirable in future.

Peripheral Revascularization

All studies that showed the efficacy of cilostazol for preventing restenosis and improving the clinical outcome after lower limb revascularization included patients with a peripheral arteriopathy (claudicatio intermittens of critical lower limb ischemia)^{21–26}; 3 studies have focused specifically on hemodialysis patients, including a total of 840 subjects.^{27–29}

A meta-analysis including 396 patients randomized to receive cilostazol plus antiplatelet treatment versus antiplatelet treatment alone, after a lower limb revascularization, with a follow-up from 12 to 24 months, has shown that cilostazol has efficiently and significantly reduced the restenosis incidence (–20%; $P < 0.0001$) and the need for repeat revascularization (–17%; $P < 0.0001$).¹³

Another meta-analysis including more than 1,500 patients—enrolled in 2 randomized studies and 4 prospective observational studies—treated with cilostazol plus antiplatelet treatment versus standard antiplatelet treatment alone, after a lower limb revascularization and with a follow-up from 18 to 37 months, has shown that cilostazol has efficiently and significantly reduced restenosis incidence (–29%; $P < 0.001$), decreased limb amputation (–58%; $P < 0.001$), and increased survival without any new revascularization procedures (+36%; $P < 0.001$).¹⁴ Both studies have confirmed a satisfactory drug safety profile.

In addition, a recent retrospective study carried out in the United States including as much as 22,954 patients (of which 1,999 treated with cilostazol), who underwent an open or endovascular

lower limb revascularization for intermittent claudication or critical limb ischemia, has confirmed a significant reduction of the amputation rate up to 1-year follow-up in patients treated with cilostazol versus controlled group (14.8% vs. 24.0%; $P < 0.0001$). This effect proved significant both for open and endovascular revascularization, and it was substantially more evident in patients treated with cilostazol before the intervention.³⁰

Data from the Most Recent Randomized Clinical Trials

Table II summarizes methods and results of randomized clinical trials published in 2015 and 2016.^{20,31–35}

DRUG TOLERABILITY AND CONTRAINDICATIONS

Generally, cilostazol is a well-tolerated drug; the most commonly reported adverse events are headache and gastrointestinal disorders, both transitory and mild-moderate events. Although not validated by any adequate clinical studies, a starting scaled titration dose may improve the drug tolerability. Cilostazol should not be administered in case of severe renal impairment or moderate-severe hepatic impairment; pregnancy; bleeding risk (e.g., active peptic ulceration, recent hemorrhagic stroke, proliferative diabetic retinopathy, and poorly controlled hypertension); decompensated congestive heart failure; patients treated concomitantly with two or more additional antiplatelet or anticoagulant agents; severe arrhythmias; unstable angina pectoris, myocardial infarction within the last 6 months, or any coronary intervention in the last 6 months.

In particular, the last 3 contraindications were introduced in 2013 by the European Medicines Agency (EMA) following a referral procedure

Table II. Data from the most recent randomized clinical trials

Study	Design	Patients (Centers)	Setting	Follow-up, months	Treatment groups (Duration)	Primary outcome	Primary outcome occurrence (group 1 vs. 2)
Ueda et al. ²⁰	O	514 (1)	Stable CAD or ACS patients who received DES or BMS implantation >6 months before (after dual antiplatelet therapy suspension)	24	(1) 245 patients. CIL (100 mg bid) + A (81–100 mg/d) (2) 260 patients. A (81–100 mg/d; for 24 months)	All-cause death, myocardial infarction, stroke, or coronary or cerebrovascular revascularization	13.9% vs. 22.1%, <i>P</i> = 0.021
Ari et al. ³¹	O	172 (1)	Stable angina pectoris patients scheduled for PCI	1	(1) 86 patients. CIL (200 mg) + CLO (600 mg) + R (40 mg) (2) 86 patients. CLO (600 mg) + R (40 mg; pretreatment)	PPMIJ or PPMIN	PPMIJ: 21% vs. 24%, <i>P</i> = 0.58; PPMIN: 2.3% vs. 7%, <i>P</i> = 0.27
Wang et al. ³²	O	153 (1)	Non-STEMI patients who underwent PCI	1	(1) 74 patients. A (100 mg/day) + CLO (75 mg/day) + CIL (100 mg bid) (2) 79 patients. A (100 mg/day) + CLO (75 mg/day; 30 days)	NA	—
Lee et al. ³³	B	254 (6)	NSTEMI-ACS patients undergoing percutaneous coronary intervention	1	(1) 127 patients. A (100 mg/day) + CLO (75 mg/day) + CIL (100 mg bid) (2) 127 patients. A (100 mg/day) + CLO (75 mg/day) (1 month)	MACE* up to 30 days	27.1% vs. 28.8%, <i>P</i> = 0.777
Xu et al. ³⁴	O	113 (1)	ACS patients undergoing PCI	<1	(1) 56 patients. A (100 mg/day) + CLO (75 mg/day) + CIL (100 mg bid) (2) 57 patients. A (100 mg/day) + CLO (75 mg/day; 7 days)	Periprocedural myocardial infarction up to 24 hr after PCI	32.1% vs. 47.4%, <i>P</i> = 0.098

(Continued)

Table II. Continued

Study	Design	Patients (Centers)	Setting	Follow-up, months	Treatment groups (Duration)	Primary outcome	Primary outcome occurrence (group 1 vs. 2)
Zheng et al. ³⁵	O	127 (1)	Patients with complex lesions undergoing PCI	12	(1) 61 patients. A (100 mg/day) + CLO (75 mg/day) + CIL (50 mg bid) (2) 66 pts. A (100 mg/day) + CLO (75 mg/day; 12 months)	MACE** up to 1 year	1.6% vs. 16.7%, <i>P</i> = 0.004

A, aspirin; ACS, acute coronary syndrome; B, blinded end point; BMS, bare-metal stent; CAD, coronary artery disease; CIL, cilostazol; CLO, clopidogrel; DES, drug-eluting stent; MACE, major adverse cardiovascular events (defined as composite of * cardiovascular death, myocardial infarction [myocardial infarction; spontaneous, or periprocedural], and ischemia driven target vessel revascularization, or ** cardiac death, myocardial infarction, and target lesion revascularization); NSTE: non-ST-segment elevation; O, open; PCI, percutaneous coronary intervention; PPMIJ, periprocedural myocardial injury; PPMIN, periprocedural myocardial infarction; R, rosuvastatin; STEMI, ST-segment elevation myocardial infarction.

Table III. Coadministration of cilostazol with inhibitors of CYP3A4 and CYP2C19

Drug	Inhibited cytochrome	Area under the curve in case of co-administration			Change in the cilostazol dose
		Cilostazol	Dehydrocilostazol	4'-trans-hydroxycilostazol	
Erythromycin and similar agents (e.g., clarithromycin)	3A4	+72%	+6%	+119%	50 mg BID
Ketoconazole and similar agents (e.g., itraconazole)	3A4	+117%	-15%	+87%	
Omeprazole	2C19	+22%	+68%	-36%	
Diltiazem	3A4	+44%	+4%	+43%	None
Grapefruit juice (240 mL)	3A4	—	—	—	

Cilostazol has 2 major metabolites: dehydro cilostazol and a 4'-trans-hydroxy cilostazol, which present antiplatelet activity 4–7 times higher and about one-fifth compared with cilostazol, respectively.

initiated by the Spanish authority, whose main concerns focused on reports received of cardiovascular reactions and hemorrhagic reactions and drug interactions during the first 18 months of marketing in Spain. Thus, after a complete review of the clinical and safety profile of cilostazol, EMA introduced these new measures to minimize the potential occurrence of new adverse events. Although clinical trial data do not substantiate safety concerns raised from spontaneous adverse drug reactions reporting, the Committee for Medicinal Products for Human Use concluded that the risk of bleeding and some cardiovascular events cannot be excluded in at-risk patients (e.g., elderly patients with

underlying co-morbidities receiving a high number of concomitant medications known to interact with cilostazol).

Prescribers also need to be aware of the risk of interactions with cilostazol: its dose should be reduced in patients concurrently taking strong inhibitors of CYP3A4 (e.g., ketoconazole, itraconazole, and erythromycin) or CYP2C19 enzymes (e.g., omeprazole; [Table III](#)).

THERAPEUTIC SCHEME

Cilostazol should be administered at a dose of 100 mg twice a day (the dose should be reduced to

50 mg twice a day in patients receiving medicines that strongly inhibit cytochromes).³⁶

In clinical trials, after a percutaneous coronary revascularization, the treatment was generally started the day after the intervention for a period of 12–24 months. Interestingly, the scheme of a recent study by Ueda et al.²⁰ provided a cilostazol treatment starting from 6 months after revascularization in patients who had withdrawn from one of the standard dual antiplatelet treatments administered (Fig. 2). This scheme provides more drug safety (no infringement of contraindications) and also significant long-term clinical outcomes.

In clinical trials, after a peripheral revascularization, the treatment was generally started the day after the intervention for a period up to 3 years. In high bleeding risk patients, it could be useful starting the treatment after the withdrawal of one drug of the standard dual antiplatelet treatment administered (at least 1 month of dual antiplatelet treatment after an intravascular intervention according to the guidelines).³⁷

CONCLUSIONS

Cilostazol efficiently prevents restenosis by promoting reendothelialization and by inhibiting smooth muscle cell proliferation and leukocyte adhesion to endothelium. Until now, cilostazol is the only pharmacotherapy that showed an adequate efficacy for preventing restenosis in randomized, controlled studies after coronary, carotid, or lower limb revascularization. These studies also show a significant reduction of repeat revascularization and cardiovascular events, with no increase of bleeding risk. Cilostazol should be administered at a dose of 100 mg twice a day, in a long-term regimen. To optimize the drug benefit/risk profile, it might be useful starting the treatment after the withdrawal of one of the standard postoperative dual antiplatelet treatment and waiting for 6 months after the coronary revascularization procedure.

REFERENCES

1. Setacci C, Castelli P, Chiesa R, et al. Restenosis: a challenge for vascular surgeon. *J Cardiovasc Surg (Torino)* 2012;53:735–46.
2. Byrne RA, Joner M, Kastrati A. Stent thrombosis and restenosis: what have we learned and where are we going? The Andreas Gruntzig Lecture ESC 2014. *Eur Heart J* 2015;36:3320–31.
3. Guerra E, Byrne RA, Kastrati A. Pharmacological inhibition of coronary restenosis: systemic and local approaches. *Expert Opin Pharmacother* 2014;15:2155–71.

4. Malyar NM, Reinecke H, Freisinger E. Restenosis after endovascular revascularization in peripheral artery disease. *Vasa* 2015;44:257–70.
5. Dake MD, Ansel GM, Jaff MR, et al. Durable clinical effectiveness with paclitaxel-eluting stents in the femoropopliteal artery: 5-year results of the Zilver PTX Randomized Trial. *Circulation* 2016;133:1472–83.
6. Aoki M, Morishita R, Hayashi S, et al. Inhibition of neointimal formation after balloon injury by cilostazol, accompanied by improvement of endothelial dysfunction and induction of hepatocyte growth factor in rat diabetes model. *Diabetologia* 2001;44:1034–42.
7. Kawabe-Yako R, Ii M, Masuo O, et al. Cilostazol activates function of bone marrow-derived endothelial progenitor cell for re-endothelialization in a carotid balloon injury model. *PLoS One* 2011;6:e24646.
8. Morishita R. A scientific rationale for the CREST trial results: evidence for the mechanism of action of cilostazol in restenosis. *Atheroscler Suppl* 2005;6:41–6.
9. Takigawa T, Tsurushima H, Suzuki K, et al. Cilostazol suppression of arterial intimal hyperplasia is associated with decreased expression of sialyl Lewis X homing receptors on mononuclear cells and E-selectin in endothelial cells. *J Vasc Surg* 2012;55:506–16.
10. Biondi-Zoccai GG, Lotrionte M, Anselmino M, et al. Systematic review and meta-analysis of randomized clinical trials appraising the impact of cilostazol after percutaneous coronary intervention. *Am Heart J* 2008;155:1081–9.
11. Bangalore S, Singh A, Toklu B, et al. Efficacy of cilostazol on platelet reactivity and cardiovascular outcomes in patients undergoing percutaneous coronary intervention: insights from a meta-analysis of randomised trials. *Open Heart* 2014;1:e000068.
12. Galyfos G, Geropapas G, Sigala F, et al. Meta-analysis of studies evaluating the effect of cilostazol on major outcomes after carotid stenting. *J Endovasc Ther* 2016;23:186–95.
13. Benjo AM, Garcia DC, Jenkins JS, et al. Cilostazol increases patency and reduces adverse outcomes in percutaneous femoropopliteal revascularisation: a meta-analysis of randomised controlled trials. *Open Heart* 2014;1:e000154.
14. Warner CJ, Greaves SW, Larson RJ, et al. Cilostazol is associated with improved outcomes after peripheral endovascular interventions. *J Vasc Surg* 2014;59:1607–14.
15. Douglas JS Jr, Holmes DR Jr, Kereiakes DJ, et al. Coronary stent restenosis in patients treated with cilostazol. *Circulation* 2005;112:2826–32.
16. Han Y, Li Y, Wang S, et al. Cilostazol in addition to aspirin and clopidogrel improves long-term outcomes after percutaneous coronary intervention in patients with acute coronary syndromes: a randomized, controlled study. *Am Heart J* 2009;157:733–9.
17. Lee SW, Park SW, Kim YH, et al. Drug-eluting stenting followed by cilostazol treatment reduces late restenosis in patients with diabetes mellitus the DECLARE-DIABETES Trial (A Randomized Comparison of Triple Antiplatelet Therapy with Dual Antiplatelet Therapy After Drug-Eluting Stent Implantation in Diabetic Patients). *J Am Coll Cardiol* 2008;51:1181–7.
18. Lee SW, Park SW, Kim YH, et al. A randomized, double-blind, multicenter comparison study of triple antiplatelet therapy with dual antiplatelet therapy to reduce restenosis after drug-eluting stent implantation in long coronary lesions: results from the DECLARE-LONG II (Drug-Eluting Stenting Followed by Cilostazol Treatment Reduces Late

- Restenosis in Patients with Long Coronary Lesions) trial. *J Am Coll Cardiol* 2011;57:1264–70.
19. Tsuchikane E, Fukuhara A, Kobayashi T, et al. Impact of cilostazol on restenosis after percutaneous coronary balloon angioplasty. *Circulation* 1999;100:21–6.
 20. Ueda H, Kido A, Matsuhisa S, et al. Addition of cilostazol to aspirin therapy for secondary prevention of cardiovascular and cerebrovascular disease in patients undergoing percutaneous coronary intervention: a randomized, open-label trial. *Am Heart J* 2016;173:134–42.
 21. Iida O, Nanto S, Uematsu M, et al. Cilostazol reduces restenosis after endovascular therapy in patients with femoropopliteal lesions. *J Vasc Surg* 2008;48:144–9.
 22. Ikushima I, Yonenaga K, Iwakiri H, et al. A better effect of cilostazol for reducing in-stent restenosis after femoropopliteal artery stent placement in comparison with ticlopidine. *Med Devices (Auckl)* 2011;4:83–9.
 23. Soga Y, Iida O, Hirano K, et al. Impact of cilostazol after endovascular treatment for infrainguinal disease in patients with critical limb ischemia. *J Vasc Surg* 2011;54:1659–67.
 24. Soga Y, Iida O, Hirano K, et al. Restenosis after stent implantation for superficial femoral artery disease in patients treated with cilostazol. *Catheter Cardiovasc Interv* 2012;79:541–8.
 25. Soga Y, Yokoi H, Kawasaki T, et al. Efficacy of cilostazol after endovascular therapy for femoropopliteal artery disease in patients with intermittent claudication. *J Am Coll Cardiol* 2009;53:48–53.
 26. Iida O, Yokoi H, Soga Y, et al. Cilostazol reduces angiographic restenosis after endovascular therapy for femoropopliteal lesions in the Sufficient Treatment of Peripheral Intervention by Cilostazol study. *Circulation* 2013;127:2307–15.
 27. Ishii H, Kumada Y, Toriyama T, et al. Effects of oral cilostazol 100 mg twice a day on long-term patency after percutaneous transluminal angioplasty in patients with femoropopliteal disease undergoing hemodialysis: a retrospective chart review in Japanese patients. *Clin Ther* 2010;32:24–33.
 28. Ishii H, Kumada Y, Toriyama T, et al. Cilostazol improves long-term patency after percutaneous transluminal angioplasty in hemodialysis patients with peripheral artery disease. *Clin J Am Soc Nephrol* 2008;3:1034–40.
 29. Ishii H, Aoyama T, Takahashi H. Treatment with cilostazol improves clinical outcome after endovascular therapy in hemodialysis patients with peripheral artery disease. *J Cardiol* 2016;67:199–204.
 30. Neel JD, Kruse RL, Dombrovskiy VY, et al. Cilostazol and freedom from amputation after lower extremity revascularization. *J Vasc Surg* 2015;61:960–4.
 31. Ari H, Emlak N, Ari S, et al. The effect of high dose cilostazol and rosuvastatin on periprocedural myocardial injury in patients with elective percutaneous coronary intervention. *Acta Cardiol Sin* 2015;31:292–300.
 32. Wang M, Zhang G, Wang Y, et al. Bivalirudin plus loading dose of cilostazol-based triple-antiplatelet in treatment of non-ST-elevation myocardial infarction following percutaneous coronary intervention. *Ther Clin Risk Manag* 2015;11:1469–73.
 33. Lee K, Yoo SY, Suh J, et al. Efficacy of cilostazol on inhibition of platelet aggregation, inflammation and myonecrosis in acute coronary syndrome patients undergoing percutaneous coronary intervention: the ACCEL-LOADING-ACS (ACCELeRated Inhibition of Platelet Aggregation, Inflammation and Myonecrosis by Adjunctive Cilostazol Loading in Patients With Acute Coronary Syndrome) study. *Int J Cardiol* 2015;190:370–5.
 34. Xu LX, Chen KY, Liu T, et al. Adjunctive loading dose of cilostazol in preventing periprocedural myocardial infarction. *Cardiovasc Ther* 2016;34:225–33.
 35. Zheng XT, Chen KY, Liu T, et al. Low-dose adjunctive cilostazol in patients with complex lesions undergoing percutaneous coronary intervention. *Clin Exp Pharmacol Physiol* 2016;43:29–33.
 36. Chapman TM, Goa KL. Cilostazol: a review of its use in intermittent claudication. *Am J Cardiovasc Drugs* 2003;3:117–38.
 37. Tendera M, Aboyans V, Bartelink ML, et al. ESC guidelines on the diagnosis and treatment of peripheral artery diseases: document covering atherosclerotic disease of extracranial carotid and vertebral, mesenteric, renal, upper and lower extremity arteries: the Task Force on the Diagnosis and Treatment of Peripheral Artery Diseases of the European Society of Cardiology (ESC). *Eur Heart J* 2011;32:2851–906.