

An orbital roof and anterior skull base fracture: case report

P. GENNARO, V. MITRO, G. GABRIELE, F. GIOVANNETTI, A. FACCHINI

Department of Maxillofacial Surgery, Sapienza University of Rome, Rome, Italy

Abstract. – Blow-out fractures usually involve the orbit in the floor or in the medial wall. Anyway, if the roof of the orbit is thin and direct compressive or buckling forces impact the orbit the fracture can involve the upper roof. We describe the case of a blow-out fracture of the orbital roof with enophthalmus and cerebrospinal fluid leak from lacero-contusive sub-ciliar wound.

Key Words:

Orbital roof, Fracture, Blow out.

Introduction

Orbital fractures can occur in patients who have suffered blunt injury from traffic accidents, falls, violence or other orbital trauma¹⁻⁶.

The term blow-out fracture was coined by Smith and Regan⁷ to describe an orbital floor fracture caused by a very sudden increase in intraorbital pressure without concomitant fracture of the orbital rim. Most blow-out fractures involve the orbital floor. Less often the medial orbital wall is fractured, either alone or in conjunction with the floor.⁸ Upward displacement fractures involving the orbital roof occur usually accompanied by extensive craniofacial fractures and involvement of the orbital rim. This type of fracture doesn't share the hydraulic etiology of true isolated blow-out fractures. Anyway if the skull base is thin the fracture can share such etiology, as in the case reported.

Early diagnosis and treatment are very important since complications such as irreversible damage on the optic nerve and ascending infections favored by liquor fistula can occur. Orbital computerized tomography (CT) with thin axial and coronal sections should be performed in an acute traumatized patient with a concurrent orbital trauma.

Reconstruction of the orbital roof is the key step of the surgical treatment and should be performed in every case.

We present the case of a fracture of the orbital roof with extent of the medial wall, the posterior wall until the frontal sinuses and the anterior skull base.

Case Report

A male patient of 46 year old was admitted to Emergency Department of Policlinico Umberto I, Rome. The man had been subjected to a severe aggression. He referred intense pain and had a notable edema of the left hemiface as well as a lacero-contusive wound under the inferior eyelid. Ocular kinetic could not be evaluated. The CT showed a break in the continuation of the left orbital roof, the posterior wall of the left frontal sinus and the anterior skull base; the fracture resulted displaced and multifragmentary (Figure 1). Gassous bubbles in the frontal area were even present. The rectus superior and levator palpebrae superioris muscles were attracted to the edge of the fracture and the periorbital fat showed edematous hemorrhagic imbibition.

At our Department we found several additional signs. There was enophthalmus, mild ptosis with restricted eyelid elevation and important cerebrospinal fluid leakage. After consulting the ophthalmologist and the neurosurgeon the patient was brought to the operating theatre. The intervention was executed by the neurosurgeon and the maxillo-facial surgeon operating contextually. A coronal incision was performed, the frontal bone was exposed, and a galeal-pericranial flap was harvested. Then, an anterior craniotomy of the left frontal bone was executed. Next step consisted of the exposition of the fracture and of the reposition of the herniated orbital content (Figure 2). Therefore, the bone integrity was restored with a portion of splitted frontal bone (Figure 3). This portion was secured with a titanium plane plate (Figure 4). Then, a cranialization of the frontal sinuses with a cuff of temporal muscle and tissucol was performed (Figure 4). The bone fragments were covered by a galeal-pericranial

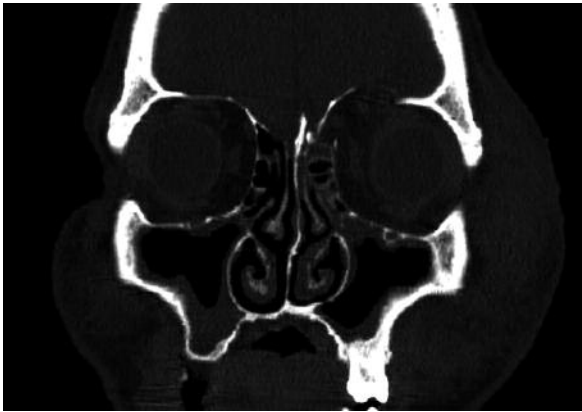


Figure 1. Coronal CT scan showing the displacement of the orbital roof and periorbital edema.

flap, which extended from the orbit roof to the upper-lateral portion of the ethmoidal cells. At this level a discontinuity was observed. Dural suspensions were executed and then the temporal bone was replaced with two plane plates. At two days from the intervention, the patient didn't show cerebro-spinal fluid leak anymore. He was discharged from the Hospital on his fourth post-operative day without complications. The following clinical examinations showed a progressive functional and aesthetic good outcome.

Discussion

Orbital fractures can occur in patients who have suffered blunt injury from traffic accidents, falls, violence or other orbital trauma¹⁻⁶.

The term 'orbital blow-out fracture' refers to the mechanism by which a blow to the eyeball is transposed to the orbital walls, causing them to fracture⁶. This often involves injury to the orbital floor^{4,9}.

The first recorded description was by Lang in

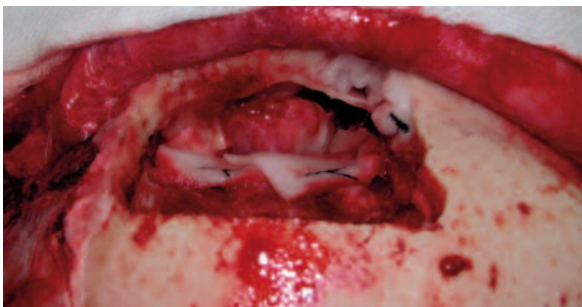

Figure 2. Intraoperative image that evidences the herniation of the orbital content into the anterior skull base.

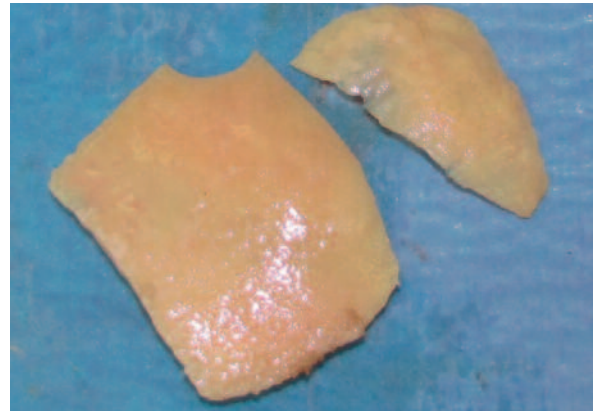


Figure 3. Frontal volet splitted and successively used to recover the roof's deficit.

1889¹⁰. Smith and Regan⁷ demonstrated that the orbital content is necessary to produce a typical orbital floor blow out fracture. Indeed, the sudden increase in intraorbital pressure causes the herniation of orbital content through the weakest part of the orbit.

Blow out fractures occur most often through the posterior orbital floor, medially to the infraorbital groove⁸. Less frequently, the orbital plate of the ethmoid is involved alone or in combination with the floor. Distribution of blow-out location results from a combination of bone's thinness and its geometric relation to the orbital axis.

Orbital roof fractures usually are part of severe craniofacial traumas. Displacement of the orbital rim can cause linear extension into or comminution of the orbital roof. In case of entrapment of the orbital soft tissues or persistent displacement of the globe, surgery is necessary to prevent permanent functional and aesthetic defect¹¹⁻¹³.

Mc Clurg and Swanson¹⁴ reported the first case of a roof fracture causing diplopia as part of a more extensive skull fracture.

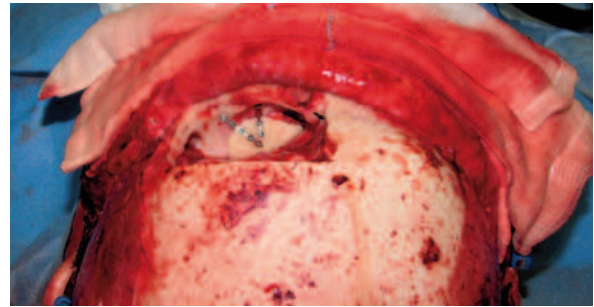


Figure 4. The splitted volet recovers the orbital roof and is stabilized by plane titanium plates.

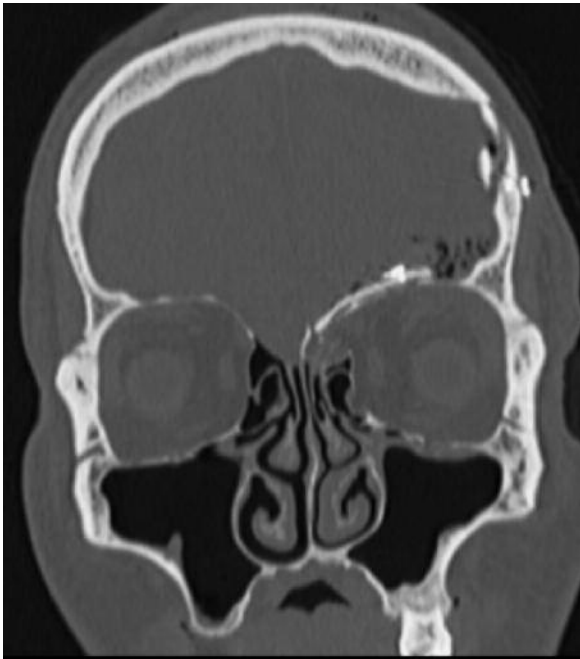


Figure 5. Coronal TC scan at two days after the intervention: bone integrity restored.

Fractures of the orbital roof not associated with fractures of the orbital rim are unusual. Isolated orbital roof fractures can derive from penetrating injuries¹⁵. Rarely, the orbital roof without can be blown downward by distant skull fractures. This results from a sudden increase in in-

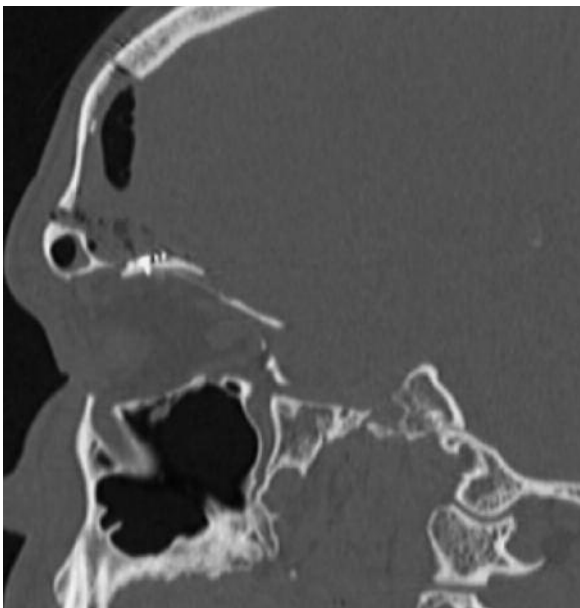


Figure 6. Sagittal TC scan evidences the continuity established by the osseous flap.

tracranial pressure transmitted through the anterior fossa and decompressed by a fracture of the orbital roof¹⁶.

The most appropriate timing for surgical repair after an orbital blow-out fracture is controversial^{1,4-6,10,11}. The current accepted indications are: internal orbital fracture with muscle incarceration resulting in ocular motility restriction with diplopia, early enophthalmos (> 2 mm), and large orbital defects ($> 50\%$ of the floor or medial wall)^{5,13,17}. Surgical intervention should be performed within 2 weeks^{18,19}.

For trapdoor fracture, early surgery within 2 to 4 days is more appropriate than a wait and watch period of 2 to 3 weeks⁴. The trapped perimuscular fat and connective tissue may set up a potential compartment-type situation leading to tissue ischemia and the possibility of resultant muscular and perimuscular fibrosis⁴.

In 1974, Putterman et al²⁰ recommended that patients with pure blow-out fractures had to be kept under observation for 4 to 6 months at least to determine the rate of improvement. In 1991, de Man et al²¹ also suggested that a “wait-and-watch” policy was appropriate for blow-out fractures in adults.

Dutton et al¹⁷ felt, however, that in some situations surgical repair should not be delayed, and therefore summarized the indications for early surgery (within one to two weeks). Furthermore, Kwon et al²² reported that the recovery period in children was shorter when surgical intervention was performed within 5 days after injury. However, surgery might be required within 2 weeks in adults. Bansagi and Meyer²³ also found that early surgical intervention (< 2 weeks) resulted in a more complete return of ocular motility in a pediatric population, while Egbert et al⁹ suggested surgery should be performed within 7 days for more rapid recovery. Egbert et al⁹ also found surgery within one month of injury resulted in improvements of preoperative conduction deficit and diplopia in all his patients.

We think that when an orbital fracture is complicated by exophthalmus, enophthalmus, diplopia or liquor fistula as in the previously described case, the intervention must be performed as soon as possible. We treated two days after the patient was injured an orbital roof fracture which extended to the ethmoidal planum, the posterior wall of frontal sinus and the anterior skull base.

Isolated fractures of the orbital roof occur rarely and are often found when a thin anterior skull base is present. This thinness makes the re-

duction of the fragments difficult and unstable. For these types of fractures there exist several reconstruction options. Among them are alloplastic materials and titanium meshes plates.

For our patient we chose to use autolog bone taken from the frontal volet because the fracture included ethmoidal planum and the possible communication with the nasal cavity raised the risk of ascending infections. Autolog bone tissue lowers the risk of infection and eliminates the risk of rejection. The volume of the orbital cavity was restored, the frontal sinuses cranialized and the cerebro-spinal fluid leakage interrupted. The functional and aesthetic outcome of the patient was satisfactory.

References

- 1) ROSADO P, DE VICENTE JC. Retrospective analysis of 314 orbital fractures. *Oral Surg Oral Med Oral Pathol Oral Radiol Endod* 2011 Apr 20.
- 2) RINNA C, ROCCHI G, VENTUCCI E, PAGNONI M, IANNETTI G. Bilateral orbital roof fracture. *J Craniofac* 2009; 20: 737-734.
- 3) JOSEPH JM, GLAVAS IP. Orbital fractures: a review. *Clin Ophthalmol* 2011; 5: 95-100.
- 4) JORDAN DR, ALLEN LH, WHITE J, HARVEY J, PASHBY R, ESMAELI B. Intervention within days for some orbital floor fractures: the white-eyed blowout. *Ophthalmic Plast Reconstr Surg* 1998; 14: 379-390.
- 5) HATTON MP, WATKINS LM, RUBIN PAD. Orbital fractures in children. *Ophthalmic Plast Reconstr Surg* 2001; 17: 174-179.
- 6) SUGAMATA A, YOSHIZAWA N. Clinical analysis of orbital blowout fractures caused by a globe-to-wall contact mechanism. *J Plast Surg Hand Surg* 2010; 44: 278-281.
- 7) SMITH B, REGAN WF Sr. Blowout fracture of the orbit: mechanism and correction of the internal orbit fractures. *Am J Ophthalmol* 1957; 44: 733-739.
- 8) JONES DEP, EVANS JNG. "Blowout" fractures of the orbit: an investigation into their anatomical basis. *J Laryngol Otol* 1967; 81: 1109-1120.
- 9) EGBERT JE, MAY K, KERSTEN RC, KULWIN DR. Pediatric orbital floor fracture: direct extraocular muscle involvement. *Ophthalmology* 2000; 107: 1875-1879.
- 10) LANG W. Traumatic enophthalmos with retention of perfect acuity of vision. *Trans Ophthalmol Soc UK* 1889; 9: 41-5.
- 11) STRANC MF, GUSTAVSON EH. Primary treatment of fractures of the orbital roof. *Proc R Soc Med* 1973; 66: 303-304
- 12) GERBINO G, ROCCIA F, BIANCHI FA, ZAVATTERO E. Surgical management of orbital trapdoor fracture in a pediatric population. *J Oral Maxillofac Surg* 2010; 68: 1310-1316.
- 13) CHEN CT, CHEN YR. Update on orbital reconstruction. *Curr Opin Otolaryngol Head Neck Surg* 2010; 18: 311-316.
- 14) MC CLURG FL, SWANSON PJ. An orbital roof fracture causing diplopia. *Arch Otolaryngol* 1976; 102: 497-98
- 15) GUYOT L, LARI N, BENSO-LAYOUN C, DENIS D, CHOSSEGROS C, THIERY G. Orbital fractures in children. *J Fr Ophtalmol* 2011; 34: 265-274.
- 16) BRUCOLI M, GIARDA M, BENECH A. A peculiar orbital roof blow-in fracture. *J Craniofac Surg* 2011; 22: 358-360.
- 17) DUTTON JJ, MANSON PN, ILIFF N, PUTTERMAN AM. Management of blow-out fractures of the orbital floor. *Surv Ophthalmol* 1990; 35: 279-298.
- 18) DULLEY B, FELLS P. Long-term follow-up of orbital floor fractures with and without surgery. *Mod Probl Ophthalmol* 1975; 14: 467-470.
- 19) WILKINS RB, HAVINS WE. Current treatment of blowout fractures. *Ophthalmology* 1982; 89: 464-466.
- 20) PUTTERMAN AM, STEVEN T, URIST MJ. Non-surgical management of blow-out fractures of the orbital floor. *Am J Ophthalmol* 1974; 77: 232-239.
- 21) DE MAN K, WJUNGAARDE R, HES J, DE JONG PT. Influence of age on the management of blow-out fractures of the orbital floor. *Int J Oral Maxillofac Surg* 1991; 20: 330-336
- 22) KWON JH, MOON JH, KWON MS, CHO JH. The differences of blowout fracture of the inferior orbital wall between children and adults. *Arch Otolaryngol Head Neck Surg* 2005; 131: 723-727
- 23) BANSAGI ZC, MEYER DR. Internal orbital fractures in the pediatric age group: characterization and management. *Ophthalmology* 2000; 107: 829-836.