

# Our supramicrosurgical experience of lymphaticovenular anastomosis in lymphoedema patients to prevent cellulitis

P. GENNARO<sup>1</sup>, G. GABRIELE<sup>1</sup>, C. SALINI<sup>1</sup>, G. CHISCI<sup>1</sup>, F. CASCINO, J.-F. XU<sup>3</sup>, C. UNGARI<sup>2</sup>

<sup>1</sup>Department of Maxillofacial Surgery, University of Siena, Siena, Italy

<sup>2</sup>Department of Maxillofacial Surgery, "Sapienza" University of Rome, Rome, Italy

<sup>3</sup>Department of Dentistry, Tongde Hospital, Hangzhou, Zhejiang Province, China

**Abstract.** – **OBJECTIVE:** Aim of this paper is to present our reduction of the frequency of cellulitis before and after supramicrosurgical lymphaticovenular anastomosis (s-LVA) in lymphoedema patients, and discuss the possibility to perform this technique outside Japan.

**PATIENTS AND METHODS:** 37 patients affected by lymphoedema were enrolled. All patients received preoperative indocyanine green lymphography. Under local anaesthesia s-LVA was performed on all patients. All patients were followed for 1 year. Lymphoedema was staged using the lymphoedema staging classification recommended by the International Society of Lymphology. Cellulitis rate was recorded for all patients the year before and after the s-LVA. A *t*-test was used to evaluate differences in the frequency of cellulitis the year before surgery and the year following surgery.

**RESULTS:** Cellulitis incidence decreased in all patients, with a mean 1.7 cases the year before s-LVA and 0.1 the year after s-LVA. A significant difference between preoperative and postoperative cellulitis rate was found ( $p = 0.0012$ ).

**CONCLUSIONS:** This study reports our s-LVA case series of lymphoedema patients. With the proper learning curve, s-LVA may be reproduced and lymphoedema patients may gain a better quality of life and a reduced cellulitis rate.

Key Words:

Supramicrosurgical, Lymphaticovenular, Anastomosis, LVA, Cellulitis, Lymphoedema.

## Introduction

Lymphoedema is a pathology characterized by a limb accumulation of subcutaneous protein-rich fluid due to a lymphatic system disorder. While the primary lymphoedema is commonly caused by congenital abnormalities, secondary lymphoe-

dema is caused in most cases by the obstructions or the stenosis of lymph vessels in relation with the oncological therapies<sup>1</sup>. Other causes are accidental or iatrogenic lesions of the lymphatic vessels.

Lymphoedema usually occurs in 6-63% of patients who received a radiotherapy and/or surgery as cancer therapy. The rise of the pathology may occur immediately after this therapy or may be delayed<sup>2</sup>. Even if the lymphoedema does not represent a death risk for patients, the impact of the external changes in a lower quality of life is significative<sup>3</sup>. Lymphangiosarcoma has been described as a rare complication, too<sup>4</sup>. Additionally, a very common and severe complication is cellulitis of the affected limb<sup>5</sup>.

The use of penicillin is one of the most common treatments of symptomatic cellulitis; however, this is not a decisive treatment and cellulitis may relapse after or even during the therapy<sup>6</sup>. Another common treatment is drainage. Complex physical therapy (CPT) is a recent treatment introduced for lymphoedema that reduces the limb circumference and the occurrence of cellulitis<sup>7,8</sup>.

The lymphaticovenular anastomosis (LVA) is a microsurgical technique very effective in improving limb circumference and alleviating dermal sclerosis<sup>9-14</sup>.

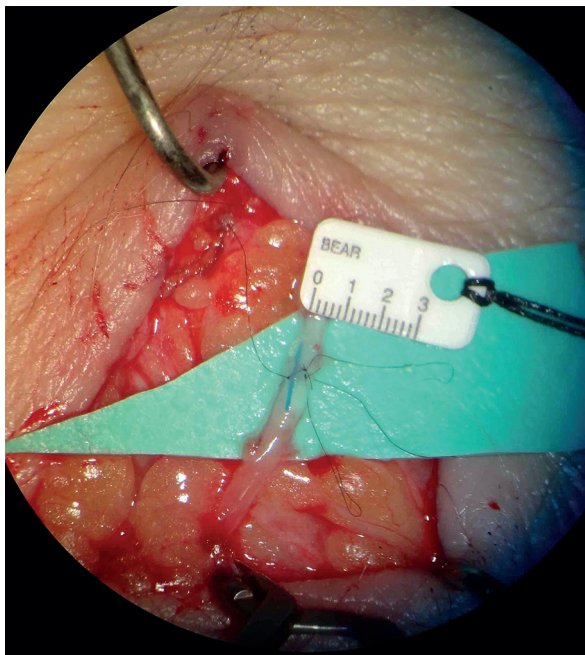
The LVA technique rapidly evolved in recent years. In 2014, Yamamoto et al<sup>15</sup> described a ladder-shaped LVA, 3 lymphatic vessels and 1 vein were anastomosed in a side-to-side fashion; further, in 2015 Yamamoto et al<sup>16</sup> reported the parachute technique, a simplified technique to perform the side to end supramicrosurgical lymphaticovenular anastomosis (s-LVA) while maintaining efficacy comparable to the conventional technique.

The limitation of this technique is its reproducibility; commonly, mainly Japanese authors reported the efficacy of LVA and very few papers reported the effect of s-LVA on cellulitis incidence. Campisi et al<sup>17</sup> in 2007 reported his experience with LVA, with 87% reduction of cellulitis incidence; Mihara et al<sup>12</sup> in 2014 reported a significant rate of reduction after LVA in lymphoedema patients.

The purpose of this paper is to compare the frequency of cellulitis before and after minimally invasive s-LVA in patients with arm/leg lymphoedema and discuss the reproducibility of this technique.

### Patients and Methods

This is a retrospective observational study that reports the clinical data of preoperative and postoperative cellulitis rate occurred in 37 lymphoedema patients (M:2, F:35) operated with s-LVA from February 2012 to April 2013 at the Department of Maxillofacial Surgery, University of Siena, Italy. The participants signed an informed consent agreement. Among the 37



**Figure 1.** Image of an anastomosis between a lymphatic of approximately 0.5 mm diameter (at the top) and a venule of the same size. Inside the anastomosis a stent made with 7/0 ethilon suture was present: this stent was used to ensure the patency of the anastomosis and removed before the last suture. This lambda-shaped anastomosis allows efficient lymphaticovenular anastomoses to be performed simultaneously by a team of surgeons, resulting in an increased number of bypasses<sup>22</sup>.

patients, 10 patients presented upper limb lymphoedema and 27 lower limb lymphoedema. 4 patients presented primary lymphoedema, while 26 patients reported lymphoedema due to breast cancer, and 7 patients reported lymphoedema due to pelvic cancer.

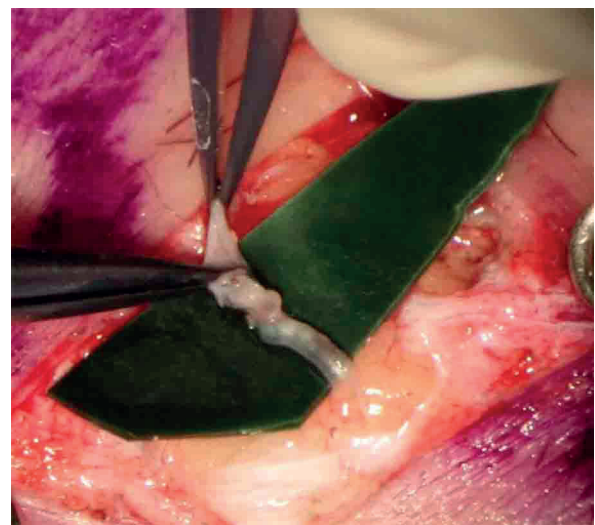
The diagnostic criteria of lymphoedema were based on indocyanine green (ICG) lymphography findings, clinical criteria, lymphoscintigraphy as well as limb circumference<sup>18-21</sup>. Lymphoedema was staged using the lymphoedema staging classification recommended by the International Society of Lymphology.

The diagnostic criteria for cellulitis were a fever of 38.5°C or higher and warmth/redness in the affected limb.

Lymphography was performed with two injections with green indocyanine (Pulsion®) between first and second, fourth and fifth toes of the limb; a superficial vein mapping with Accuvein device was performed before surgery too.

### Surgical Technique

Under local anaesthesia with 1% adrenaline xylocaine, a skin incision was performed for each site. The subcutaneous tissue was dissected under a high magnification operating microscope. Lymphatic collectors and adjacent subcutaneous veins were identified. Vessels were dissected and 4 or 5 11/0 endoluminal sutures with a 50-micron needle were performed (Figure 1). After each anastomosis, the milk-test was performed to check the patency<sup>22</sup> (Figure 2). Afterwards, the skin was sutured with continu-



**Figure 2.** Intraoperative figure after s-LVA with milk-test performance: milk-test evaluates the patency of the anastomosis.

**Table I.** This table shows the *p*-values of patients before and after LVA, and patients characteristics. Two-tailed *p*-values of <0.05 were considered significant if not otherwise specified.

Patient characteristics		Number	Mean number of lymphangitis in the year before LVA	Mean number of lymphangitis in the year after LVA*
Total	37	1.7	0.1	
Location	upper limb	10	1.4	0.07
	lower limb	27	2.8	0.2
ISL stage	111	0.3	0	
ISL stage	2a	11	1.9	0
ISL stage	2b	13	3.3	0.3
ISL stage	32	2.5	0	
Aetiology	primary	4	3.8	0
	secondary	33	1.5	0.1
Cause	pelvic cancer	7	1.8	0.3
	breast cancer	26	1.5	0.1
Radiotherapy	yes	24	1.6	0.1
	no	13	2.8	0.2

ous 6/0 absorbable microsutures. The purpose of this technique was to drain the accumulated lymphatic fluid into the venous system. The anastomotic configuration was chosen on the basis of the vessels calibre; the most performed was the end-to-end configuration, while the side-to-end configuration was performed if the venular calibre was twice the lymphatic vessel calibre<sup>23</sup>. The average number of anastomosis performed was 3 per patient, with an average operation time of 3 hours.

The incidence of cellulitis before surgery was recorded in the patient history collection, while postoperative cellulitis was collected with telephone interviews.

Standardized CPT with compression garments was performed 1 year before surgery with 20 cycles of therapy with lymphatic drainages, followed by bandage with progressive compression; two weeks after s-LVA CPT was continued post-operatively for 1 year. Oral amoxicillin (1 g) was prescribed for 2 days after s-LVA.

The evaluated parameters consisted in: age at the time of surgery, sex, radiotherapy, affected limb, lymphoedema stage, time of lymphoedema before surgery, follow-up period, number of cellulitis occurred in the year before surgery, number of cellulitis after surgery.

The frequency of cellulitis in the year before and after s-LVA was compared.

### Statistical Analysis

The *t*-test was used to evaluate if the decrease of cellulitis was significant. If not

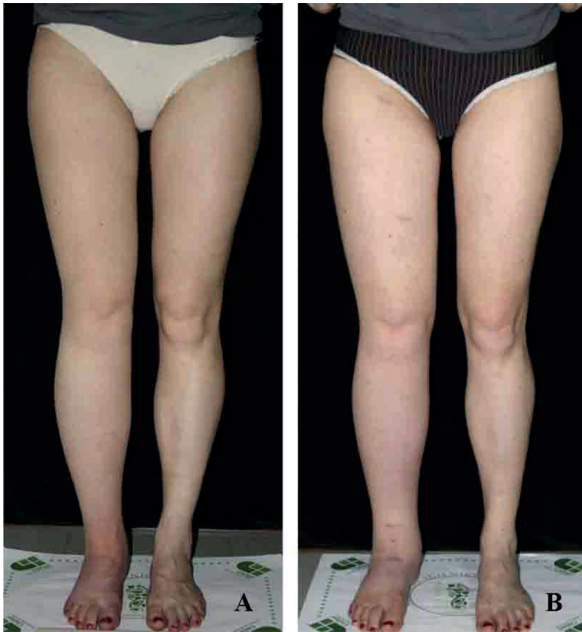otherwise specified two-tailed *p*-values < 0.05 were considered significant.

### Results

S-LVA resulted successful in all patients as the intraoperative wash-out of the LVA resulted positive in all patients. Table I reports population data of the patients. The incidence of cellulitis significantly decreased in all patients; passing from an average of 1.7 cases the year before s-LVA to 0.1 the year after surgery (*p* = .0012). Cellulitis incidence in upper limb lymphedema dropped from an average of 1.4 cases the year before s-LVA to 0.07 cases the year after surgery while in lower limb lymphedema cellulitis incidence decreased from an average of 2.8 cases the year before s-LVA to 0.2 cases the year after surgery. All patients with ISL stage 1, 2a and 3 showed a reduction of cellulitis incidence to zero cases the year after LVA while 2b ISL stage patients showed a cellulitis incidence decreased from an average of 3.3 the year before s-LVA to an average of 0.3 the year after surgery. s-LVA appeared to reduce the instances of cellulitis on all patients. Two typical cases are reported in Figure 3 and Figure 4.

### Discussion

Cellulitis is a very serious episode that degrades the quality of life of many patients. Every



**Figure 3.** Clinical appearance of right lower limb before (A) and after (B) s-LVA. This patient reported lymphedema of the lower right limb after ovarian cancer surgery; after the s-LVA the limb circumference reduced and no cellulitis were reported in the year after s-LVA.

case damages the lymphatic vessels and may worsen the lymphoedema. Lymph vessels and subcutaneous tissue undergo to cellulitis-induced

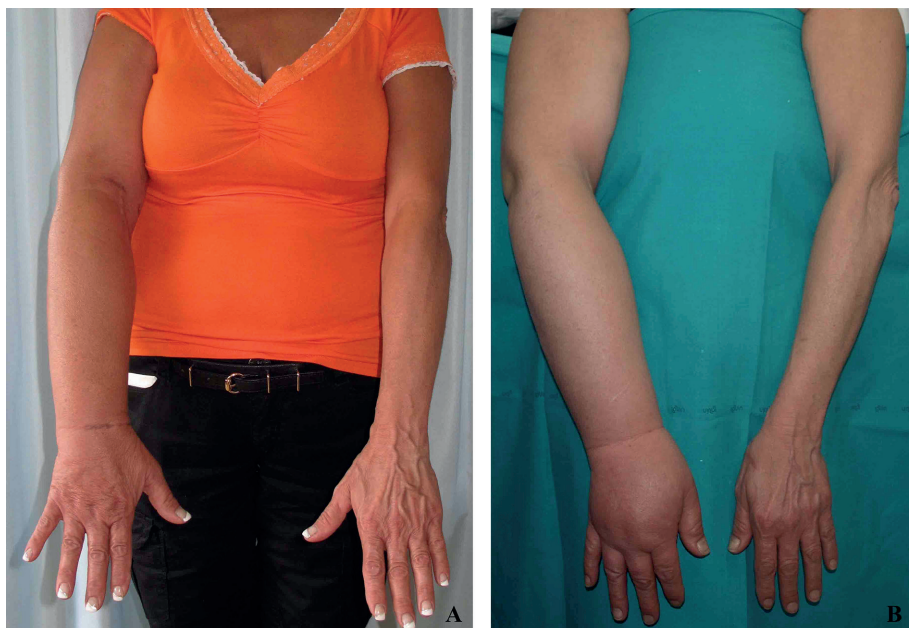fibrosis, leading to a vicious cycle where the lymphoedema worsens and cellulitis becomes easier and easier to develop<sup>24</sup>.

Minimizing the lymphoedema progression is required in order to prevent and reduce the frequency of cellulitis. LVA has proven its reliability in reducing the incidence of cellulitis, as recently reported by Mihara et al<sup>12</sup>. Campisi et al<sup>25</sup> reported good results with LVA, too. Onoda et al<sup>26</sup> reported satisfactory results in the reduction of cellulitis in lymphoedema patients with LVA, and Boccardo et al<sup>27</sup> reported a positive outcome with the use of the LYMPHA method.

All papers that report the role of s-LVA in lymphoedema patients are usually Japanese papers; the main argument against this technique is its difficult reproducibility out of Japan.

In the present study, we performed s-LVA on 37 Italian patients and reduced cellulitis incidence from an average of 1.7 episodes per year before s-LVA to an average of 0.1 cases per year after s-LVA. Patient with 2a and 2b ISL stage reported the most marked decrease.

The traditional LVA technique uses lymphatic vessels at the root of the limb, while s-LVA consists in a supramicrosurgical endoluminal anastomosis performed on small veins with 0.2 mm diameter all over the limb; with s-LVA smaller



**Figure 4.** Clinical appearance of an upper limb in a lymphoedema case after the s-LVA (A). Clinical appearance before s-LVA (B). This patient reported lymphedema after breast cancer surgery, with numerous cellulitis; after s-LVA the limb circumference reduced and no cellulitis were reported in the year after s-LVA.

lymphatic vessels may be detected and used for the supramicrosurgical anastomosis with smaller veins.

S-LVA reduces cellulitis rate in lymphoedema patients due to the formation of anastomosis and lets the lymph flow into the peripheral venular circulation, with a reduction of stagnant lymph. The concomitant use of CPT and s-LVA with their different mechanisms may also have a synergistic effect on improving lymphatic stasis.

A standard prophylaxis protocol for cellulitis in lymphoedema patients is yet to be present in literature; s-LVA may play an important role in the prevention of future cellulitis cases after cancer surgery and/or radiotherapy.

In this study, we report a consistent number of lymphoedema patients operated in Italy with s-LVA. This paper dispels the myth of an irreproducible technique and opens the gates for a worldwide dissemination of the technique as the reported results similar to Mihara et al<sup>12</sup> suggest the possibility of diffusion of this technique.

S-LVA is a standardized, reliable and reproducible technique that finds its main indication in lymphoedema treatment. The reduction of cellulitis in these patients after s-LVA adds credit to this technique while validating it.

The recent introduction of ICG lymphography and the possibility to perform the LVA operation via the supramicrosurgical technique and under local anesthesia makes this a minimally invasive approach<sup>10</sup>. ICG lymphography is a useful imaging technique for both beginner and advanced microsurgeon to investigate lymphatic disorders and to decide the best sites for skin incisions. Even though the number of patients in this study was relatively small, a positive trend was evidenced in all subclasses reported in Table I. Further, in patients with prolonged follow-up (2 years), the cellulitis trend kept going towards even lower rates.

The limitation of the present study is represented by the fact that it is a retrospective study and no consideration was given to the volume reduction. Our study group is now working to another article with a greater population focused on limb volume reduction after s-LVA<sup>28</sup>.

## Conclusions

A significant reduction of cellulitis after s-LVA was reported in all patients enrolled in this study. S-LVA is a standardized, minimally invasive and easily accepted by patients operation that influ-

ences the incidence of cellulitis in lymphoedema patients. The main argument against s-LVA in lymphoedema patients is that the positive results present in literature come only from Japanese microsurgeons. This paper reports similar results out of Japan, suggesting the possibility of diffusion of this technique.

## Conflict of Interest

The authors declare no conflicts of interest.

## References

- 1) OLSZEWSKI W. On the pathomechanism of development of postsurgical lymphoedema. *Lymphology* 1973; 6: 35-51.
- 2) CORMIER JN, ASKEW RL, MUNGOVAN KS, XING Y, ROSS MI, ARMER JM. Lymphoedema beyond breast cancer: a systematic review and meta-analysis of cancer-related secondary lymphoedema. *Cancer* 2010; 116: 5138-5149.
- 3) McWAYNE J, HEINEY SP. Psychologic and social sequelae of secondary lymphoedema: a review. *Cancer* 2005; 104: 457-66.
- 4) COZEN W, BERNSTEIN L, WANG F, PRESS MF, MACK TM. The risk of angiosarcoma following primary breast cancer. *Br J Cancer* 1999; 81: 532-536.
- 5) SIMON MS, CODY RL. Cellulitis after axillary lymph node dissection for carcinoma of the breast. *Am J Med* 1992; 93: 543-548.
- 6) OLSZEWSKI WL, JAMAL S, MANOKARAN G, TRIPATHI FM, ZALESKA M, STELMACH E. The effectiveness of long-acting penicillin (penidur) in preventing recurrences of dermatolymphangioadenitis (DLA) and controlling skin, deep tissues, and lymph bacterial flora in patients with "filarial" lymphoedema. *Lymphology* 2005; 38: 66-80.
- 7) VIGNES S, PORCHER R, ARRAULT M, DUPUY A. Long-term management of breast cancer-related lymphoedema after intensive decongestive physiotherapy. *Breast Cancer Res Treat* 2007; 101: 285-290.
- 8) FOLDI E. Prevention of dermatolymphangioadenitis by combined physiotherapy of the swollen arm after treatment for breast cancer. *Lymphology* 1996; 29: 48-49.
- 9) MIHARA M, HARA H, NARUSHIMA M, HAYASHI Y, YAMAMOTO T, OSHIMA A, KIKUCHI K, MURAI N, KOSHIMA I. Lower limb lymphoedema treated with lymphatico-venous anastomosis based on pre- and intraoperative ICG lymphography and non-contact vein visualization: A case report. *Microsurgery* 2012; 32: 227-230.
- 10) MIHARA M, HARA H, KIKUCHI K, YAMAMOTO T, IIDA T, NARUSHIMA M, ARAKI J, MURAI N, MITSUI K, GENNARO P, GABRIELE G, KOSHIMA I. Scarless lymphatic venous anastomosis for latent and early-stage lymphoedema using indocyanine green lymphography

- and non-invasive instruments for visualising subcutaneous vein. *J Plast Reconstr Aesthet Surg* 2012; 65: 1551-1558.
- 11) MIHARA M, HARA H, HAYASHI Y, IIDA T, ARAKI J, YAMAMOTO T, TODOKORO T, NARUSHIMA M, MURAI N, KOSHIMA I. Upper-limb lymphoedema treated aesthetically with lymphaticovenous anastomosis using indocyanine green lymphography and noncontact vein visualization. *J Reconstr Microsurg* 2012; 28: 327-332.
  - 12) MIHARA M, HARA H, FURNISS D, NARUSHIMA M, IIDA T, KIKUCHI K, OHTSU H, GENNARO P, GABRIELE G, MURAI N. Lymphaticovenular anastomosis to prevent cellulitis associated with lymphoedema. *Br J Surg* 2014; 101: 1391-1396.
  - 13) KOSHIMA I, NANBA Y, TSUTSUI T, TAKAHASHI Y, ITOH S, FUJITSU M. Minimal invasive lymphaticovenular anastomosis under local anesthesia for leg lymphoedema: is it effective for stage III and IV? *Ann Plast Surg* 2004; 53: 261-266.
  - 14) KOSHIMA I, NANBA Y, TSUTSUI T, TAKAHASHI Y, ITOH S. Long-term follow-up after lymphaticovenular anastomosis for lymphoedema in the leg. *J Reconstr Microsurg* 2003; 19: 209-215.
  - 15) YAMAMOTO T, KIKUCHI K, YOSHIMATSU H, KOSHIMA I. Ladder-shaped lymphaticovenular anastomosis using multiple side-to-side lymphatic anastomoses for a leg lymphedema patient. *Microsurgery* 2014; 34: 404-408.
  - 16) YAMAMOTO T, CHEN WF, YAMAMOTO N, YOSHIMATSU H, TASHIRO K, KOSHIMA I. Technical simplification of the supramicrosurgical side-to-end lymphaticovenular anastomosis using the parachute technique. *Microsurgery* 2015; 35: 129-134.
  - 17) CAMPISI C, ERETTA C, PERTILE D, DA RIN E, CAMPISI C, MACCIÒ A, CAMPISI M, ACCOGLI S, BELLINI C, BONIOLI E, BOCCARDO F. Microsurgery for treatment of peripheral lymphedema: long-term outcome and future perspectives. *Microsurgery* 2007; 27: 333-338.
  - 18) YAMAMOTO T, YOSHIMATSU H, NARUSHIMA M, YAMAMOTO N, HAYASHI A, KOSHIMA I. Indocyanine Green Lymphography Findings in Primary Leg Lymphedema. *J Reconstr Microsurg* 2016; 32: 72-79.
  - 19) YAMAMOTO T, NARUSHIMA M, DOI K, OSHIMA A, OGATA F, MIHARA M, KOSHIMA I, MUNDINGER GS. Characteristic indocyanine green lymphography findings in lower extremity lymphedema: the generation of a novel lymphedema severity staging system using dermal backflow patterns. *Plast Reconstr Surg* 2011; 127: 1979-1986.
  - 20) YAMAMOTO T, YAMAMOTO N, DOI K, OSHIMA A, YOSHIMATSU H, TODOKORO T, OGATA F, MIHARA M, NARUSHIMA M, IIDA T, KOSHIMA I. Indocyanine green-enhanced lymphography for upper extremity lymphedema: a novel severity staging system using dermal backflow patterns. *Plast Reconstr Surg* 2011; 128: 941-947.
  - 21) YAMAMOTO T, MATSUDA N, DOI K, OSHIMA A, YOSHIMATSU H, TODOKORO T, OGATA F, MIHARA M, NARUSHIMA M, IIDA T, KOSHIMA I. The earliest finding of indocyanine green lymphography in asymptomatic limbs of lower extremity lymphedema patients secondary to cancer treatment: the modified dermal backflow stage and concept of subclinical lymphedema. *Plast Reconstr Surg* 2011; 128: 314e-321e.
  - 22) YAMAMOTO T, NARUSHIMA M, KIKUCHI K, YOSHIMATSU H, TODOKORO T, MIHARA M, KOSHIMA I. Lambda-shaped anastomosis with intravascular stenting method for safe and effective lymphaticovenular anastomosis. *Plast Reconstr Surg* 2011; 127(5): 1987-92.
  - 23) YAMAMOTO T, YOSHIMATSU H, NARUSHIMA M, SEKI Y, YAMAMOTO N, SHIM TW, KOSHIMA I. A modified side-to-end lymphaticovenular anastomosis. *Microsurg* 2013; 33: 130-133.
  - 24) MIHARA M, HARA H, HAYASHI Y, NARUSHIMA M, YAMAMOTO T, TODOKORO T, IIDA T, SAWAMOTO N, ARAKI J, KIKUCHI K, MURAI N, OKITSU T, KISU I, KOSHIMA I. Pathological steps of cancer-related lymphoedema: histological changes in the collecting lymphatic vessels after lymphadenectomy. *PLoS One* 2012; 7: e41126.
  - 25) CAMPISI C, BELLINI C, CAMPISI C, ACCOGLI S, BONIOLI E, BOCCARDO F. Microsurgery for lymphoedema: clinical research and long-term results. *Microsurgery* 2010; 30: 256-260.
  - 26) ONODA S, TODOKORO T, HARA H, AZUMA S, GOTO A. Minimally invasive multiple lymphaticovenular anastomosis at the ankle for the prevention of lower leg lymphedema. *Microsurgery* 2014; 34: 372-376.
  - 27) BOCCARDO F, CASABONA F, DECIAN F, FRIEDMAN D, MURELLI F, PUGLISI M, CAMPISI CC, MOLINARI L, SPINACI S, DESSALVI S, CAMPISI C. Lymphatic microsurgical preventing healing approach (LYMPHA) for primary surgical prevention of breast cancer-related lymphedema: over 4 years follow-up. *Microsurg* 2014; 34: 421-424.
  - 28) GENNARO P, GABRIELE G, MIHARA M, KIKUCHI K, SALINI C, ABOH I, CASCINO F, CHISCI G, UNGARI C. Supramicrosurgical lymphaticovenular anastomosis (LVA) in treating lymphoedema: 36-months preliminary report. *Eur Rev Med Pharmacol Sci* 2016; 20: 4642-4653.