

## From surgery to neurosurgery: our experience on the efficacy of fleece-bound sealing (TachoSil®) for dural repair

S. ULIVIERI<sup>1</sup>, G. PERI<sup>1</sup>, G. TIEZZI<sup>1</sup>, E. MILEO<sup>1</sup>, A. GIORGIO<sup>2</sup>, G. OLIVERI<sup>1</sup>

**SUMMARY:** From surgery to neurosurgery: our experience on the efficacy of fleece-bound sealing (TachoSil®) for dural repair.

S. ULIVIERI, G. PERI, G. TIEZZI, E. MILEO, A. GIORGIO, G. OLIVERI

*Aim.* To report on our routine use of TachoSil® for dural repair in neurosurgical practice.

*Method.* TachoSil® has been applied in different fields of surgery thus far. When using TachoSil®, fibrinogen and thrombin is provided locally at the site of the dural defects. Upon contact with fluid, the clot-

ting factors of TachoSil® dissolve and form a fibrin network, which glues the collagen sponge to the wound surface.

*Results.* In our experience, TachoSil® was found to be effective as support for the suture of the dura in patients undergoing spinal and cranial neurosurgical operations. Two illustrative examples are shown.

*Conclusions.* Our procedure showed that closing the dural defect with TachoSil® is a technically simple, reliable and safe method for patients. Indeed, no post-operative cerebrospinal fluid leakage was observed. Nonetheless, further studies with larger sample size are warranted to confirm the efficacy of TachoSil® patches for dural repair.

KEY WORDS: Cerebrospinal fluid leakage - Spinal surgery - Durotomy.

### Introduction

Dural repair remains a source of morbidity during and following neurosurgery operations (1, 2). Postoperative cerebrospinal fluid (CSF) leakage remains the most serious and life-threatening complication. Persistent CSF leakage is a significant concern for surgeons, as this complication has been associated with increased time of hospitalization, worse neurological outcome, and development of CSF fistule (3).

The treatment of choice for durotomy, either incidental or intended, is primary repair (4). The method of repair and subsequent management of patients with incidental durotomy has been previously reported in literature. Various methods have been suggested but the principal aim is first expose and visualize the tear and then repair it with a non-absorbable suture (1).

The products that can be used during surgery may be classified as topical haemostats, sealants, and adhesives (4). Haemostats favor blood clotting. Sealant can

create sealing barriers. Adhesive is able to bond tissue components together. Collagen, gelatin, and cellulose are examples of haemostat agents (5). TachoSil® (haemostatic surgical patch; Nycomed, Linz, Austria) is a fixed combination of a collagen matrix coated with two coagulation factors such as fibrinogen and thrombin. TachoSil® is indicated in surgery as supportive treatment for improvement of haemostasis, to promote tissue sealing, and for suture support in vascular surgery where standard techniques turn out to be insufficient (6, 7).

The aim of this study is to evaluate and report the clinical experience of the authors on the use of TachoSil® in closing CSF leakage after durotomy in spinal and cranial neurosurgical operations.

### Case reports

Since the TachoSil® patch was also reported to be useful for sealing surgical resection surfaces, we postulated it to be of value also for dural repair in which fistula formation continued to be a problem. Covering of the stapling line on the cut surface of the dura therefore became a routine part of the procedure in our Neurosurgical Center since 2011.

Illustrative examples of our experience in using Ta-

<sup>1</sup> Department of Neurosurgery, Policlinico "Santa Maria alle Scotte", Siena, Italy  
<sup>2</sup> Department of Medicine, Surgery and Neuroscience, University of Siena, Italy

Corresponding Author: Simone Ulivieri, email: simone.ulivieri@email.it

© Copyright 2014, CIC Edizioni Internazionali, Roma

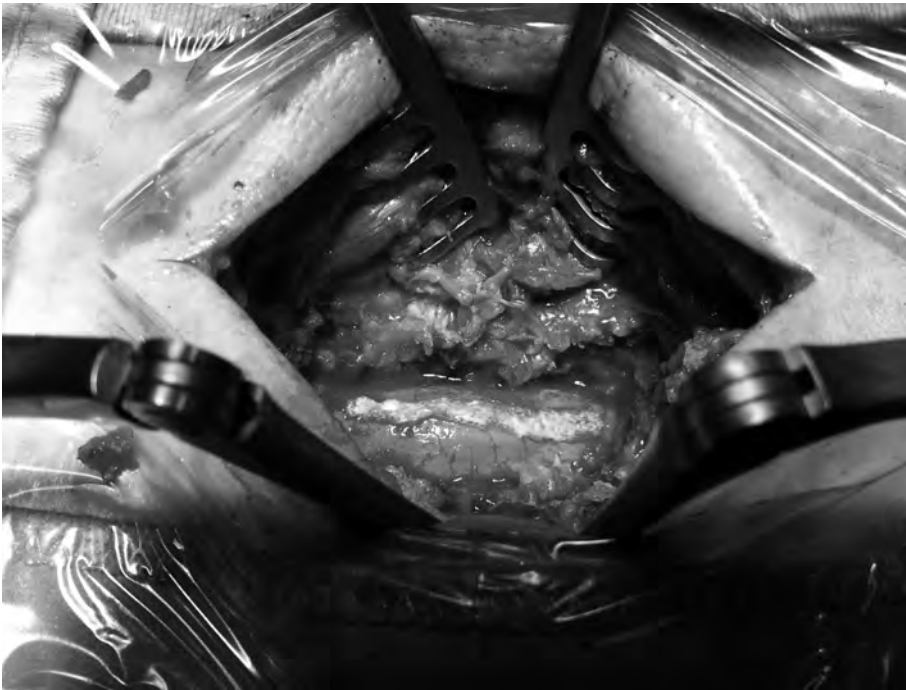


Fig. 1 - Use of TachoSil® in spinal surgery (meningioma at L3-L4 level). The material covers and reinforces the underlying dural suture.

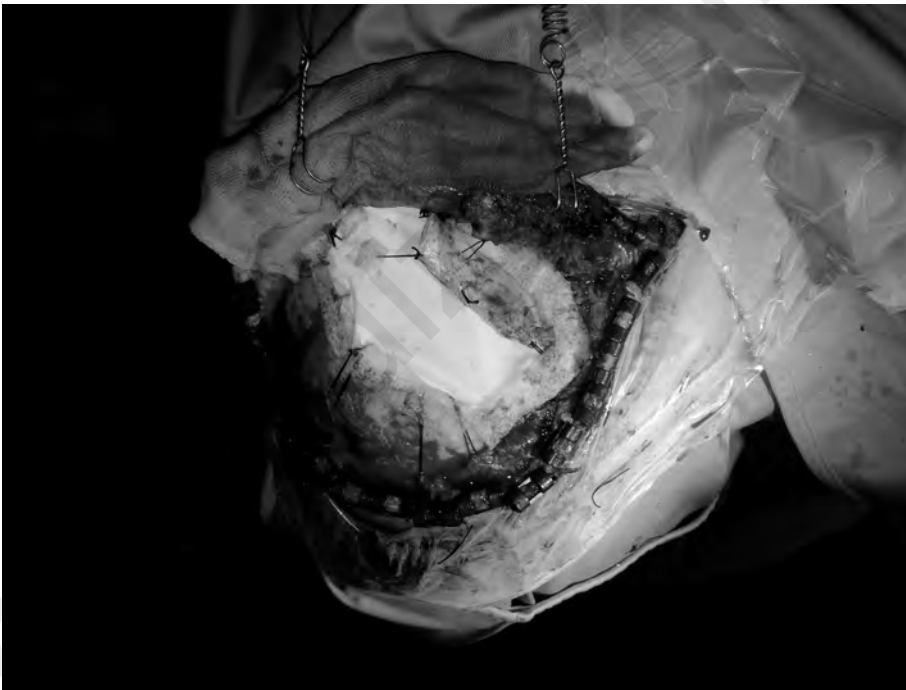


Fig. 2 - Use of TachoSil® in cranial surgery (decompressive craniotomy with dural patch [Gore® Preclude®]).

choSil® for spinal and cranial surgery are shown in Figure 1 and Figure 2, respectively. In both cases dura mater was cut and opened in order to remove intradural lesions and then finally closed.

The first case was a 50-year old woman who presented with sudden back pain and *claudicatio*. Spinal MRI re-

vealed the presence of a meningioma at L3-L4 level.

The second case was a 65-year old man who developed over a few months a progressive weakness in the lower limbs, with subsequent walking impairment. Brain MRI revealed ischemic features in the territory of the middle cerebral artery.

## Discussion

In our Neurosurgical Center we use TachoSil® to provide fibrinogen and thrombin locally at the site of the dural defects. Indeed, upon contact with fluid the clotting factors of TachoSil® dissolve and form a fibrin network, which glues the collagen sponge to the wound surface. Combining the clotting factors in a collagen patch provides a high concentration of clotting factors at the site where it is specifically needed. Our procedure showed that closing the dural defect with TachoSil® is a technically simple, reliable and safe method for patients. In our experience, TachoSil® was well tolerated and no adverse event was observed. Although the risk of severe immunologic reactions to bovine material is low, TachoSil® has gradually replaced all bovine material with material of human origin and has therefore eliminated the associated risks of bovine material (5). TachoSil®, either alone or as adjunct to standard techniques, enables cost savings from the perspective of healthcare providers (12). TachoSil® has a good satisfaction rate among surgeons and reduces both the operating time and the time spent by patients in intensive care units (5).

TachoSil® is a sterile ready-to-use absorbable patch for intraoperative topical application. It consists of an equine collagen patch coated with the fibrin glue components, human fibrinogen and human thrombin. It thus combines the assets of a pliable patch material with the haemostatic and adhesive properties of coagulation factors. The product is currently approved in Europe for supportive haemostatic treatment surgery (8) where standard techniques are insufficient. The predecessors of TachoSil® (Tachocomb® and Tachocomb H®) have proven to be efficacious haemostats and tissue sealants during several years of clinical use (8). TachoSil® is a valuable supplement to the traditional treatment and favors a shorter hospital stay (9). Moreover, it seems to be effective in reducing the rate of postoperative complications (10).

In selected patients, TachoSil® was more effective than

standard treatment of air leakage after pulmonary lobectomy (11). In some studies, TachoSil® patches were found to be significantly superior to conventional haemostatic fleece material for the control of bleeding in cardiovascular surgery. The efficacy and safety of TachoSil® have been demonstrated in digestive and hepatobiliary surgeries (liver resection), in pulmonary lobectomy, in sealing the tract after a percutaneous nephrolithotomy, kidney resection, open repair of abdominal aortic aneurysm, during splenectomy for oncohaematological conditions, for obstetric and gynecologic surgery, inguofemoral and axillary lymphadenectomy and in a case of corneal perforation. Only in a study on the prevention of postoperative pancreatic fistula with the routine use of TachoSil® patch no clinically significant benefit ensued (12).

The technique of covering the dural defects using TachoSil® that we normally use in our Neurosurgical Center to close the dura mater in presence of intraoperative CSF leakage is reliable as no post-operative CSF leakage has been observed when this technique was applied.

## Conclusion

Our experience shows that the use of standard dural suture repair followed by the application of TachoSil® has reduced the frequency of complications in both spinal and cranial surgery. Nonetheless, further studies with larger sample size are warranted to confirm the efficacy of TachoSil® patches for dural repair.

## Disclaimer

None of the Authors has any financial in TachoSil® or Nycomed.

This work is original and no parts of the manuscript is subject to plagiarism.

The Authors report no conflict of interest.

## References

1. Tafazal SI, Sell PJ. Incidental durotomy in lumbar spine surgery: incidence and management. *Eur Spine J.* 2005;14:287-290.
2. Tamasauskas A, Sinkunas K, Draf W, et al. Management of cerebrospinal fluid leak after surgical removal of pituitary adenomas. *Medicina (Kaunas)* 2008;44(4):302-7.
3. Jankowitz BT, Atteberry DS, Gerszten PC, et al. Effect of fibrin glue on the prevention of persistent cerebral spinal fluid leakage after incidental durotomy during lumbar spinal surgery. *Eur Spine J.* 2009;18(8):1169-1174.
4. Spontnitz WD. Fibrin sealant: past, present, future. A brief review. *World J Surg.* 2010;34:632-634.
5. Toro A, Mannino M, Reale G, Di Carlo I. TachoSil use in abdominal surgery: a review. *J Blood Med.* 2011;2:31-36.
6. Bajardi G, Pecoraro F, Mirabella D. Efficacy of TachoSil® patches in controlling Dacron suture-hole bleeding after abdominal aortic aneurysm open repair. *J Cardiothorac Surg.* 2009;4:60.
7. European Medicine Agency TachoSil H-C-505 European Public Assessment Report <http://www.emea.europa.eu/humandocs/Humans/EPAR/tachosil/tachosil.html> Revision9 - published 25/06/09.
8. Siemer S, Lahme S, Altziebler S, et al. Efficacy and safety of TachoSil® as haemostatic treatment versus standard suturing in kidney tumour resection: a randomised prospective study. *Eur Urol.* 2007;52(4):156-63.
9. Cormio L, Perrone A, Fino GD, et al. TachoSil® sealed tubeless percutaneous nephrolithotomy to reduce urine leakage and bleed

- ding: outcome of a randomized controlled study. *J Urol.* 2012;May 15 Epub ahead of print.
10. Buda A, Fruscio R, Pirovano C, Signorelli M, Betti M, Milani R. The use of TachoSil for the prevention of postoperative complications after groin dissection in cases of gynecologic malignancy. *Int J Gynaecol Obstet.* 2012;117(3):217-9, epub Mar 15, 2012.
  11. Marta GM, Facciolo F, Ladegaard L, et al. Efficacy and safety of TachoSil® versus standard treatment of air leakage after pulmonary lobectomy. *Eur J Cardiothorac Surg.* 2010;44(4):302-7.
  12. Marangos P, Rosok BI, Kazaryan AM, Rosselland AR, Edwin B. Effect of TachoSil patch in prevention of postoperative pancreatic fistula. *J Gastrointest Surg.* 2011; Sep, 15(9):1625-9.
-

---

*Selection of papers from the  
“Best Communication Award”*

*at the*

*XXV National Congress  
of the*

*“Società Polispecialistica Italiana  
dei Giovani Chirurghi”*

Bari, 13-15 June 2013

---