

HOSTED BY



Contents lists available at ScienceDirect

Journal of Acute Disease

journal homepage: [www.jadweb.org](http://www.jadweb.org)

Document heading doi: 10.1016/S2221-6189(14)60089-5

## Is the early percutaneous spine total care to treat the polytrauma patient a good way?

Gabriele Falzarano<sup>1</sup>, Antonio Medici<sup>1</sup>, Giuseppe Pica<sup>1</sup>, Predrag Grubor<sup>2</sup>, Milan Grubor<sup>2</sup>, Francesco Vitaliano Muzil<sup>3</sup>, Mirza Biscevic<sup>4</sup>, Arianna Falzarano<sup>5</sup>, Luigi Meccariello<sup>6\*</sup>

<sup>1</sup>*U.O.C. Orthopedics and Traumatology, AO G.Rummo, Benevento, Italy*

<sup>2</sup>*Orthopaedics and Traumatology Clinic Banja Luka, Republic of Srpska, Bosnia and Herzegovina*

<sup>3</sup>*Department of Medical and Surgical Sciences and Neuroscience, Section of Neurosurgery, University of Siena, University Hospital "Santa Maria alle Scotte", Siena, Italy*

<sup>4</sup>*Orthopaedics and Traumatology Clinic Sarajevo, Sarajevo, Bosnia and Herzegovina*

<sup>5</sup>*Faculty of Medicine, Vasile Goldiș Western University of Arad, Arad, Romania*

<sup>6</sup>*Department of Medical and Surgical Sciences and Neuroscience, Section of Orthopedics and Traumatology, University of Siena, University Hospital "Santa Maria alle Scotte", Siena, Italy*

### ARTICLE INFO

#### Article history:

Received in 20 Jan 2015

Received in revised form 21 Jan 2015

Accepted 23 Jan 2015

Available online 26 Jan 2015

#### Keywords:

Spine fractures

Polytrauma

Early total care

Floating knee

Damage control

### ABSTRACT

The "ideal" timing and modality of fracture fixation for unstable thoracolumbar spine fractures in multiply injured patients remains controversial. The concept of "damage control orthopedics" is expressed. We presented a case report of a 27 years' old male who sustained a multilevel spine fractures associated a floating knee (Fraser's Type A), ulna fracture and carpal scaphoid fracture in July 2014 after car accident (very high energy trauma). All these fractures were treated in early total care. We reported a case control to discuss about the early spinal total care associated at orthopedic total care in patients with multiple trauma.

## 1. Introduction

Decision making and communication are vital factors for successful surgery; good surgeons make wise decisions. Before recommending surgical treatment, a thorough assessment of the patient must be undertaken to understand the full extent of the injury, anticipate

and prevent postoperative complications, and determine the potential for recovery. In our setting, the concept of damage control surgery entails a three-phase approach to the surgical management of the trauma patient. In the initial phase, the prime aim is to establish rapid control of hemorrhage and to identify and control major injuries<sup>[1]</sup>. The next step is to stabilize major fracture(s), to reduce dislocated joint(s) and to decontaminate open wound(s) with appropriate surgical methods, which may or may not be definitive<sup>[1]</sup>. Once normal physiology has been restored, a final phase entails definitive injury repairs<sup>[1]</sup>.

The "ideal" timing and modality of fracture fixation for unstable thoracolumbar spine fractures in multiply

\*Corresponding author: Luigi Meccariello, MD, Department of Medical and Surgical Sciences, and Neuroscience, Section of Orthopedics and Traumatology, University of Siena, University Hospital "Santa Maria alle Scotte", Viale Bracci 1, 53100 Siena, Italy.

E-mail: [dlordmec@gmail.com](mailto:dlordmec@gmail.com)

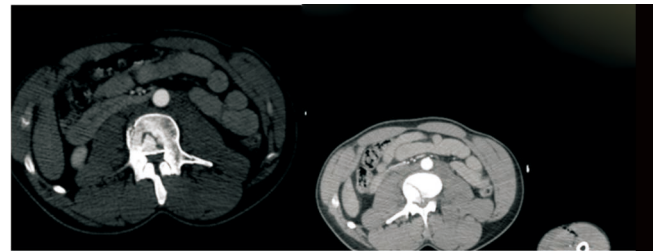
Tel: +39 329 9419574

injured patients remains controversial. The concept of “damage control orthopedics”, which has evolved globally in the past decade, provides a safe guidance for temporary external fixation of long bone or pelvic fractures in multisystem trauma[2]. In contrast, “damage control” concepts for unstable spine injuries have not been widely implemented, and the scarce literature in the field remains largely anecdotal[2]. The current practice standards are reflected by two distinct positions, either immediate “early total care” or delayed spine fixation after recovery from associated injuries. Both concepts have inherent risks which may contribute to adverse outcome[2].

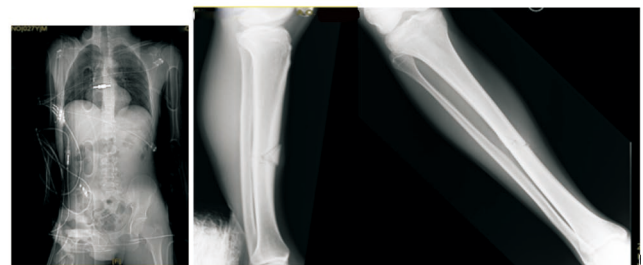
## 2. Case presentation

We presented a case report of a 27 years’ old male with a history of drug addiction and alcoholism, after car accident in July 2014 (very high energy trauma). He sustained a multilevel thoraco–lumbar spinal associated a right floating knee (Fraser’s Type A), left ulnar shaft fracture and left carpal scaphoid fracture. At admission in emergency room, the Glasgow Coma Score was 13 and Injury Severity Score was 22. The vertebral body spine fractures were at L1 (Type A3 according Magerl’s classification) and L2 (Type A2 according Magerl’s classification) (Figure 1). The right floating knee (Fraser’s Type A), femoral shaft and tibial shaft in ipsilateral leg were shown in Figure 2. The fractures on left arm, not dominance were ulnar shaft fracture and carpal scaphoid fracture (Figure 3). All these fractures were treated in early total care. Spine fractures were treated by percutaneous short posterior stabilization with undersize pedicle screws in fractured vertebra’s body (Figure 4). The right floating knee (Fraser’s Type A) was treated by femoral intramedullary nailing and tibial intramedullary nailing (Figure 5). The ulnar shaft fracture was treated by open reduction internal fixation with plate and wires (Figure 6). The carpal scaphoid fracture was treated by percutaneous screw. A plaster cast arm–forearm–metacarpal was applied at his left upper limb. The surgical time to treat all fractures was 327 min, 423 min of the anesthetic. The patient after surgery was hospitalized in intensive care for one day. It has not been subjected to blood transfusions, but made the common antibiotic prophylaxis and enoxaparin 4000 IU 1 fl/day under the

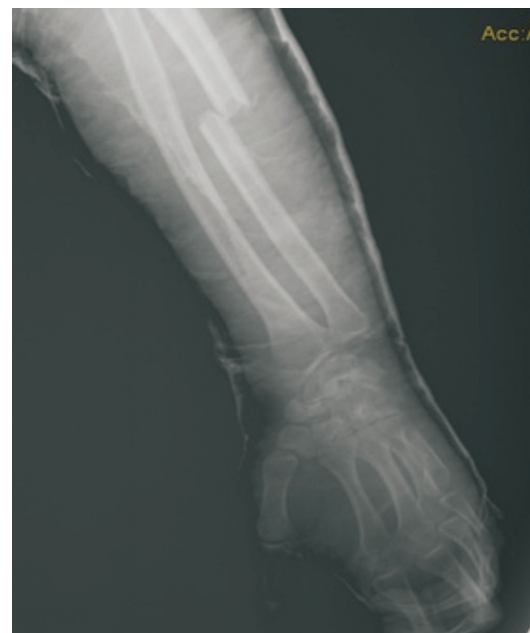skin. He hospitalized in the physiotherapy department for the first day and was verticalized in the second post-operative day. The patient was not subjected to any blood transfusion during hospitalization and lost only 3 points hemoglobin. The follow-up programs consisted of radiographic control of injures segments, VAS (Figure 7), Oswestry low back pain disability questionnaire (OLBPSQ) used to quantify disability for low back pain (Figure 8) and The Short Form (36) Health Survey(SF-36) at 1 month, 3 months and 6 months (Figure 9). He had no complication during the follow up.



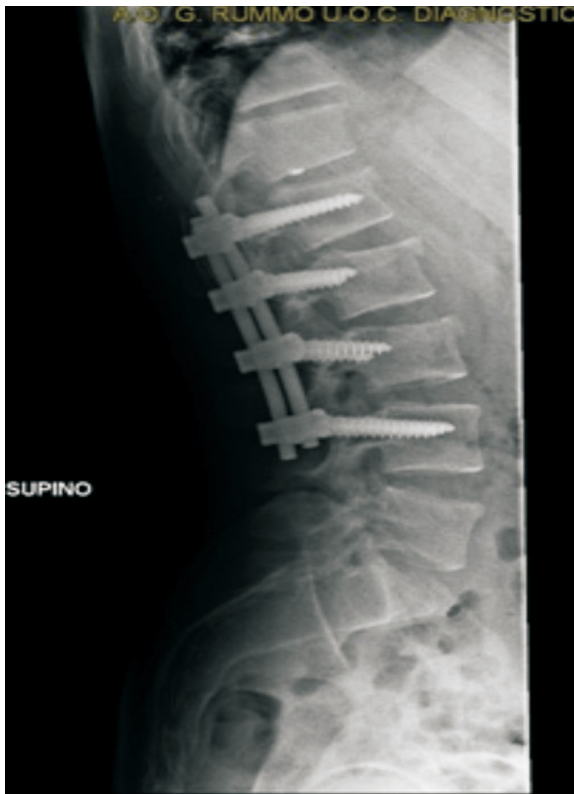**Figure 1.** CT showed the instability of the fractured in L1 instead of the fracture stability of L2.



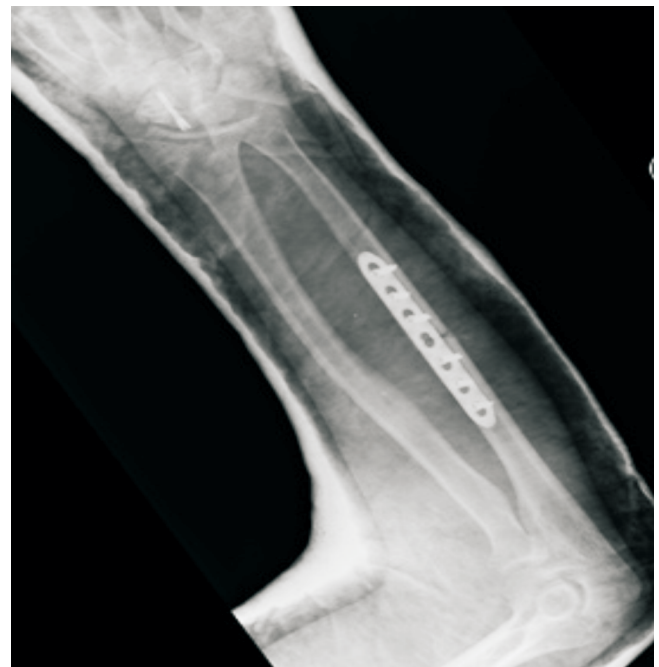**Figure 2.** The CT’s scout showed the femoral shaft fracture and XR showed the tibial shaft fracture.



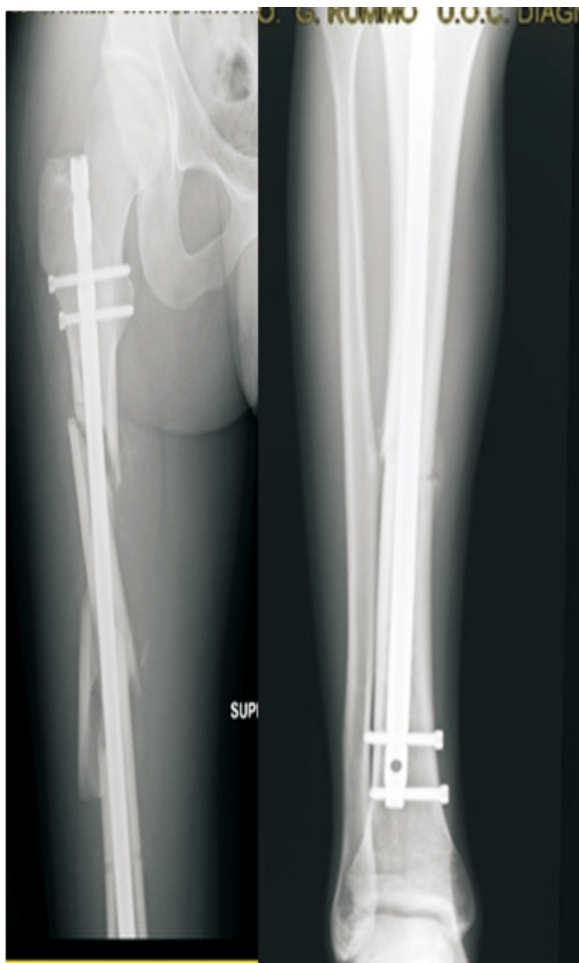
**Figure 3.** The left ulnar shaft fracture and left carpal scaphoid.



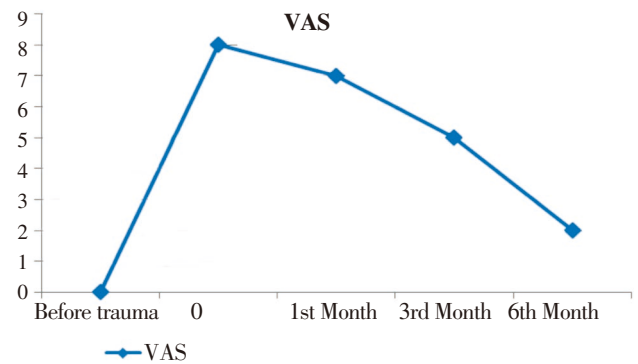
**Figure 4.** Treatment of spine fractures by percutaneous short posterior stabilization with undersize peduncular screws in fractured vertebral body.



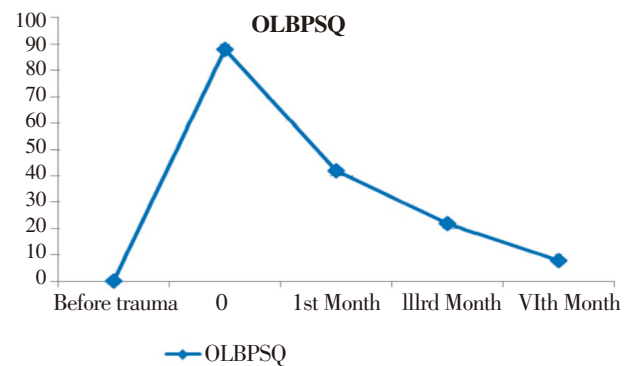
**Figure 6.** Ulnar shaft fracture's treatment by ORIF with plate and wires; single screw for the treatment of carpal scaphoid fracture.



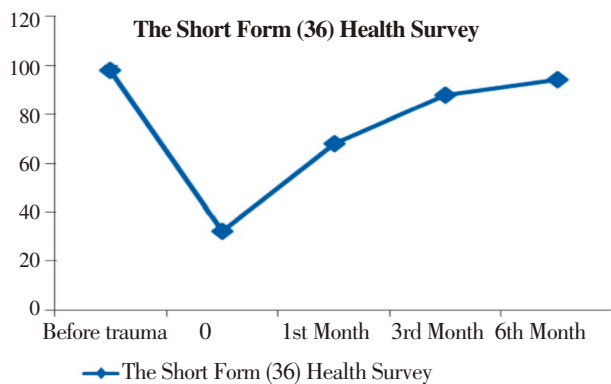
**Figure 5.** The right floating knee (Fraser's Type A) was treated by femoral intramedullary nailing and tibial intramedullary nailing.



**Figure 7.** Trend of back pain during the 6 months of follow up measured with VAS.



**Figure 8.** Trend of back quality life during the 6 months of follow up measured with OLBPSQ.



**Figure 9.** Trend of quality of life during the 6 months of follow up measured with SF-36.

### 3. Discussion

Polytrauma patients have a severely deranged immune response, characterized by an early excessive activation of innate immunity (hyperinflammation), followed by a delayed attenuation of adaptive immunity with decreased T-cell function (immunosuppression) and enhanced susceptibility to infection, sepsis, and multiple organ failure<sup>[3,4]</sup>. In addition, about a third of all multiply injured patients have severe disturbances of their clotting system on arrival to the emergency department, as determined by the presence of post injury coagulopathy<sup>[5,6]</sup>. Early total care is beneficial for some patients with polytrauma. This involves definitive surgical stabilization of all long-bone fractures during the early phase of treatment. This may reduce pulmonary complications and allow earlier rehabilitation of the patient<sup>[7–10]</sup>.

Early total care is suitable for patients with multiple fractures but without major chest or visceral injury. Patients must be hemodynamically stable with normal blood gases, clotting, and temperature.

The concept of “spine damage control” will provide a safe and effective treatment modality for unstable thoraco-lumbar fractures in multiply injured patients, associated with less complications and improved outcomes compared to conventional treatment strategies. In 2005, Stahel *et al.* and Heyde *et al.* have defined “spine damage control” as a staged procedure of immediate posterior fracture reduction and instrumentation within 24 h (“Day 1 surgery”)<sup>[11,12]</sup>. This concept differs from the more common elective strategy of a staged spine fixation by initial posterior fixation and delayed anterior completion by its timeliness (posterior fixation within 24 h) and expanded applicability to all unstable thoraco-lumbar fractures, including pure anterior column burst fractures (AO/OTA type A3)<sup>[2]</sup>.

Decision-making regarding non-operative versus operative treatment of patients with thoraco-lumbar Magerl’s Type A fractures in the absence of neurologic deficits is controversial. Lack of evidence-based practice may result in patients being treated inappropriately and being exposed to unnecessary adverse consequences. With respect to the patients’ status after treatment of a spinal fracture, literature mostly focuses on radiological aspects<sup>[13]</sup>. The study of Post *et al.* was developed to gain insight into the functional outcome in patients treated non-operatively for a thoraco-lumbar spinal fracture<sup>[13]</sup>. What is it really advantageous for a good alignment of the spine in young adult? In 2014, Medici, Meccariello and Falzarano reported 39 adult patients with thoraco-lumbar spinal fractures according to Magerl’s A1 and A2; 24 patients were treated with 3 points orthopedic corset and 15 patients were treated with percutaneous posterior stabilization without augmentation<sup>[14]</sup>. Although the data are preliminary and based on data available in the literature, we can say that the percutaneous posterior stabilization of thoraco-lumbar fractures lumbar in Magerl’s A1 and A2 in the adults is the ideal method for a good and functional alignment of the spine<sup>[14]</sup>. The advantages of percutaneous posterior stabilization were faster than open posterior stabilization, reduced the back pain, improved the quality life, small blood loss average 3 gauze (range 1–6); the exposure of surgeons to ionizing radiation was less than 1 millisievert for each stabilization; the reduction of hospitalization days and reduction of the miscellaneous complications<sup>[14]</sup>. Fracture level screw combination provided better intraoperative correction and maintenance in the treatment of unstable thoraco-lumbar burst fractures, which was more prevalent in short-segment fixation group. Reinforcement with fracture level screw combination can help to provide better kyphosis correction and offers immediate spinal stability in patients with thoraco-lumbar burst fracture<sup>[14,15]</sup>. An interestingly and encompassing prospective multicenter study published in the German literature by the spine working group of the German Trauma Society (“Arbeitsgemeinschaft Wirbelsaeule der Deutschen Gesellschaft fuer Unfallchirurgie”) revealed that 65.7% of all polytrauma patients with operative thoraco-lumbar fractures ( $n=682$ ) are currently treated by exclusive posterior fixation in German and Austrian level 1 trauma centers<sup>[16]</sup>. The authors showed that posterior instrumentation was associated with a decreased complication rate of 4.7%, compared to 10.8% in the primary anterior fusion group<sup>[16]</sup>. Impressively,

only 0.4% of all patients with posterior instrumentation showed a secondary neurological deterioration, implying that the “spine damage control” procedure is safe from a neurological perspective<sup>[6]</sup>.

#### 4. Conclusion

The early spinal total care is still a main topic of spinal surgery and the management of patients with multiple trauma. In selected patients with multiple trauma, percutaneous posterior stabilization of the thoracolumbar spine remains a viable choice for the early spinal total care.

#### Conflict of interest statement

The authors report no conflict of interest.

#### Acknowledgments

Patient was treated according to the Helsinki Declaration’s ethical standards, and he was asked if he could read and understand the patient information sheet and sign the informed consent form. None of the authors had received direct or indirect compensation for the realization of this paper.

#### References

- [1] Kossman T, Trease L, Freedman I, Malham G. Damage control surgery for spine trauma. *Injury* 2004; **35**(7): 661–670.
- [2] Stahel PF, Flierl MA, Moore EE, Smith WR, Beauchamp KM, Dwyer A. Advocating “spine damage control” as a safe and effective treatment modality for unstable thoracolumbarfractures in polytrauma patients: a hypothesis. *J Trauma Manag Outcomes* 2009; **3**: 6.
- [3] Pape HC, Rixen D, Morley J, Husebye EE, Mueller M, Dumont C, et al. Impact of the method of initial stabilization for femoral shaft fractures in patients with multiple injuries at risk for complications (borderline patients). *Ann Surg* 2007; **246**: 491–499.
- [4] Morshed S, Miclau T 3rd, Bembom O, Cohen M, Knudson MM, Colford JM Jr. Delayed internal fixation of femoral shaft fracture reduces mortality among patients with multisystem trauma. *J Bone Joint Surg (Am)* 2009; **91**: 3–13.
- [5] MacLeod JB, Lynn M, McKenney MG, Cohn SM, Murtha M. Early coagulopathy predicts mortality in trauma. *J Trauma* 2003; **55**: 39–44.
- [6] Maegele M, Lefering R, Yucel N, Tjardes T, Rixen D, Paffrath T, et al. Early coagulopathy in multiple injury: an analysis from the German Trauma Registry on 8724 patients. *Injury* 2007; **38**: 298–304.
- [7] Pape HC, Grimme K, Van Griensven M, Sott AH, Giannoudis P, Morley J, et al. Impact of intramedullary instrumentation versus damage control for femoral fractures on immunoinflammatory parameters: prospective randomized analysis by the EPOFF Study Group. *J Trauma* 2003; **55**(1): 7–13.
- [8] Grubor P, Grubor M, Falzarano G, Medici A, Meccariello L. Importance of eternal fixation in primary treatment of war wounds. *Acta Facultatis Medicae Naissensis* 2011; **28**: 225–233.
- [9] Grubor P, Falzarano G, Medici A, Grubor M, Franzese F, Errico G, et al. The damage control orthopedics and external fixation in traffic accident after 20 years in the Bosnian War: our experience and a review of the literature. *SYLWANJ* 2014; **158**(6): 90–109.
- [10] Meccariello L, Medici A, Fazarano G, Roberto VL, Errico G, Franzese R, et al. The intramedullary nailing in femoral and tibial open fractures: A Review of Literature. *Canadian Open Orthopaedics Traumatol J* 2014; **1**: 8–12.
- [11] Stahel PF, Heyde CE, Wyrwich W, Ertel W. [Current concepts of polytrauma management: from ATLS to “damage control”]. *Orthopade* 2005; **34**: 823–836. German.
- [12] Heyde CE, Ertel W, Kayser R. ]Management of spine injuries in polytraumatized patients]. *Orthopade* 2005; **34**: 889–905. German.
- [13] Post RB, Keizer HJ, Leferink VJ, van der Sluis CK. Functional outcome 5 years after non-operative treatment of type A spinal fractures. *Eur Spine J* 2006; **15**(4): 472–478.
- [14] Medici A, Meccariello L, Falzarano G. Non-operative vs. percutaneous stabilization in Magerl’s A1 or A2 thoracolumbar spine fracture in adults: is it really advantageous for a good alignment of the spine? Preliminary data from a prospective study. *Eur Spine J* 2014; **23**: 677–683.
- [15] Guven O, Kocaoglu B, Bezer M, Aydin N, Nalbantoglu U. The use of screw at the fracture level in the treatment of thoracolumbar burst fractures. *J Spinal Disord Tech* 2009; **22**(6): 417–421.
- [16] Knop C, Blauth M, Bühren V, Hax PM, Kinzl L, Mutschler W, et al. Operative treatment of thoracolumbar fractures. Part II: Operation and radiology. *Unfallchirurg* 2000; **103**: 1032–1047.