

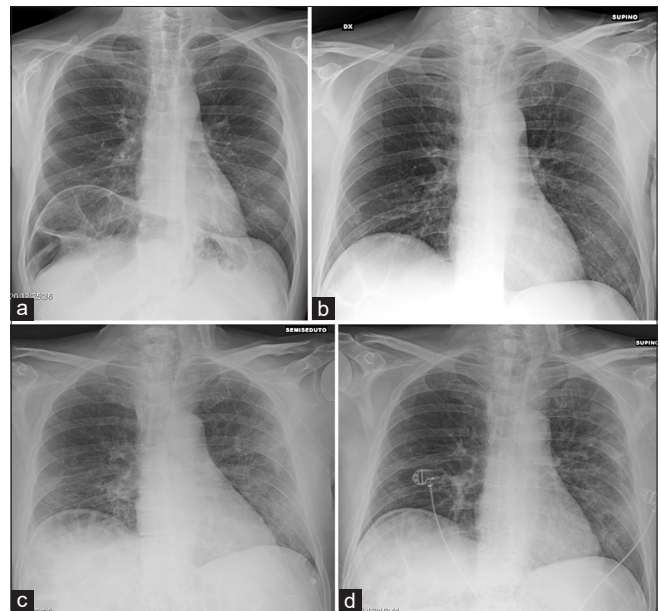
## Novel coronavirus (COVID-19) pneumonia: Portable chest X-ray or computed tomography? An Italian perspective

As the new COVID-19 pandemic spreads, radiologists are at the forefront playing an important role in the initial positive/differential diagnosis, the assessment of disease severity, and in searching for progression to acute respiratory syndrome and possible complications.<sup>[1]</sup> Chest computed tomography (CT) has an unquestionable role in this setting, with a better sensitivity and specificity than chest X-Ray (CXR) and its role is growing, especially in the early detection with a low rate of missed diagnoses (3.9%), since real-time reverse transcription-polymerase chain reaction (rRT-PCR) may produce false-negative results.<sup>[2]</sup> Furthermore, it allows to follow the temporal changes of lung abnormalities throughout specific pattern, indicating the progression and recovery of the illness.<sup>[3-5]</sup> At the time of this writing, the search string “chest CT AND COVID-19” produces 351 articles on PubMed, whereas 235 articles appear if we search for “chest X-ray AND COVID-19,” and among these, only 39 articles report CXR features (several of these as case reports). CT is definitely the technique of excellence to be used in case of complicated pneumonia and for demonstrating vascular involvement in these patients.<sup>[6]</sup> However, other issues should be considered in the radiological management of known and suspected COVID-19 patients such as infection control issues related to patient transport to CT suites, infection containment in medical staffs (radiographers, radiologists, and nurses), sanitization of imaging equipment and rooms, and sparing of personal protective equipment. In this scenario, also considering that not all COVID-19 patients experience a complicated lung disease, chest CT could be used “sparingly” and reserved for hospitalized patients with specific clinical indications, as already suggested by ACR recommendations, or in suspected COVID-19 patients requiring both chest imaging and time-based emergency care by priority CT.<sup>[7,8]</sup> This case series aims to share in brief an Italian perspective on CXR findings of COVID-19 pneumonia patients from diagnosis until patient recovery.

In our case series, of 76 COVID-19 patients (male 48, age range 22–97, mean age 66; 8 died and 59 discharged at the time we are writing) with rRT-PCR confirmation admitted to our University Hospital from February 24 to May 30, 2020 (hospitalization time: median 22 days, range 3–57), we performed 448 baseline and serial portable CXRs (median for patient 6, range 1–29) and 16 chest CT in 10 patients with complicated illness (range 1–6 per patient). According to the onset of symptoms, four stages of pneumonia were identified (early Stage = 0–4 days, progressive Stage = 5–8 days, peak Stage = 9–13 days,

and recovering stage  $\geq 14$  days) and distribution of CXR findings were evaluated.<sup>[4,9]</sup> We found that “hazy densities,” which correspond to ground-glass opacities (GGOs) on CT, were mostly present in early stage (92%), whereas consolidation and parenchymal band in peak (83%) and recovering stage (96%), respectively [Table 1], whereas regarding the topographical distribution of lesions, peripheral hazy densities, or air space opacities, lower lobe and bilateral involvement were the most common findings (78.4%, 75.2%, and 84%, respectively). Lung abnormalities showed the greatest severity approximately 12 days from the onset (peak Stage)<sup>[11]</sup> [Figure 1a-d]. In one patient, the only CXRs finding, confirmed by CT, was unilateral pleural effusion, resulted positive for COVID-19 infection at rRT-PCR examination.

Even if chest CT allows detecting subtle diffuse GGOs that are variable identified by CXRs for several reasons such as GGO’s density, technical factors (including imaging quality, acquisition parameters, and patient’s positioning),



**Figure 1:** (a-d) baseline (Stage 1) and serial (Stages 2–4) chest X-rays of a 68-year-old COVID-19 patient. Stage 1 chest X-ray (a) shows a subtle ground-glass opacities in both lower lung zone (left > right). In Stage 2 chest X-ray (b) the ground-glass opacities are more diffuse in the left lung, mixed to septal thickening in the lower zone (crazy paving appearance). Stage 3 chest X-ray (c) shows peripheral consolidation in the middle and lower zone on the left and in the lower zone on the right, which resolve in Stage 4 chest X-ray (d) where smaller consolidation and parenchymal band take place

**Table 1: Chest X-ray findings according to the stage of illness in COVID-19 pneumonia patients**

Stage of illness from the onset	Number <sup>o</sup> of patients	Hazy opacities/GGO (%)	Mixed pattern (%)	Consolidation (%)	Parenchymal band (%)
Stage 1	14	13 (92)	1 (8)	0	0
Stage 2	41	0	38 (92)	3 (8)	0
Stage 3	53	2 (4)	2 (4)	44 (83)	5 (9)
Stage 4	51	0	1 (2)	1 (2)	49 (96)

Stage 1=Early Stage (0–4 days); Stage 2=Progressive Stage (5–8 days); Stage 3=Peak Stage (9–13 days); Stage 4=Recovering Stage (>14 days).  
CXR: Chest X-ray, GGOs: Ground-glass opacities, Mixed pattern: GGOs and consolidations

and radiologist's experience, we agree with Jacobi *et al.* that COVID-19 lung involvement, including both lesion type and distribution, can be identified on conventional CXRs as well as on chest CT.<sup>[10,11]</sup> Nevertheless, CXRs have numerous advantages such as low radiation exposure and costs, constant availability and mobility, especially for intensive care unit, and greater ease in the equipment sanitization process. In our clinical experience, we were able to accurately manage COVID-19 pneumonia, integrating clinical and functional data with the time course of lung changes obtained by CXRs, limiting chest CT to specific clinical conditions. In conclusion, even if chest CT remains “the Empress” in imaging COVID-19 pneumonia, accurately depicting both parenchymal and vascular injury, CXRs may represent “the Queen,” allowing a careful treatment and above all, a bedside management of noncomplicated illness.

**Maria Antonietta Mazzei<sup>1</sup>, Susanna Guerrini<sup>2</sup>, Matteo Zanoni<sup>1</sup>, Federico Franchi<sup>3</sup>, Serafina Valente<sup>4</sup>, Maria Grazia Cusi<sup>5</sup>, Bruno Frediani<sup>6</sup>, Luca Volterrani<sup>1</sup>, Siena COVID-Unit<sup>7</sup>**

<sup>1</sup>Department of Medical, Surgical and Neuro Sciences and of Radiological Sciences, Unit of Diagnostic Imaging, University of Siena, Azienda Ospedaliero-Universitaria Senese, Siena, Italy, <sup>2</sup>Department of Radiological Sciences, Unit of Diagnostic Imaging, University of Siena, Azienda Ospedaliero-Universitaria Senese, Siena, Italy, <sup>3</sup>Department of Medical, Surgical and Neuro Sciences, Anesthesia and Intensive Care Unit, University of Siena, Azienda Ospedaliero-Universitaria Senese, Siena, Italy, <sup>4</sup>Department of Cardio-Thoraco-Vascular, Cardiac Intensive Care Unit, University of Siena, Azienda Ospedaliero-Universitaria Senese, Siena, Italy, <sup>5</sup>Department of Medical Biotechnologies, Microbiology Unit, University of Siena, Azienda Ospedaliero-Universitaria Senese, Siena, Italy, <sup>6</sup>Department of Medical, Surgical and Neuro Sciences, Unit of Rheumatology, University of Siena, Azienda Ospedaliero-Universitaria Senese, Siena, Italy, <sup>7</sup>University of Siena, Azienda Ospedaliero-Universitaria Senese, Siena, Italy  
E-mail: guerrinisus@gmail.com

Submitted: 03-Jun-2020 Revised: 07-Jun-2020  
Accepted: 07-Jun-2020 Published: 16-Sep-2020

## REFERENCES

- Kim H. Outbreak of novel coronavirus (COVID-19): What is the role of radiologists? *Eur Radiol* 2020;30:3266-7.

- Ai T, Yang Z, Hou H, Zhan C, Chen C, Lv W, et al. Correlation of Chest CT and RT-PCR Testing in Coronavirus Disease 2019 (COVID-19) in China: A Report of 1014 Cases. *Radiology* 2020; 200642. Advance online publication. <https://doi.org/10.1148/radiol.202000642>
- Li Y, Xia L. Coronavirus disease 2019 (COVID-19): Role of chest CT in diagnosis and management. *AJR Am J Roentgenol* 2020;214:1280-6.
- Pan F, Ye T, Sun P, Gui S, Liang B, Li L, et al. Time course of lung changes at chest CT during recovery from coronavirus disease 2019 (COVID-19). *Radiology* 2020;295:715-21.
- Wang Y, Dong C, Hu Y, Li C, Ren Q, Zhang X, et al. Temporal Changes of CT Findings in 90 Patients with COVID-19 Pneumonia: A Longitudinal Study. *Radiology* 2020; 200843. Advance online publication. <https://doi.org/10.1148/radiol.202000843>.
- Grillet F, Behr J, Calame P, Aubry S, Delabrousse E. Acute Pulmonary Embolism Associated with COVID-19 Pneumonia Detected by Pulmonary CT Angiography. *Radiology* 2020; 201544. Advance online publication. <https://doi.org/10.1148/radiol.202001544>.
- American College of Radiology, COVID-19 Radiology-Specific Resources. Available from: <http://www.acr.org/Clinical-Resources/COVID-19-Radiology-Resources>. [Last updated 2020 Mar 24; Last accessed on 2020 Mar 24].
- Cerese A, Guazzi G, Mazzei MA. Letter by Cerese et al. Regarding Article, “Temporary Emergency Guidance to US Stroke Centers During the COVID-19 Pandemic”. *Stroke* 2020; 51, e139–e140. <https://doi.org/10.1161/STROKEAHA.120.030147>
- Wong H, Lam H, Fong AH, Leung ST, Chin TW, Lo C, et al. Frequency and Distribution of Chest Radiographic Findings in COVID-19 Positive Patients. *Radiology* 2019; 201160. Advance online publication. <https://doi.org/10.1148/radiol.202001160>.
- Jacobi A, Chung M, Bernheim A, Eber C. Portable chest X-ray in coronavirus disease-19 (COVID-19): A pictorial review. *Clin Imaging* 2020;64:35-42.
- Hansell DM, Bankier AA, MacMahon H, McLoud TC, Müller NL, Remy J. Fleischner Society: Glossary of terms for thoracic imaging. *Radiology* 2008;246:697-722.

This is an open access journal, and articles are distributed under the terms of the Creative Commons Attribution-NonCommercial-ShareAlike 4.0 License, which allows others to remix, tweak, and build upon the work non-commercially, as long as appropriate credit is given and the new creations are licensed under the identical terms.

Access this article online	
<b>Quick Response Code:</b> 	<b>Website:</b> <a href="http://www.lungindia.com">www.lungindia.com</a>
	<b>DOI:</b> <a href="https://doi.org/10.4103/lungindia.lungindia_453_20">10.4103/lungindia.lungindia_453_20</a>

**How to cite this article:** Mazzei MA, Guerrini S, Zanoni M, Franchi F, Valente S, Cusi MG, et al. Novel coronavirus (COVID-19) pneumonia: Portable chest X-ray or computed tomography? An Italian perspective. *Lung India* 2021;38:S72-3.