



Contents lists available at ScienceDirect

Indian Pacing and Electrophysiology Journal

journal homepage: www.elsevier.com/locate/IPEJ

Case Report

The interventricular conduction delays guide best cardiac resynchronization therapy: A tailored-patient approach to perform a CRT through Conduction System Pacing

Amato Santoro^{a,*}, Maria Barilli^b, Carmine Marallo^b, Claudia Baiocchi^a^a Division of Cardiology, Azienda Ospedaliera Universitaria Senese, Siena, Italy^b Division of Cardiology, University of Siena, Siena, Italy

ARTICLE INFO

Keywords:

Cardiac resynchronization therapy
His bundle pacing
Left bundle branch pacing
Interventricular delays
Conduction system pacing

ABSTRACT

Evaluation of conduction intervals to predict success of resynchronization in biventricular pacing (BiVP) or Conduction System Pacing (CSP) is not spread in clinical practice. A right ventricle-to-left ventricle intrinsic conduction interval (RVs–LVs) > 70 ms or prolonged RVpaced – LVs (RVp–LVs) interval can predict Cardiac Resynchronization Therapy (CRT) response. This paper describes a case of cardiac resynchronization guided by spontaneous and paced interventricular conduction delays (IVCD) obtained in BiVP that led to changing intra-operative approach. A strategy for cardiac resynchronization based on the CSP/BiVP approach according to the IVCD could represent a viable and reliable solution to obtain a narrow paced QRS and to improve the CRT response.

1. Introduction

All heart failure patients with severely reduced ejection fraction (LVEF < 35%), NYHA class II–IV in sinus rhythm and Left Bundle Branch Block (LBBB) and QRS duration > 130 msec, benefit of CRT [1]. Despite the benefits of CRT, the non-responder rate represents a relevant clinical problem. A right ventricle-to-left ventricle intrinsic conduction (RVs – LVs) interval > 70 ms or prolonged RVpaced – LVs (RVp–LVs) interval can predict a better CRT response [2]. In case of sub-optimal RVs–LVs or RVp – LVs intervals recorded during the LV lead positioning, often results in a wide QRS. Conduction system pacing (CSP) has been demonstrated to be feasible and effective for a more physiological pacing on the natural conduction system. BiVP remains the first-line therapy for CRT, but, as suggested by European Guidelines, CSP should be considered in case of failed LV lead positioning [1] or in case of low value of IVCD [3]. Despite its physiological pacing, the HBP approach presented some drawbacks. Left Bundle Branch Pacing (LBBP) overcome many limitations of HBP [4]. It is an alternative method to perform a CSP. This makes LBBP a promising field, although long term data on safety are still not available [5].

2. Clinical case

A 68-year-old male patient affected by heart failure with reduced ejection fraction (HFrEF), caused by dilated cardiomyopathy with a biological prosthesis aortic valve, NYHA III functional class, presented to Emergency Department of our hospital with symptoms of heart failure. Echocardiography at admission reported a LVEF of 18% with biventricular dysfunction and at electrocardiogram (ECG) evidence of LBBB with a QRS duration of 164 ms (Fig. 1 a). After clinical stabilization, he was eligible for Biventricular-ICD implantation, according to ESC pacing guidelines. He received optimal medical therapy for heart failure since 4 months.

3. Description of the procedure

After positioning of a RV defibrillator lead, coronary sinus (CS) was cannulated using a quadripolar Josephson curve diagnostic catheter. The delivery was advanced in CS over the quadripolar catheter, then the CS venography was performed: it showed a lateral-anterior CS tributary vein that has been successfully cannulated with a quadripolar lead to obtain BiVP. The recorded RVs – LVs EGM interval was 80 msec and RVp–LVs was 100 ms. A BiVP ECG showed a QRS duration of 192 ms (Fig. 1

Peer review under responsibility of Indian Heart Rhythm Society.

* Corresponding author. Cardiologia Clinico-Chirurgica, Azienda Ospedaliera Universitaria Senese, viale Bracci 1, Siena. 53100 Italy.

E-mail address: amato.santoro@gmail.com (A. Santoro).<https://doi.org/10.1016/j.ipej.2023.11.004>

Received 23 May 2023; Received in revised form 14 October 2023; Accepted 14 November 2023

Available online 17 November 2023

0972-6292/© 2023 Indian Heart Rhythm Society. Published by Elsevier B.V. This is an open access article under the CC BY-NC-ND license (<http://creativecommons.org/licenses/by-nc-nd/4.0/>).

b). The leads position are showed in Fig. 1 c and d. Considering those predictors of poor resynchronization success, LV quadripolar lead was removed and a His mapping was performed using quadripolar Josephson curve catheter. A sub-Hisian block was demonstrated (HV interval 105 ms). Therefore, it has been mapped proximal LB. Using the delivery tool for LBBP and the 3830 lead (Medtronic Inc, Minneapolis, MN) a LBB EGM was reached. The paced QRS morphology demonstrated the notch at the nadir in lead V₁, known as the “W pattern” (Fig. 2 a-b). An LBB-local ventricular EGM interval of 35 ms has been found; a transition in QRS morphology from non-selective to selective LBB capture with decrementing output and a peak LV activation time in leads V5–V6 <80 ms demonstrated the corrected orientation of pacing lead. Therefore, the lead tip was maintained perpendicular to the septal surface using the sheath, that provided stability, and it was then implanted into the septum reaching LV septal subendocardium, penetrating the tip of the lead 6–8 mm into the septum. The position was confirmed by the fulcrum sign in fluoroscopy during sheath angiography in LAO 30° (Fig. 2 c). The lead advancement was performed in LAO 40°. High-output to low-output pacing was then recorded, showing shortening of QRS duration. The thresholds obtained was 1V @ 0.4 msec with a QRS duration of 110 msec (Fig. 2 e). After assessing catheter stability, the delivery system was retracted gently while advancing the lead, reducing lead tension and the risk of dislodgement. Last impedance value was 580 Ω. The echocardiography post implantation showed the deep placement of the lead on the interventricular septum (Fig. 2 d-e). As confirmed by clinical and instrumental response, an effective resynchronization has been obtained. After 3 months we assisted to an improvement in patient’s LV systolic function of 17 % (from 18 to 35 %) and, at the device check, to stability of its electronic parameters.

4. Discussion/conclusions

Literature advises employment of HBP in case of failed LV lead implantation or as an alternative pacing site when coronary sinus lead implantation is unsuccessful. LBBP seems to have better electrical parameters compared to HBP and a wider target area for implantation. The use of intracardiac conduction intervals to predict CRT response has already been described [2,3]. The IVCD and the wide QRS obtained with BiVP exposed the high probability of being non-responder to CRT [6]. Therefore, despite a lateral-anterior vein of CS could be an adequate site of LV lead positioning according to literature, our approach was to prefer a CSP to BiVP in this case. Considering the recorded prolonged H–V interval, the chosen resynchronization approach has been LBBP. LBBP has emerged as an alternative modality to deliver physiological pacing as it overcomes many of the limitations of the HBP. LBBP was then performed as previously described [5], reaching low thresholds and optimal QRS duration. In this case the use of endocardial conduction intervals measurement during CRT procedure is fundamental to perform the optimal patient-tailored resynchronization therapy. The IVCD is an interesting, feasible and effective measure to choose the best CRT approach. The use of the IVCD to determine when to perform CSP in patients indicated for standard CRT resulted in a significant increase in the number of responders as reported in a recent paper [3]. In case of a conduction delay <100 ms, the application of the CSP therapy led to improved cardiac resynchronization when compared to patients with a similar conduction delay but treated with standard BiVP [3]. Large cohort studies are necessary to demonstrate this rationale approach to CRT.

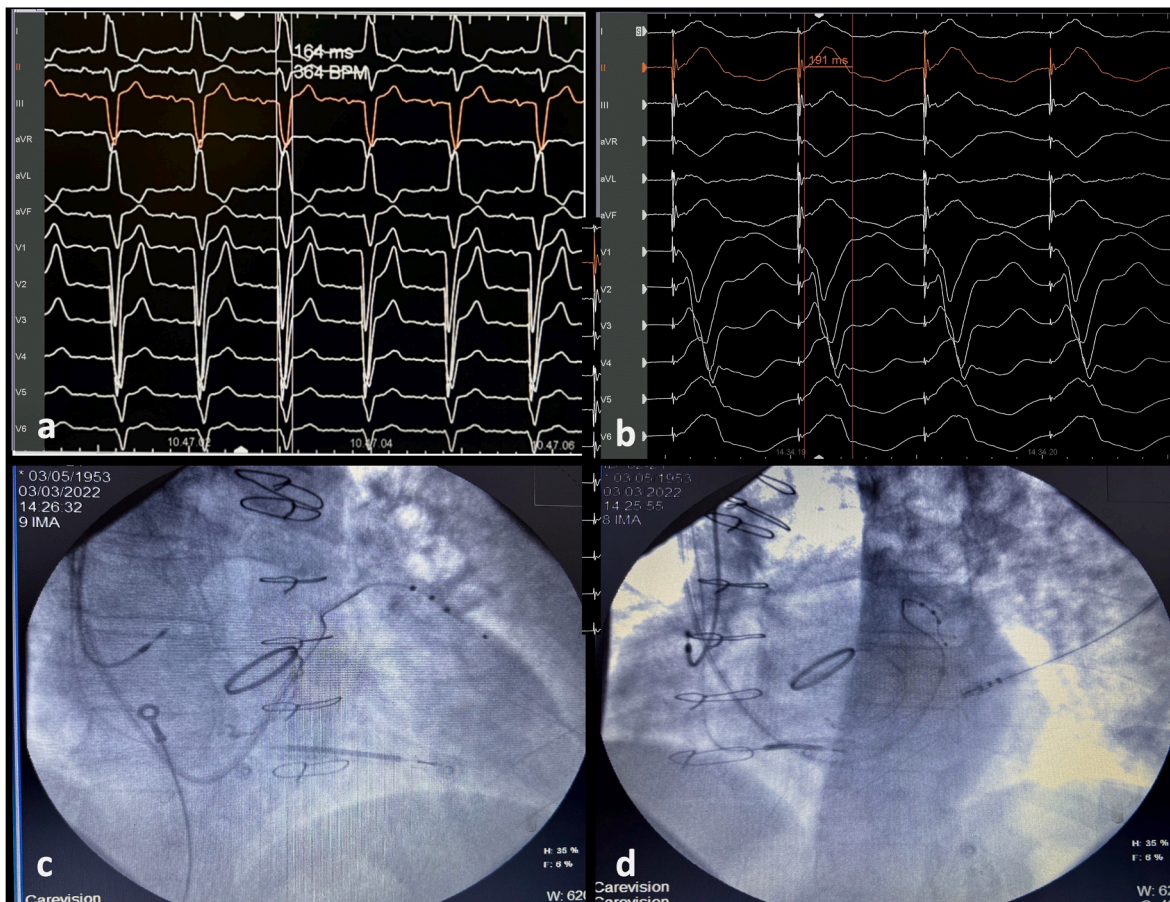


Fig. 1. a: ECG and basal QRS; b: ECG and BiVP QRS; c: BiVP on left anterior oblique projection 20°; d: BiVP on right anterior oblique.

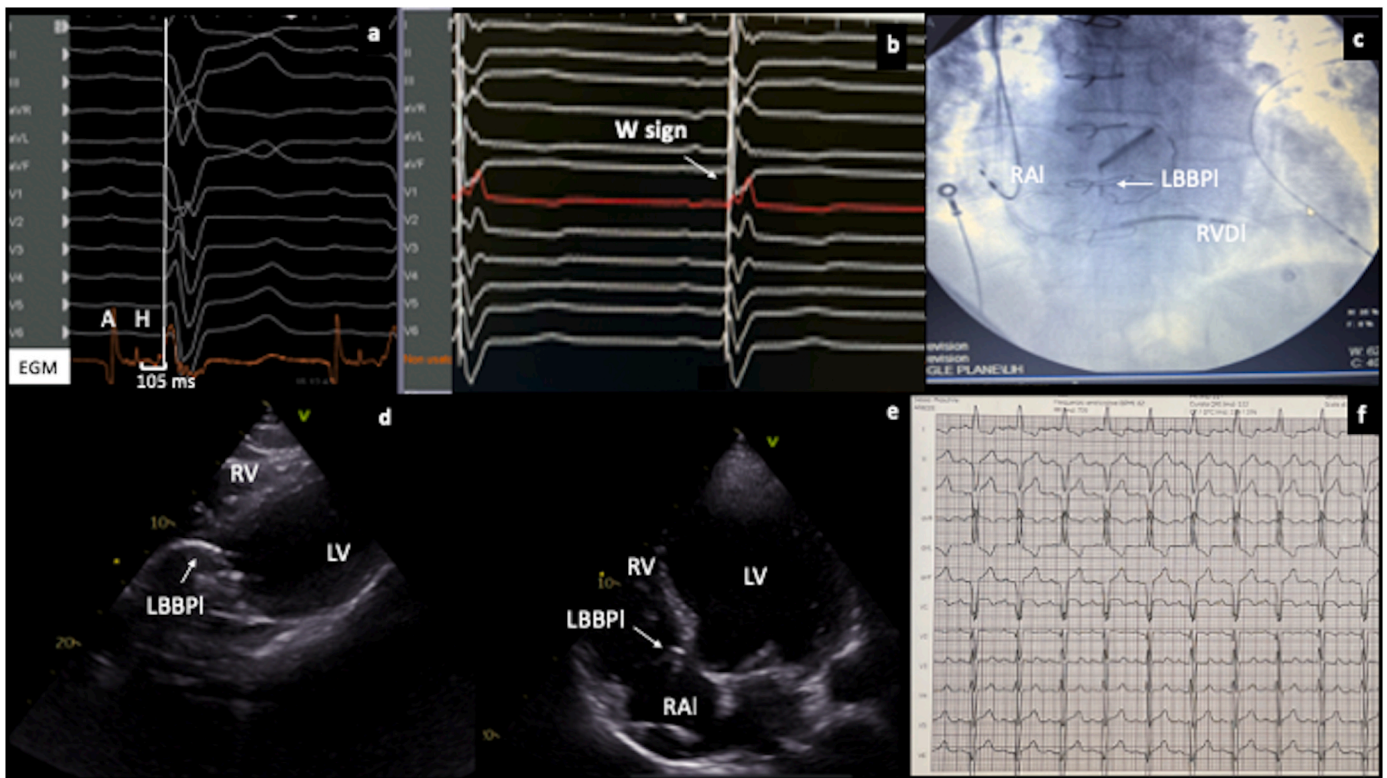


Fig. 2. a: His potential on EGM trace and “W” sign on V1 lead at starting lead rotation in distal His/LBB area; b: W sign during pacing; c: LBBP position on anterior-posterior view; d: echocardiographic sub-costal view; e: apical 4 chamber; f: final ECG. A: atrial EGM; H: distal His potential. RAI: right atrial lead; RVDI: right ventricular defibrillator lead; LBBPI: left bundle branch pacing lead. RV: right ventricle; LV: left ventricle.

Funding

None.

Declaration of competing interest

None.

References

- [1] Glikson M, Nielsen JC, Kronborg MB, et al. ESC Guidelines on cardiac pacing and cardiac resynchronization therapy. *Eur Heart J* 2021;42(35):3427–520. <https://doi.org/10.1093/eurheartj/ehab364>. 2021.
- [2] Gold MJ, Singh JP, Ellenbogen KA, Yu Y, Wold N et al., Interventricular electrical delay is predictive of response to cardiac resynchronization therapy, 10.1016/j.jacep.2016.02.018.
- [3] Santoro A, Landra F, Marallo C, Taddeucci S, Sisti N, et al. Biventricular or conduction system pacing for cardiac resynchronization therapy: a strategy for cardiac resynchronization based on a hybrid approach. *J Cardiovasc Dev Dis* 2023; 10(4):169. <https://doi.org/10.3390/jcdd10040169>. PMID:37103048. PMCID: PMC10146594.
- [4] Mulia EPB, Amadis MR, Julario R, Dharmadhati BB. Left bundle branch pacing: an evolving site for physiological pacing. *Journal of Arrhythmia* 2021;37(6):1578–84. <https://doi.org/10.1002/joa3.12638>.
- [5] Ponnusamy S S, Arora V et al., Left bundle branch pacing: a comprehensive review, *J Cardiovascular Electrophysiol*, doi:10.1111/jce.14681.
- [6] Naqvi SY, Jawaid A, Goldenberg I, et al. Non-response to cardiac resynchronization therapy. *Curr Heart Fail Rep* 2018;15:315–21. <https://doi.org/10.1007/s11897-018-0407-71LG>.