



Managing Incomplete and Complete Thoracolumbar Burst Fractures (AO Spine A3 and A4). Results from a Prospective Single-Center Study Comparing Posterior Percutaneous Instrumentation plus Mini-Open Anterolateral Fusion versus Single-Stage Posterior Instrumented Fusion

This is the peer reviewed version of the following article:

Original:

Todeschi, J., Ganau, M., Zaed, I., Bozzi, M.T., Mallereau, C.-H., Gallinaro, P., et al. (2021). Managing Incomplete and Complete Thoracolumbar Burst Fractures (AO Spine A3 and A4). Results from a Prospective Single-Center Study Comparing Posterior Percutaneous Instrumentation plus Mini-Open Anterolateral Fusion versus Single-Stage Posterior Instrumented Fusion. *WORLD NEUROSURGERY*, 150, e657-e667 [10.1016/j.wneu.2021.03.069].

Availability:

This version is available <http://hdl.handle.net/11365/1280638> since 2024-12-12T20:56:13Z

Published:

DOI: <http://doi.org/10.1016/j.wneu.2021.03.069>

Terms of use:

Open Access

The terms and conditions for the reuse of this version of the manuscript are specified in the publishing policy. Works made available under a Creative Commons license can be used according to the terms and conditions of said license.

For all terms of use and more information see the publisher's website.

(Article begins on next page)

Title: Managing incomplete and complete thoraco-lumbar burst fractures (AO Spine A3 and A4). Results from a prospective single center study comparing posterior percutaneous instrumentation plus mini-open antero-lateral fusion versus single stage posterior instrumented fusion.

Authors: Julien Todeschi¹ MD, Mario Ganau MD PhD, Ismail Zaed MD, Maria Teresa Bozzi MD, Charles-Henry Mallereau MD, Paolo Gallinaro MD, Helene Cebula MD, Irene Ollivier MD, Giggio Spatola MD, Dominique Chaussemy MD, Hugo-Andres Coca MD, François Proust MD PhD, Salvatore Chibbaro MD PhD

Affiliations:

¹ Neurosurgery Department, Hautepierre Regional Hospital, Strasbourg University, Strasbourg, France

Corresponding Author:

Ismail Zaed, MD
Department of Neurosurgery
Hautepierre Regional Hospital, Strasbourg University
Email: ismailzaed1@gmail.com
Tel. 0033 3 88127614

Short Title: Managing thoracolumbar fractures with a two-stages MIS strategy

Keywords: thoracolumbar fracture, burst fracture, anterolateral fusion, corpectomy, titanium cage, rib graft, pseudarthrosis, minimally invasive surgery (MIS).

Conflicts of Interest and Source of Funding: None of the authors has a conflict of interest to disclose

Funding: none

Previous presentation: none

1 **Title** Managing incomplete and complete thoraco-lumbar burst fractures (AO Spine A3 and
2 A4). Results from a prospective single center study comparing posterior percutaneous
3 instrumentation plus mini-open antero-lateral fusion versus single stage posterior
4 instrumented fusion.

5

6 **ABSTRACT**

7 **Object**

8 Treatment strategy for thoraco-lumbar burst fractures is still debated. The aim of this study is
9 to evaluate clinical and radiological outcomes of a two-stage strategy with immediate
10 posterior percutaneous instrumentation and delayed antero-lateral fusion (Group A) versus a
11 single stage open posterior instrumented fusion (Group B).

12 **Patients and methods**

13 Demographics, clinical and surgical data of patients operated for AO Spine A3 and A4
14 fractures were prospectively collected. Vertebral height and deformity were evaluated prior
15 and after surgery. VAS for back pain, ODI and SF-12 for quality of life assessment were
16 collected during follow up.

17 **Results**

18 Among the 110 patients enrolled, 66 were allocated to Group A and 44 to Group B; most
19 common fractured level was T12 (34%). Postoperative complications resulted higher in
20 Group B, especially wound infection rate (18% vs 3%), and pseudo-meningocele (14% vs
21 0%). The two-stage approach allowed an average long-term gain of 15.8° at the local
22 kyphosis of fractured vertebra and 5.8° at the regional level (Cobb Angle), vs 15,4° and 5,5°
23 of Group B. At 2-year follow-up, both Groups demonstrated significant functional
24 improvements, however VAS and ODI metrics appeared more favorable for Group A patients
25 ($p < 0.0001$ vs $p < 0.003$). Complete fusion rate was obtained in 100% of Group A vs 65% of
26 Group B.

27 **Conclusion**

28 Our study indicates that percutaneous instrumentation and anterior fusion or expandable cage
29 lead to excellent long-term clinical and radiological outcomes with lower complication rate
30 and higher fusion rate than open posterior approaches.

31 **Keywords:** thoracolumbar fracture; anterolateral fusion; corpectomy; titanium cage;
32 pseudarthrosis; minimally invasive surgery (MIS); early recovery after surgery.

1 INTRODUCTION

2 Reconstructing the anterior column in thoraco-lumbar burst fractures is nowadays considered
3 essential to restore/maintain sagittal and coronal alignment, achieve satisfactory fusion and
4 prevent failure of posterior implants ¹. It is well known that posterior instrumentation alone
5 might be subject to failure of the anterior column, as per the three-column concept of thoraco-
6 lumbar spinal fractures initially devised by Francis Denis, hence bearing an intrinsic risk of
7 progressive postoperative kyphosis. The combination of posterior and anterior approaches has
8 therefore been proposed as a more effective strategy to tackle the loss of correction in the long
9 term ².

10 This said, the best management of such fractures is still a matter of debate, while we lack a
11 shared, universal consensus, the surgical strategy is tailored to the individual patient's
12 characteristics and surgeon's preference^{3,4}. Arguments in favor of open posterior
13 decompression and fixation include the easy and well standardized approach with direct
14 decompression of the spinal cord and conus medullaris, the rapid reduction of these fractures,
15 and the reasonable correction of the thoraco-lumbar alignment. Posterior approaches also
16 spare the operating team and patients from the operative morbidity of anterior approaches,
17 given their burden of potentially severe pulmonary and vascular complications^{5,6}. In fact, the
18 presence of diaphragm, pleura and peritoneum in close proximity to this spine represents a
19 specific operative challenge for any anterior surgical access⁷. Nonetheless the main criticism
20 for open approaches is that they damage the posterior column, which is otherwise usually
21 spared from traumatic mechanisms leading to A3 and A4 fractures.

22 During the last decades, the development of less invasive extra-pleural and retroperitoneal
23 approaches⁸ has minimized risks of open anterior approaches, while providing excellent
24 exposure for good decompression and antero-lateral anatomical reconstruction^{9,10}. Although
25 the development of expandable cages to support the anterior column offered remarkable
26 biomechanical advantages, it has not eliminated the need for lateral and in many instances
27 also posterior screw fixation¹¹. Hopefully new strategies spurred from the implementation of
28 combined approaches leveraging on the holistic concepts of minimally invasive surgery
29 (MIS), as such immediate percutaneous posterior screw fixation to immobilize the thoraco-
30 lumbar junction, followed by a delayed mini open anterior approach to reconstruct the
31 anterior column, became the philosophy of choice in our Institution. In theory, this strategy
32 would offer a series of advantages from both clinical and biomechanical perspectives, those
33 include: a reduced morbidity rate compared to more invasive open approaches, an increased

1 chance to avoid kyphotic deformities, a potentially faster fusion process, etc.
2 This study was meant to ascertain the theoretical advantages of the abovementioned 360°
3 spinal fixation strategy in managing single level thoraco-lumbar burst fractures compared to
4 open posterior instrumented fusion. With the aim to contribute to the current literature on
5 burst fracture, our objectives were to evaluate the perioperative complication rate, and to
6 assess the radiological and functional outcomes of patients enrolled in this prospective
7 comparative study.

8

9 **PATIENTS AND METHODS**

10 *Design of the study*

11 This is a single-center prospective study conducted between January 2007 and December
12 2016 on a series of 110 patients treated for unstable thoraco-lumbar burst fractures (AO Spine
13 A3 and A4). A Thoraco-Lumbar Injury Classification and Severity System (TLICS)¹² score \geq
14 5, and an American Spinal Injury Association Impairment Scale (AIS) E or D represented the
15 most important inclusion criteria; fractures' instability and the need for anterior treatment
16 were also assessed with the Load Sharing Score (LSS)¹³, with all candidates considered for
17 inclusion scoring ≥ 7 .

18 Exclusion criteria were as follows: AIS A, B or C, multilevel vertebral fractures, an history of
19 instrumented spine surgery. Child bearing women and patients below 18 years were also not
20 included. Smoking status, as well as presence of comorbidities such as diabetes, obesity,
21 blood hypertension, and cardiovascular pathologies did not represent a contraindication to the
22 enrollment in this study; however they were duly recorded and considered in the post-hoc
23 analysis. At time of consenting for surgical management, patients were given the chance to
24 opt for either a two-stage strategy with immediate posterior percutaneous instrumentation and
25 delayed antero-lateral fusion (Group A), or a single stage open posterior instrumented fusion
26 (Group B).

27 *Clinical evaluation*

28 Impairment scale calculations were performed by using an electronic version
29 (www.isncscialgorithm.com) of the ASIA International Standards for Neurological
30 Classification of Spinal Cord Injury (ISNCSCI). Patients were followed up clinically at 3, 6,
31 12 and 24 months; Data regarding Visual Analogue Scale (VAS) for back pain, Oswestry
32 Disability Index (ODI) and quality of life assessed by the 12-Item Short Form Health Survey
33 (SF-12), exploring the physical component score (PCS) and mental component score (MCS),

1 were collected for all patients at 24 months postoperatively follow-up (FU), and duly
2 registered in their case report form (CRF).

3 Presence of comorbidities and details from previous medical history were recorded at time of
4 clerking patients: prevalence of diabetes (type I and II) and blood hypertension were recorded
5 as dichotomy variables, whereas obesity in terms of body mass index (BMI) was calculated as
6 a continuous variable. Average for Group A and B was calculated at time of post-hoc analysis
7 and correlated to postoperative outcomes.

8 ***Radiological evaluation***

9 Radiological evaluation was conducted by 2 independents radiologists using standing x-rays
10 in antero-posterior (AP) and lateral (LL) views, as well as sagittal and coronal CT scans with
11 bone window .

12 Two aspects were included in the analysis: 1) the vertebral height and deformity of the spine
13 before and after surgery, and 2) the long-term implant integration and bony fusion. For the
14 purposes of this study the images were analyzed at the following time points: preoperatively,
15 postoperatively after the MIS instrumentation, postoperatively after the anterolateral fusion
16 and finally at 2-year follow up.

17 The first aspect, spinal alignment, was thoroughly assessed on sagittal CT scan images and on
18 standing LL x-rays; to this extent, three pre-and postoperative parameters were considered
19 **[Figure 1]:**

20 - 1) the kyphotic deformation of the fractured vertebra was assessed by calculating the angle
21 between the upper plate and the lower plate (Angle 1).

22 - 2) the Cobb angle was assessed by calculating the regional kyphosis angle between the
23 upper plate of the overlying vertebra and the lower plate of the vertebra underlying the
24 fracture (Angle 2).

25 - 3) the Gardner's angle was assessed by calculating the kyphosis angle formed between the
26 upper plate of the vertebra above the fracture and the lower plate of the fractured vertebra
27 (Angle 3).

28 The second aspect, bone fusion, was assessed on coronal and sagittal CT scan with bone
29 windows, and defined as complete and incomplete depending on the presence or absence of
30 bony bridges between the cage and the superior/inferior vertebral body as well as through the
31 cage for Group A, and the presence of postero-lateral fusion for Group B.

32

33

1 ***Surgical strategies***

2 Group A underwent immediate posterior percutaneous instrumentation extended two levels
3 above and below the fracture in an emergency setting [**Figure 2**]. Screw insertion (ES2 Spinal
4 system[®]; Stryker) was performed under radiological guidance with AP and LL views obtained
5 by C-arm fluoroscopy on a radiolucent operating table, a focal decompression was obtained if
6 needed (i.e. AIS D on admission) through a short midline incision as per standard MIS
7 practice. In this Group a delayed second stage intervention was planned (2 and 3 weeks later)
8 on an elective list during daytime hours, this consisted in a mini-open antero-lateral approach
9 with selective corpectomy of the fractured vertebral body and interbody fusion by either a
10 titanium mesh (Pyramesh[®]; Medtronic) or an expandable cage (V-lift[®]; Stryker) [**Figure 3**].
11 In either case, the implant was filled with bone resulting from the corpectomy and when
12 available the split rib used as a strut graft. Between the first and second stage additional
13 investigations were carried out, and specifically standing x-rays and CT scan with bone
14 window. Group B patients underwent an open posterior instrumented fusion in an emergency
15 setting. In this Group pedicle screws and rods (XIA Spinal system[®] Stryker) were inserted
16 two levels above and below the fracture using anatomical landmarks with radiological
17 verification; furthermore, a postero-lateral grafting was always carried out by using either
18 bone fragments resulting from any laminectomy or allogeneic grafts from bone bank.

19 ***Statistical analysis***

20 The statistical analysis included a descriptive comparison of preoperative and postoperative
21 variables by using the t-test for continuous data (i.e. pre and post-op VAS, angle
22 measurements), whereas z-score and OR were calculated to correlate the presence of
23 preoperative comorbidities (smoking, diabetes, and BMI>30) with the primary postoperative
24 outcome: osseointegration. Two-sided significance level was defined as p.05. Data analysis
25 was performed using GraphPad Prism version 6.00 for Windows (GraphPad Software, La
26 Jolla, California, USA, www.graphpad.com);

27 ***Ethics***

28 This study was conducted according to the Ethical Principles for Medical Research Involving
29 Human subjects stated in the 2004 and its further revision made in 2008 and 2013 of the
30 Declaration of Helsinki. To be eligible for the study, patients were asked to sign an informed
31 consent form previously approved by the Institutional Research Board. To report our results,
32 we followed the recommendations of the STROBE (Strengthening the Reporting of
33 Observational Studies in Epidemiology) statement for observational studies ¹⁴.The study was

1 approved by the IRB the French National Neurosurgery society (Reference n°: IRB-
2 00011687).

3

4 **RESULTS**

5 *Patients demographic and radiological pre-operative features*

6 Hundred-ten patients (52 women and 58 men, mean age 41 ± 15 years) were included in this
7 study, 66 were allocated to Group A and 44 to Group B. In Group A, the most common
8 fracture level was T12 (34.8%), with a prevalence of A4 complete burst fractures (66.6%)
9 over A3 incomplete burst fractures. In Group B, the most common fracture level was still T12
10 (40.9%), with a strong prevalence of A4 complete burst fractures (68.2%). In both group of
11 patients, the median scores for TLICS and LSS were 6 ± 1 and 8 ± 1 , respectively [**Table 1**].
12 Overall, 87% of patients were AIS E on admission. In Group A, during mini-open antero-
13 lateral approach, 7 patients (11%) underwent insertion of titanium mesh, while all the other
14 patients (n=59) had expandable cages (89%). Median operating time resulted to be 105 ± 18
15 minutes and 145 ± 25 minutes for the percutaneous fixation and mini-open lateral approaches
16 respectively, whereas in Group B operating time was 175 ± 35 minutes. Average blood loss
17 was significantly different in the two Groups: in Group A, it was negligible for both the
18 posterior percutaneous approach and the antero-lateral one (180 ml; range: 110 to 390 ml);
19 whereas perioperative blood loss in Group B was much higher (650 ml; range 550 to 1100
20 ml).

21 *Clinical and radiological data postoperatively*

22 Median postoperative hospital stay for Group A was of 4 ± 1 days and of 6 ± 2 for the first and
23 second stage surgery, respectively: whereas patients in Group B had a median length of stay
24 of 11 ± 3 days. No perioperative neurological complications or implants malposition needing
25 surgical revision were recorded in either group. Postoperative complications in Group A
26 included: superficial wound infection in 2 cases (3%), symptomatic hemothorax in 2 cases
27 (3%), and pneumothorax in 5 cases (7.5%) requiring a 3-day course of drainage via chest
28 tube. All those complications were managed conservatively with no need for revision surgery.
29 Infection rate in Group B resulted to be 18%, hence much higher than in patients treated with
30 the 2-stage strategy, furthermore Group B patients had a 14% incidence of clinically
31 significant pseudo-meningocele requiring surgical revision.

32 At the 2 years follow up all patients in Group A had a minimal ODI score (0 to 20%) and
33 significant improvement in VAS score ($1\pm 0,8$ versus $8.6\pm 0,8$ preoperatively, $p < 0,0001$), their

1 average SF-12 PCS score was of $57.9\% \pm 6.1\%$ and SF-12 MCS score was of $62.5\% \pm 10.5\%$.
2 On the other hand, patients in Group B also achieved a minimal ODI score (0 to 20%),
3 although they showed a lesser improvement of VAS score (4.5 ± 1 versus 9 ± 0.5 , $p < 0,003$),
4 their average SF-12 PCS score was of $53.4\% \pm 5.2\%$ and SF-12 MCS score was of $50.2\% \pm$
5 9.2% [Figure 4].

6 Our study demonstrated a statistically significant difference for all the 3 radiological
7 parameters assessed pre- and postoperatively [Table 2]. In Group A, Angle 1 (kyphotic
8 deformation of the fractured vertebra) resulted in an average difference of $15,8^\circ$ CI 95% [8,8;
9 20,7] $p < 0,0001$; Angle 2 (Cobb angle) an average difference of $5,8^\circ$ IC 95% [0,6; 10,1] $p =$
10 $0,002$; and Angle 3 (Gardner's Angle) an average difference of $7,1^\circ$ 95% CI [3,5; 10,7] $p =$
11 $0,0005$; On the other hand, in Group B, Angle 1 resulted in an average difference of $15,4^\circ$ CI
12 95% [8; 19,9] $p < 0,0001$; Angle 2 an average difference of $5,5^\circ$ CI 95% [1,1; 9,2] $p = 0,003$;
13 and Angle 3 an average difference of $6,5^\circ$ CI 95% [3,1; 11,6] $p = 0,0003$. No statistically
14 significant differences were recorded between the two groups regarding all the pre and
15 postoperative radiological parameters evaluated. Of note, the correction loss over time of the
16 injured vertebra was minimal, and additional statistical analysis failed to demonstrate any
17 significance with regards to these time points.

18 Remarkable bony integration within the mesh/cage and across the level of fracture was
19 achieved in 100% of the cases in Group A; bone fusion was instead achieved in only 65% of
20 the Group B patients. Given the superior fusion rate and quality, a choice of posterior
21 instrumentation removal was systematically offered to all patients in Group A, however only
22 80% of them opted for implant removal. Younger patients complaining of local discomfort or
23 reporting a limitation of flexion/extension spine movements mostly took this choice. The
24 same option was offered to all patients in Group B although none of them requested removal
25 of the instrumentation, even in those cases where complete fusion was confirmed on long-
26 term FU. The reason for this decision was unanimously the aversion for additional surgical
27 interventions, which justifies their initial option for posterior surgery alone.

28 Descriptive analysis revealed that a homogeneous distribution of comorbidities across the two
29 groups with the exception of a higher prevalence of individuals with diabetes ($p = 0,0088$)
30 and blood hypertension ($p = 0,01108$) in Group B [Table 3]. Post-hoc analysis confirmed that
31 smoking (OR 4.09, CI 95% 1.02, 16.4) and BMI >30 (OR 2.48 CI 95% 0.45, 13.51)
32 represented a risk factor for lack of osteointegration in Group B. No other relevant correlation
33 was found between preoperative comorbidities and postoperative outcome.

1

2 **DISCUSSION**

3 The present study evaluated the perioperative complication rate and assessed radiological and
4 functional outcomes of patients admitted with incomplete and complete thoraco-lumbar burst
5 fracture treated with two different surgical strategies. The statistical analysis carried out to
6 compare the 360° MIS instrumented fusion of Group A with the open posterior instrumented
7 fusion of Group B revealed that the two-stage strategy delivers its theoretical advantages.

8 In fact, Group A patients appeared to have comparable length of stay, with lower
9 postoperative complications, better functional recovery and higher fusion rate at 2 years
10 follow up. In the present study the 360° strategy led also to a satisfactory correction of spinal
11 alignment which was maintained very nicely at long-term follow up. Of note, our study also
12 contributed to shed light on the clinical implications of kyphotic correction, which is still a
13 matter of debate because earlier studies failed to find a clear correlation between the
14 postoperative degree of kyphosis and the long-term degree of pain or disability^{6, 15}. Although
15 for scientific and organizational reasons open posterior instrumented fusion remains a well
16 standardized and universally accepted practice, the radiological and clinical results achieved
17 in Group A justify the growing interest toward MIS multi-staged strategies, such as that
18 proposed in our Institution.

19 ***Stabilization of Posterior and Middle Columns***

20 Over the years, pedicle screw fixation for the treatment of thoraco-lumbar burst fractures
21 became a popular strategy overcoming the limitations of laminar hooks and allowing for a
22 good rigid fixation¹⁶. The advantages of posterior instrumentation also include the immediate
23 decompression of spinal canal, the identification of intracanal fragments, which might be
24 facilitated by use of intraoperative ultrasound, and a consideration for ligamentotaxis¹⁷.
25 However, it should be noted that the differences between long and short posterior
26 instrumentation are not so obvious, especially when using mono-axial screws. Recently,
27 Dobran et al¹⁹ compared long and short instrumentation for fractures at the thoraco-lumbar
28 junction and reported similar results regarding both correction of kyphosis and the
29 maintenance of sagittal alignment. Shorter constructs however have the advantage of reduced
30 operative time as well as risk of screw malposition and related neurological complications,
31 and obviously preserve two extra segments of vertebral motion. Longer posterior
32 instrumentation, on the other hand, ensures a better distribution of biomechanical stress across
33 the thoraco-lumbar junction and reduces the risk of pull out. Unfortunately, those

1 biomechanical needs are relevant only in the first year following the traumatic event, in fact,
2 once spine fusion is achieved, long constructs put a toll in terms of spine stiffness and patient
3 compliance. In our experience the advantages of performing a long posterior instrumentation
4 combined with mini open anterior approach, even beyond the consolidation process, are
5 highest in patients with obesity, osteoporosis, and significant vertebral splitting with major
6 loss of height of the vertebral body.

7 ***Stabilization of Anterior column***

8 A reconstruction of the anterior column is indicated in thoraco-lumbar fractures caused by
9 compression mechanisms with burst of the vertebral body. Our series confirms that a selective
10 rather than a total corpectomy helps maintaining a relatively short average operative time but
11 also allow achieving a satisfactory biomechanical stability²⁰. Furthermore, our study bring
12 additional evidence that the preservation of the endogenous blood supply by a selective
13 corpectomy promotes faster healing and better fusion²¹.

14 The use of mesh or expandable titanium cages allows avoiding the need for autologous graft
15 from distant donor sites, as well as the use of bone from tissue banks, hence increasing the
16 overall safety of the approach and reducing costs. In our series, the choice between mesh and
17 expandable cage was systematically made according to the extent of the performed
18 corpectomy. Depending on the characteristic of the fracture, the selective corpectomy entailed
19 either a 1-disc level fusion (such as A3 fractures where one endplate of the affected vertebral
20 body was preserved) or a 2-disc levels fusion (in all other A4 fractures where the mesh/cage
21 was bridging the inferior endplate of the vertebra above and the superior endplate of the
22 vertebra below the fractured one). These implants offer the advantage of an immediate
23 mechanical strength and have good resistance to pullout ²². In addition, the cancellous bone
24 obtained at time of the corpectomy and filled into the cage/mesh provides a greater amount of
25 cells and osteogenic factors that the tri-cortical bone obtained from iliac crest¹. Whenever a
26 rib was excised to approach the fractured vertebra, we always applied it as strut graft on either
27 side of the cage to enhance the bone fusion. Our guiding belief was that all those aspects of
28 our surgical strategy played an important role in preventing the risk of pseudarthrosis. Of
29 note, in our study we did not explored the use of heterologous substitute (i.e. BMP), hence an
30 educated inference can be made regarding the biomechanical advantages of our 360°
31 construct without any confounding factor caused by the use of biologics.

32 ***Surgical Timing***

33 The advantages of our strategy include the possibility to intervene as early as possible and

1 provide a MIS stabilization of the fracture, while carefully planning for the reconstruction of
2 the anterior column in a delayed elective surgical session. The second stage allows for a direct
3 visualization of the spinal canal enhancing the chance of good decompression which is
4 certainly superior to the one obtained from a posterior approaches alone ²³. The choice of
5 performing a percutaneous approach without laminar decompression is based on the nature of
6 burst fractures: essentially, the mechanism of injury involves the anterior elements while
7 posterior ones might be initially spared, hence to our eyes preserving the posterior
8 ligamentous complex and paraspinal muscles represent whenever feasible a more
9 biomechanically-sound choice. In fact, while the patients included in this series were all
10 presenting with AIS E, it should be noted that in those presenting with AIS D, C and B at
11 baseline we tend to adopt the same surgical strategy with only a small variation which
12 consists in supplementing the initial percutaneous screw insertion with a midline incision and
13 selective laminectomy to decompress the spinal canal and relieve the pressure from the neural
14 elements.

15 Paradoxically, despite Group A patients underwent multiple procedures, their treatment was
16 tailored to the biomechanical needs of AO Spine A3 and A4 fractures. On the other hand, we
17 can argue that privileging the technically easier open posterior instrumented fusion may lead
18 to the risk of an overtreatment with time-consuming muscle dissection and extension of the
19 construct up to 3 levels above and below the fractured vertebra.

20 ***Bony integration***

21 Long-term bony integration following any type of spinal fixation is greatly dependent on a
22 good primary stability at the time of initial surgery and subsequent creation of sustained
23 structural and functional bridging between the surrounding living bone and the surface of the
24 load-bearing implant⁴³. Although failure to achieve bony integration does not preclude a good
25 clinical outcome (hence the concept of short non fusion surgery for thoracolumbar fractures),
26 it increases the risk of dissatisfaction with treatment⁴². For this reasons surgeons and scientists
27 have focused so much attention over the last decades to achieve rapid bio-integration and
28 long-lasting bone fusion. Successful bony integration (which might be as low as 40% in some
29 series) requires a series of events including initial inflammation, bone formation, and
30 remodeling which could be impaired in patients with diabetes, high BMI and smoking
31 habitus^{43,44}. While our cohort appeared to be homogeneous in terms of baseline comorbidities,
32 Group A patients were younger than Group B, who showed instead higher prevalence of
33 diabetes and blood hypertension. Our statistical analysis, though, revealed that the only

1 factors affecting the chance of achieving bony integration were smoking and BMI >30. On
2 one hand, we may suggest that they contributed to the lower rate of osseointegration noted in
3 Group B compared to Group A; on the other hand, we may also argue that in Group A the
4 anterior and posterior stabilization contributed to offset the impact of those risk factors,
5 justifying why bony integration was achieved at follow up in all patients. A preliminary
6 conclusion that can be drawn from our series is therefore that the combined approach could
7 potentially yield better results in patients more at risk of pseudo-arthrosis due to their baseline
8 comorbidities. This hypothesis might serve as a valuable research question for further studies.

9 ***Technical evolution of MIS approaches***

10 In the last few years several reports have shown very good outcomes using the mini-open
11 antero-lateral approach combined with posterior fixation for burst and compression fractures^{4,}
12 ²⁴⁻³⁰. This less invasive approach allows for satisfactory exposure with limited risks; however
13 other techniques have also been developed to further minimize exposure-related morbidity,
14 they include the antero-lateral video-laparoscopic/-thoracoscopic approach as well as the
15 extreme lateral approach (XLIF), which is mostly used in degenerative lumbar surgery³¹⁻³³.
16 These approaches to the anterior thoraco-lumbar spine are known to result in shorter hospital
17 stays, shorter convalescence time and better cosmetic results compared to open approaches³⁴⁻
18 ³⁶, nevertheless their longer learning curve justifies the paucity of reports/series available to
19 date.

20 It is known that anterior column reconstruction through a posterior approach with uni- or
21 bilateral transpedicular corpectomy offers a limited operative corridor, resulting in a poorer
22 visualization of the vertebral body compared to an antero-lateral approach, and an increased
23 risk of subsequent loss of correction¹⁰. This explains why the long-term results obtained
24 through posterior vertebrectomies are less favorable when compared to antero-lateral ones^{4, 7,}
25 ³⁷. Additionally, the mini-open access used in our series has several advantages: 1) it avoids
26 unwanted and dangerous retraction of retroperitoneal vessels, 2) it does not require dissection
27 of the sympathetic plexus, 3) it does not entail unnecessary manipulation of abdominal
28 viscera, 4) it limits muscle dissection, 5) it reduces manipulation of nerve structures and
29 increases the operative working area needed to fully excise the vertebral body and adjacent
30 discs⁹.

31 **Complications**

32 Our series contributes to the discussion on early recovery after surgery by highlighting that a
33 360° strategy can combine the advantages of percutaneous screw fixation and mini-open

1 antero-lateral approach. On paper this choice does not come without drawbacks: patients with
2 dual approaches are more likely to have infectious complications, scarring issues, breathing
3 problem, and blood loss^{4, 29, 38, 39}. However, while known complications for any antero-lateral
4 approach include dural tear, intercostal neuralgia, spleen hemorrhage, paraspinal abscesses,
5 cage subsidence, and chest infection^{13, 25}, none of them occurred in our series of mini-open
6 anterior approaches. On the contrary, the higher incidence of infection complications in
7 Group B might be attributed to the intrinsic risk associated to open surgery performed during
8 night-time, which is a known contributing factor to intra- and postoperative complications.
9 Additionally, no anesthetic complications occurred during this study: this aspect is
10 particularly important because Group A patients had two general anesthesia \pm one in case of
11 screws removal, Group B patients has a 14% incidence of redo surgery to address wound
12 dehiscence due to persistent pseudo-meningocele. Furthermore, the rate of thromboembolism
13 in our series was also remarkably low, perhaps because of our established protocol which is
14 particularly relevant in patients with spinal cord injuries^{40, 41}, and the faster mobilization after
15 treatment.

16 **Limitations of the study**

17 The main limitation of our study is its non-randomized design, nonetheless the two-stage
18 strategy with 360° approach to burst fractures became our philosophy hence the lack of
19 equipoise to accept this type of methodology for patient's selection. In drafting the research
20 protocol we have been guided by our good clinical practice principles of having an honest and
21 sensitive discussion with patients about their clinical condition, their management options and
22 expected clinical course, which eventually led to an informed and deliberate consent, ensuring
23 adherence of our study to the highest ethical standards. While the strict inclusion criteria
24 enhanced internal validity, they made hard to possibly extend our discussion to other patients
25 or fracture categories (such as pathologic fractures, pediatric population, etc.), as such
26 together with the randomization issue they somehow limit the external validity of our study.

27

28 **CONCLUSION**

29 Our 360° strategy led to higher fusion rates, providing good long-term clinical and
30 radiological outcomes in patients with thoraco-lumbar incomplete and complete burst
31 fractures comparing to single stage open posterior instrumented fusion. Beside correcting the
32 post-traumatic angular deformation and leading to a longstanding biomechanical stability, this
33 combined less invasive strategy paves the way for safe removal of the posterior screws and

1 release of two segments of vertebral movements once the osteosynthesis process has
2 terminated; hence offering potential advantages to younger patients.

3

4 **Disclosure of interest:** the authors report no conflict of interest concerning the material or
5 methods used in this study or the findings specified in this paper.

6

7 REFERENCES

- 8 1. Antoni M, Charles YP, Walter A, Schuller S, Steib JP. Fusion Rates of Different
9 Anterior Grafts in Thoracolumbar Fractures. *J Spinal Disord Tech.* 2015;28(9): E528-533.
10 <https://doi.org/10.1097/BSD.0b013e3182aab2bf>.
- 11 2. Reinhold M, Knop C, Beisse R, et al. Operative treatment of 733 patients with acute
12 thoracolumbar spinal injuries: comprehensive results from the second, prospective, Internet-
13 based multicenter study of the Spine Study Group of the German Association of Trauma
14 Surgery. *Eur Spine J.* 2010;19(10): 1657-1676. <https://doi.org/10.1007/s00586-010-1451-5>.
- 15 3. Vaccaro AR, Lim MR, Hurlbert RJ, et al. Surgical decision making for unstable
16 thoracolumbar spine injuries: results of a consensus panel review by the Spine Trauma Study
17 Group. *J Spinal Disord Tech.* 2006;19(1): 1-10.
18 <https://doi.org/10.1097/01.bsd.0000180080.59559.45>.
- 19 4. Lu DC, Lau D, Lee JG, Chou D. The transpedicular approach compared with the
20 anterior approach: an analysis of 80 thoracolumbar corpectomies. *J Neurosurg Spine.*
21 2010;12(6): 583-591. <https://doi.org/10.3171/2010.1.SPINE09292>.
- 22 5. Payer M. Unstable burst fractures of the thoraco-lumbar junction: treatment by
23 posterior bisegmental correction/fixation and staged anterior corpectomy and titanium cage
24 implantation. *Acta Neurochir (Wien).* 2006;148(3): 299-306; discussion 306.
25 <https://doi.org/10.1007/s00701-005-0681-5>.
- 26 6. Korovessis P, Baikousis A, Zacharatos S, Petsinis G, Koureas G, Iliopoulos P.
27 Combined anterior plus posterior stabilization versus posterior short-segment instrumentation
28 and fusion for mid-lumbar (L2-L4) burst fractures. *Spine (Phila Pa 1976).* 2006;31(8): 859-
29 868. <https://doi.org/10.1097/01.brs.0000209251.65417.16>.
- 30 7. Chou D, Wang VY, Gupta N. Transpedicular corpectomy with posterior expandable
31 cage placement for L1 burst fracture. *J Clin Neurosci.* 2009;16(8): 1069-1072.
32 <https://doi.org/10.1016/j.jocn.2008.12.009>.
- 33 8. Kim M, Nolan P, Finkelstein JA. Evaluation of 11th rib extrapleural-retroperitoneal
34 approach to the thoracolumbar junction. Technical note. *J Neurosurg.* 2000;93(1 Suppl): 168-
35 174.
- 36 9. Litre CF, Duntze J, Benhima Y, et al. Anterior minimally invasive extrapleural
37 retroperitoneal approach to the thoraco-lumbar junction of the spine. *Orthop Traumatol Surg*
38 *Res.* 2013;99(1): 94-98. <https://doi.org/10.1016/j.otsr.2012.08.006>.
- 39 10. Zidan I, Khedr W, Fayed AA, Farhoud A. Retroperitoneal Extrapleural Approach for
40 Corpectomy of the First Lumbar Vertebra : Technique and Outcome. *J Korean Neurosurg*
41 *Soc.* 2019;62(1): 61-70. <https://doi.org/10.3340/jkns.2017.0271>.
- 42 11. Pflugmacher R, Schleicher P, Schaefer J, et al. Biomechanical comparison of
43 expandable cages for vertebral body replacement in the thoracolumbar spine. *Spine (Phila Pa*
44 *1976).* 2004;29(13): 1413-1419.

- 1 12. Rihn JA, Anderson DT, Harris E, et al. A review of the TLICS system: a novel, user-
2 friendly thoracolumbar trauma classification system. *Acta Orthop*. 2008;79(4): 461-466.
3 <https://doi.org/10.1080/17453670710015436>.
- 4 13. McCormack T, Karaikovic E, Gaines RW. The load sharing classification of spine
5 fractures. *Spine (Phila Pa 1976)*. 1994;19(15): 1741-1744.
- 6 14. von Elm E, Altman DG, Egger M, et al. The Strengthening the Reporting of
7 Observational Studies in Epidemiology (STROBE) statement: guidelines for reporting
8 observational studies. *Ann Intern Med*. 2007;147(8): 573-577.
- 9 15. Wood K, Buttermann G, Mehbod A, Garvey T, Jhanjee R, Sechriest V. Operative
10 compared with nonoperative treatment of a thoracolumbar burst fracture without neurological
11 deficit. A prospective, randomized study. *J Bone Joint Surg Am*. 2003;85-A(5): 773-781.
- 12 16. Parker JW, Lane JR, Karaikovic EE, Gaines RW. Successful short-segment
13 instrumentation and fusion for thoracolumbar spine fractures: a consecutive 41/2-year series.
14 *Spine (Phila Pa 1976)*. 2000;25(9): 1157-1170.
- 15 17. Ganau M, Syrmos N, Martin AR, Jiang F, Fehlings MG. Intraoperative ultrasound in
16 spine surgery: history, current applications, future developments. *Quant Imaging Med Surg*.
17 2018;8(3): 261-267. <https://doi.org/10.21037/qims.2018.04.02>.
- 18 18. Tezeren G, Kuru I. Posterior fixation of thoracolumbar burst fracture: short-segment
19 pedicle fixation versus long-segment instrumentation. *J Spinal Disord Tech*. 2005;18(6): 485-
20 488.
- 21 19. Dobran M, Nasi D, Brunoizzi D, et al. Treatment of unstable thoracolumbar junction
22 fractures: short-segment pedicle fixation with inclusion of the fracture level versus long-
23 segment instrumentation. *Acta Neurochir (Wien)*. 2016;158(10): 1883-1889.
24 <https://doi.org/10.1007/s00701-016-2907-0>.
- 25 20. Schmoelz W, Schaser KD, Knop C, Blauth M, Disch AC. Extent of corpectomy
26 determines primary stability following isolated anterior reconstruction in a thoracolumbar
27 fracture model. *Clin Biomech (Bristol, Avon)*. 2010;25(1): 16-20.
28 <https://doi.org/10.1016/j.clinbiomech.2009.09.010>.
- 29 21. Liang B, Huang G, Ding L, Kang L, Sha M, Ding Z. Early results of thoraco lumbar
30 burst fracture treatment using selective corpectomy and rectangular cage reconstruction.
31 *Indian J Orthop*. 2017;51(1): 43-48. <https://doi.org/10.4103/0019-5413.197524>.
- 32 22. Lund T, Oxland TR, Jost B, et al. Interbody cage stabilisation in the lumbar spine:
33 biomechanical evaluation of cage design, posterior instrumentation and bone density. *J Bone*
34 *Joint Surg Br*. 1998;80(2): 351-359.
- 35 23. McDonough PW, Davis R, Tribus C, Zdeblick TA. The management of acute
36 thoracolumbar burst fractures with anterior corpectomy and Z-plate fixation. *Spine (Phila Pa*
37 *1976)*. 2004;29(17): 1901-1908; discussion 1909.
- 38 24. Adkins DE, Sandhu FA, Voyadzis JM. Minimally invasive lateral approach to the
39 thoracolumbar junction for corpectomy. *J Clin Neurosci*. 2013;20(9): 1289-1294.
40 <https://doi.org/10.1016/j.jocn.2012.09.051>.
- 41 25. Amaral R, Marchi L, Oliveira L, Coutinho T, Pimenta L. Acute lumbar burst fracture
42 treated by minimally invasive lateral corpectomy. *Case Rep Orthop*. 2013;2013: 953897.
43 <https://doi.org/10.1155/2013/953897>.
- 44 26. Dhall SS, Wadhwa R, Wang MY, Tien-Smith A, Mummaneni PV. Traumatic
45 thoracolumbar spinal injury: an algorithm for minimally invasive surgical management.
46 *Neurosurg Focus*. 2014;37(1): E9. <https://doi.org/10.3171/2014.5.FOCUS14108>.
- 47 27. El Saghir H. Extracoelemic mini approach for anterior reconstructive surgery of the
48 thoracolumbar area. *Neurosurgery*. 2002;51(5 Suppl): S118-122.

- 1 28. Muhlbauer M, Pfisterer W, Eyb R, Knosp E. Minimally invasive retroperitoneal
2 approach for lumbar corpectomy and reconstruction. Technical note. *Neurosurg Focus*.
3 1999;7(6): e4.
- 4 29. Payer M, Sottas C. Mini-open anterior approach for corpectomy in the thoracolumbar
5 spine. *Surg Neurol*. 2008;69(1): 25-31; discussion 31-22.
6 <https://doi.org/10.1016/j.surneu.2007.01.075>.
- 7 30. Smith WD, Dakwar E, Le TV, Christian G, Serrano S, Uribe JS. Minimally invasive
8 surgery for traumatic spinal pathologies: a mini-open, lateral approach in the thoracic and
9 lumbar spine. *Spine (Phila Pa 1976)*. 2010;35(26 Suppl): S338-346.
10 <https://doi.org/10.1097/BRS.0b013e3182023113>.
- 11 31. Kim DH, Jaikumar S, Kam AC. Minimally invasive spine instrumentation.
12 *Neurosurgery*. 2002;51(5 Suppl): S15-25.
- 13 32. Bergey DL, Villavicencio AT, Goldstein T, Regan JJ. Endoscopic lateral transposas
14 approach to the lumbar spine. *Spine (Phila Pa 1976)*. 2004;29(15): 1681-1688.
- 15 33. Ozgur BM, Aryan HE, Pimenta L, Taylor WR. Extreme Lateral Interbody Fusion
16 (XLIF): a novel surgical technique for anterior lumbar interbody fusion. *Spine J*. 2006;6(4):
17 435-443. <https://doi.org/10.1016/j.spinee.2005.08.012>.
- 18 34. Scheufler KM. Technique and clinical results of minimally invasive reconstruction
19 and stabilization of the thoracic and thoracolumbar spine with expandable cages and
20 ventrolateral plate fixation. *Neurosurgery*. 2007;61(4): 798-808; discussion 808-799.
21 <https://doi.org/10.1227/01.NEU.0000298909.01754.C5>.
- 22 35. Cunningham BW, Kotani Y, McNulty PS, et al. Video-assisted thoracoscopic surgery
23 versus open thoracotomy for anterior thoracic spinal fusion. A comparative radiographic,
24 biomechanical, and histologic analysis in a sheep model. *Spine (Phila Pa 1976)*. 1998;23(12):
25 1333-1340.
- 26 36. McAfee PC, Regan JR, Zdeblick T, et al. The incidence of complications in
27 endoscopic anterior thoracolumbar spinal reconstructive surgery. A prospective multicenter
28 study comprising the first 100 consecutive cases. *Spine (Phila Pa 1976)*. 1995;20(14): 1624-
29 1632.
- 30 37. Pham MH, Tuchman A, Chen TC, Acosta FL, Hsieh PC, Liu JC. Transpedicular
31 Corpectomy and Cage Placement in the Treatment of Traumatic Lumbar Burst Fractures. *Clin*
32 *Spine Surg*. 2017;30(8): 360-366. <https://doi.org/10.1097/BSD.0000000000000312>.
- 33 38. Lin RM, Huang KY, Lai KA. Mini-open anterior spine surgery for anterior lumbar
34 diseases. *Eur Spine J*. 2008;17(5): 691-697. <https://doi.org/10.1007/s00586-008-0644-7>.
- 35 39. Rauzzino MJ, Shaffrey CI, Nockels RP, Wiggins GC, Rock J, Wagner J. Anterior
36 lumbar fusion with titanium threaded and mesh interbody cages. *Neurosurg Focus*. 1999;7(6):
37 e7.
- 38 40. Chibbaro S, Cebula H, Todeschi J, et al. Evolution of Prophylaxis Protocols for
39 Venous Thromboembolism in Neurosurgery: Results from a Prospective Comparative Study
40 on Low-Molecular-Weight Heparin, Elastic Stockings, and Intermittent Pneumatic
41 Compression Devices. *World Neurosurg*. 2018;109: e510-e516.
42 <https://doi.org/10.1016/j.wneu.2017.10.012>.
- 43 41. Ganau M, Prisco L, Cebula H, et al. Risk of Deep vein thrombosis in neurosurgery:
44 State of the art on prophylaxis protocols and best clinical practices. *J Clin Neurosci*. 2017;45:
45 60-66. <https://doi.org/10.1016/j.jocn.2017.08.008>.
- 46 42. Sanderson PL, Fraser RD, Hall DJ, Cain CM, Osti OL, Potter GR. Short segment
47 fixation of thoracolumbar burst fractures without fusion. *Eur Spine J*. 1999;8(6):495-500. doi:
48 10.1007/s005860050212.
- 49 43. Wu ZX, Gong FT, Liu L, Ma ZS, Zhang Y, Zhao X, Yang M, Lei W, Sang HX. A
50 comparative study on screw loosening in osteoporotic lumbar spine fusion between

1 expandable and conventional pedicle screws. Arch Orthop Trauma Surg. 2012
2 Apr;132(4):471-6. doi: 10.1007/s00402-011-1439-6.
3 44. Knop C, Fabian HF, Bastian L, Blauth M. Late results of thoracolumbar fractures after
4 posterior instrumentation and transpedicular bone grafting. Spine (Phila Pa 1976). 2001 Jan
5 1;26(1):88-99. doi: 10.1097/00007632-200101010-00016
6
7
8

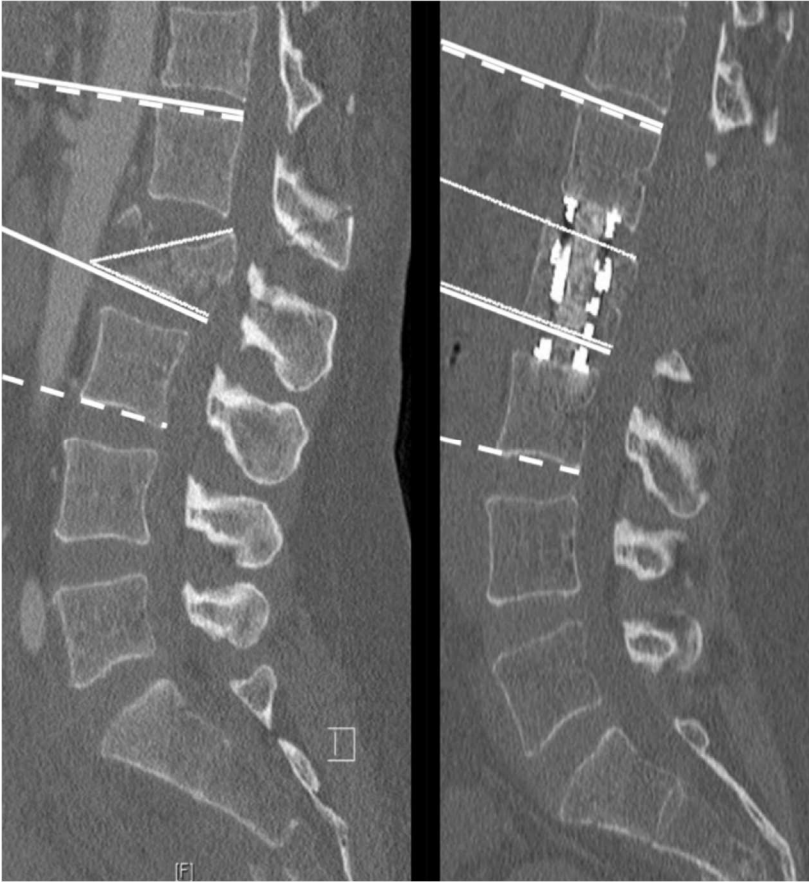

Figure 1. L2 fracture before and at the end of the treatment with the different angle measurements. Dotted line: Angle 1 of kyphotic deformation of the fractured vertebra Dotted line: Cobb Angle 2; Full line: Gardner Angle 3.

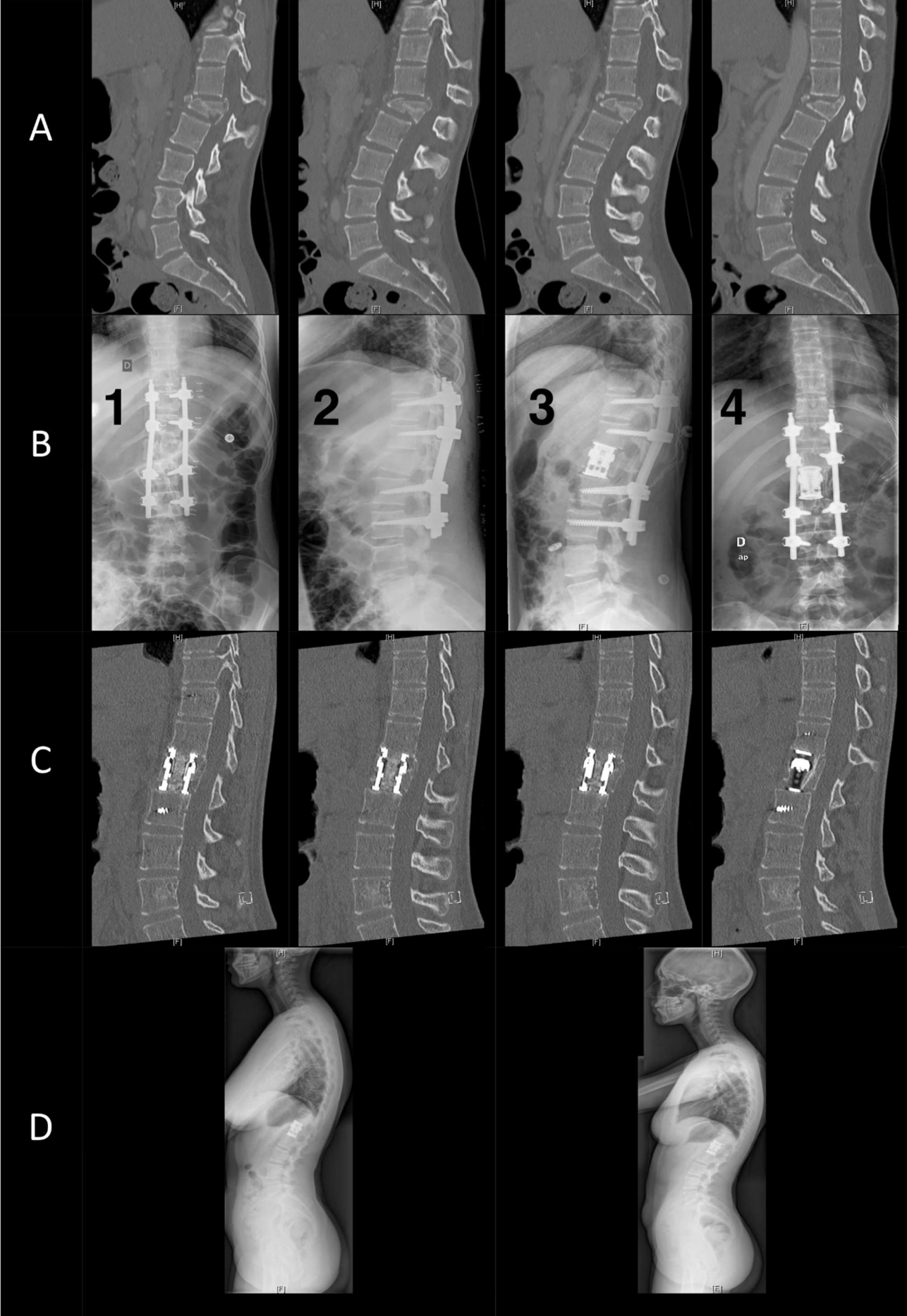


Figure 2. Example of a 3-stage sequential treatment of a post traumatic L1 A4 (AoSpine) fracture in a 25-year-old woman. Images A: sagittal bone CT showing the fracture. Images B: after posterior MIS osteosynthesis (first 2 images) and after previous arthrodesis treatment (last 2 images). C: Sagittal bone scan at 1 year showing absence of pseudarthrosis with complete ossification. D: Sagittal Tele-column after removal of posterior MIS instrumentation after 1 and 2 years showing good stability with a correct sagittal balance without local sagging.

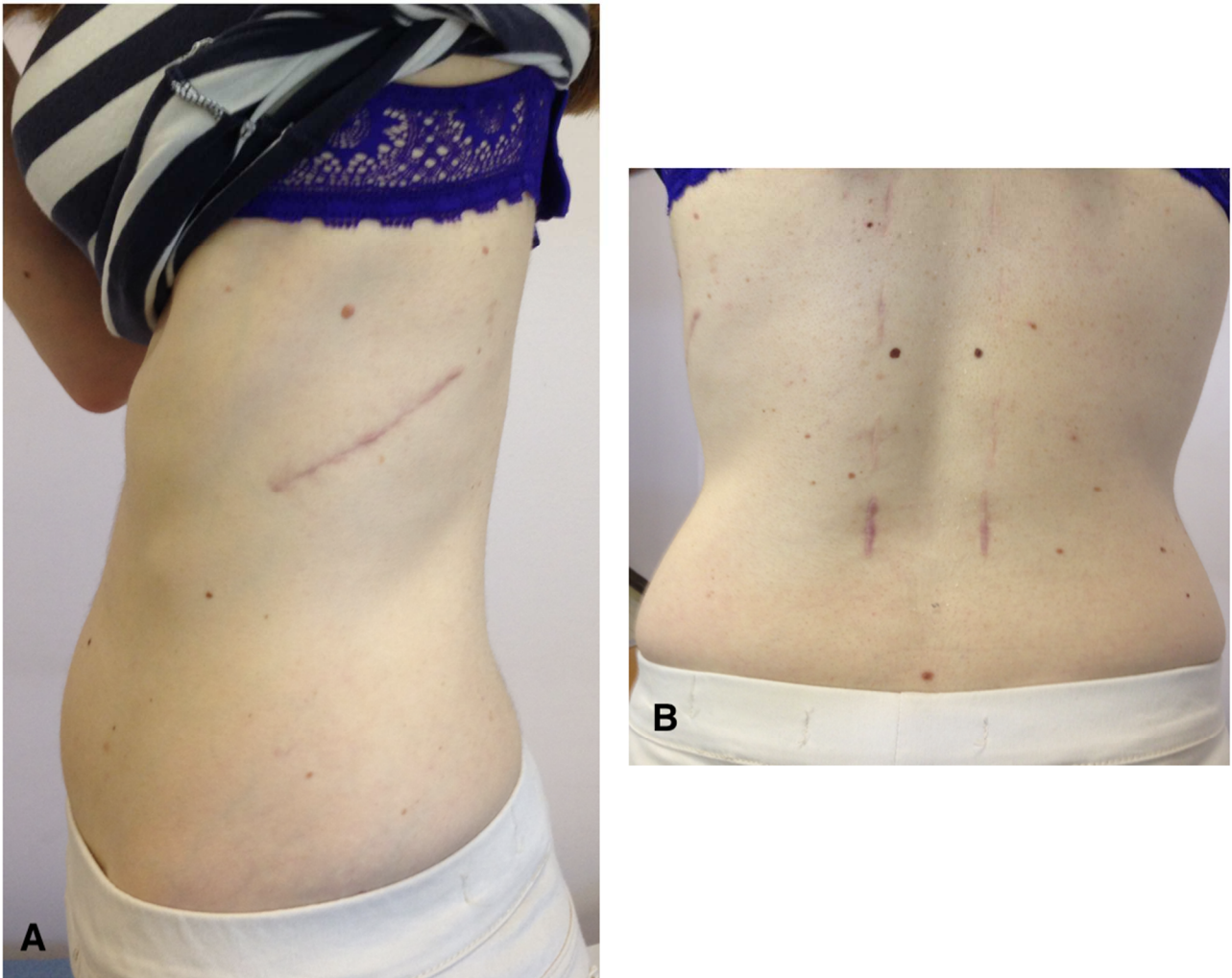


Figure 3. Pictures showing anterior and posterior scars 6 months after surgery.

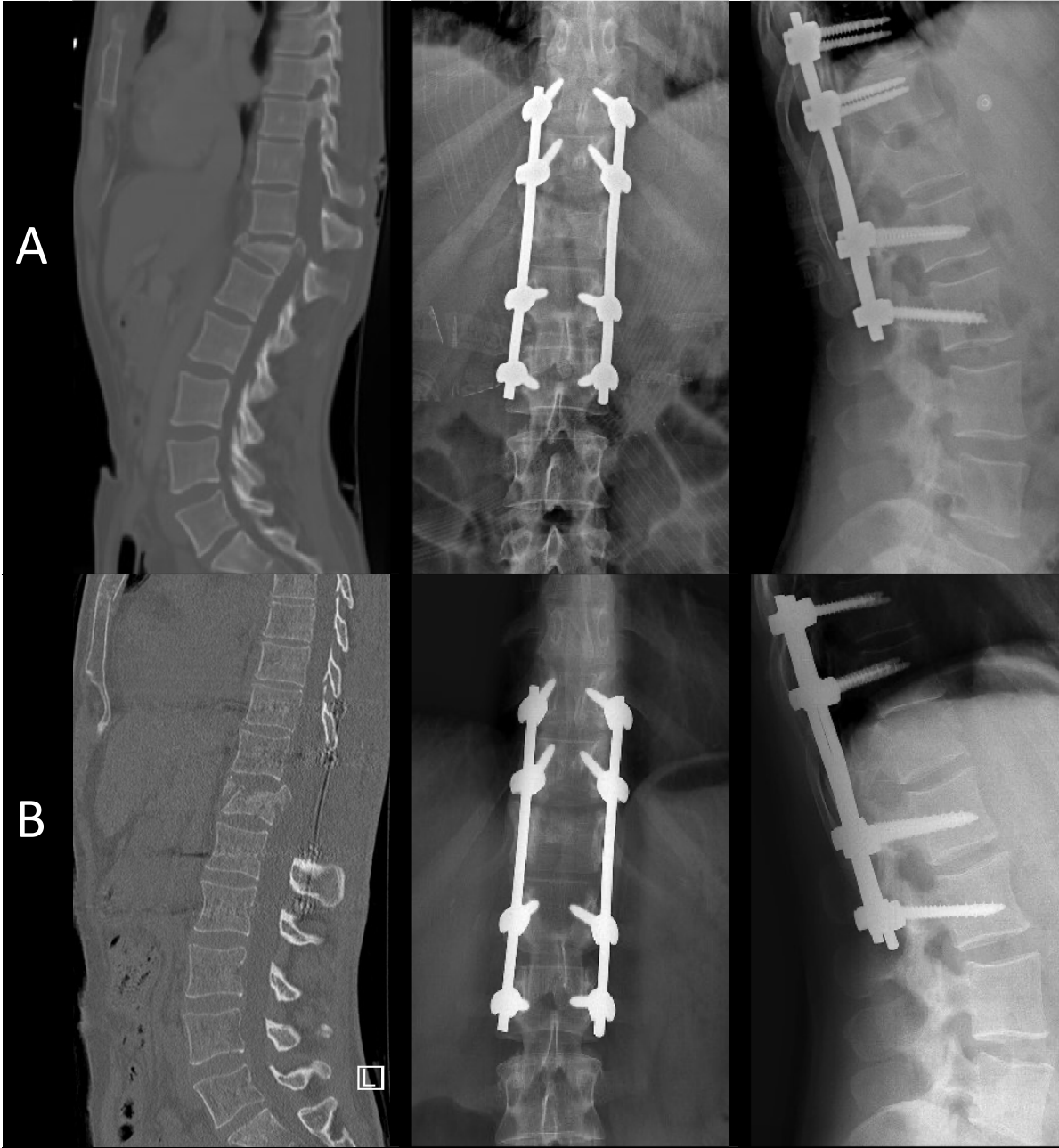


Figure 4 A-B: A) Preoperative sagittal CT scan (left side) showing the fracture, and early postoperative (middle and right side) x-ray check demonstrating a good correction. B) 2 years postoperative sagittal CT scan (left side) and postoperative x-ray check (middle and right side) demonstrating the absence of bony consolidation as well as a slight loss of correction.

		N / %	
		Group A	Group B
Women		32 / 48.5%	20 / 45.5%
Man		34 / 51.5%	24 / 54.5%
median age		42.2±11.3	51.1±14.3
median TLICS		6 ± 1	6 ± 1
median LSS		8 ± 1	8 ± 1
Level	T11	9 / 13,6%	4 / 9,1%
	T12	23 / 34,9 %	18 / 40,9%
	L1	19 / 28,8 %	16 / 36,4%
	L2	15 / 22,7 %	6 / 13,6%
Type	A3	22 / 33,3 %	14 / 31,8%
	A4	44 / 66,7%	30 / 68,2%

Table 1: Characteristic of the population, level and type of fracture

<i>Thoraco-lumbar angles</i>		Pre-op values at time 0	Early Post-op values	Post-op values at 2 years	Δ time 0-2 years	P value	
			Posterior MIS	Anterior ALF			
Group A	1: local kyphotic deformation of the fractured vertebra	20,2°	5,9°	4,0°	4,4°	15,8°	<i>p</i> < 0,0001
	2: Cobb regional	14,5°	9,8°	9,1°	8,7°	5,8°	<i>p</i> = 0,002
	3: Gardner	16,6°	10,8°	9,2°	9,5°	7,1°	<i>p</i> = 0,0005
Group B	1: local kyphotic deformation of the fractured vertebra	19,3°	-	-	3,9	15,4°	<i>p</i> < 0,0001
	2: Cobb regional	14°	-	-	8,5°	5,5°	<i>p</i> = 0,003
	3: Gardner	16,1°	-	-	9,6°	6,5°	<i>p</i> = 0,0003
Difference between the 2 groups				<i>NS</i>			

Table2. Patient series: pre and post-operative radiological angles/correction measurements (Δ: gradient, MIS: minimally invasive surgery; ALF: antero-lateral fusion, NS: not significant).

	Group A	Group B	Z score (P value)
Patients	66	44	-
Smokers	14 (21%)	13 (29%)	0.9949 (0.32218)
Diabetes (Type I and II)	12 (18%)	18 (41%)	-2.622 (0.0088)
BMI > 30	13 (19%)	10 (22%)	-0.3829 (0.70394)
Blood hypertension	9 (14%)	15 (34%)	-2.5447 (0.01108)
Cardiovascular pathologies	2 (3%)	5 (11%)	-1.7541 (0.08012)
Osseointegration	66 (100%)	29 (65%)	5.1042 (0.0001)

Table 3. Prevalence of comorbidities in Groups A and B (significant differences in bold)