Check for updates

Received: 31 March 2022 | Revised: 12 June 2022 | Accepted: 14 June 2022

DOI: 10.1111/codi.16248

SYSTEMATIC REVIEW

Anoplasty for anatomical anal stenosis: systematic review of complications and recurrences

Gaetano Gallo[1] | Arcangelo Picciariello[2] | Gian Luca Di Tanna[3] | Patrizia Pelizzo[4,5] | Donato Francesco Altomare[2] | Mario Trompetto[6] | Giulio Aniello Santoro[4] | Franco Roviello[1] | Carla Felice[5] | Ugo Grossi[4,7]

[1]Unit of General Surgery and Surgical Oncology, Department of Medicine, Surgery and Neurosciences, University of Siena, Siena, Italy

[2]Surgical Unit 'M. Rubino', Department of Emergency and Organ Transplantation, University 'Aldo Moro of Bari', Bari, Italy

[3]Statistics Division, The George Institute for Global Health, University of New South Wales, Sydney, New South Wales, Australia

[4]II Surgery Unit, Regional Hospital Treviso, AULSS2, Treviso, Italy

[5]Department of Medicine – DIMED, University of Padua, Padua, Italy

[6]Department of Colorectal Surgery, S. Rita Clinic, Vercelli, Italy

[7]Department of Surgery, Oncology and Gastroenterology – DISCOG, University of Padua, Padua, Italy

Correspondence
Ugo Grossi, Department of Surgery, Oncology and Gastroenterology - DISCOG, University of Padua, Padua, Italy.
Email: ugo.grossi@unipd.it

Abstract

Aim: The optimal surgical treatment for anatomical anal stenosis (AS) remains to be determined. The aim of this study was to determine the rates of complications and recurrence after anoplasty for anatomical AS and, wherever feasible, compare the outcomes for the various techniques.

Method: A PROSPERO-registered systematic review was reported following the Preferred Reporting Items for Systematic Reviews and Meta-Analyses guidelines. Medline, PubMed, Embase, Cochrane Library of Systematic Review, Scopus and Web of Science were searched for articles published up to May 2021. Studies that assessed the outcomes of anoplasty in adult patients with anatomical AS were selected. The primary outcomes were complications and recurrence. The methodological quality of studies was appraised using the Joanna Briggs Institute critical appraisal tools.

Results: From the total of 2705 unique screened records, 151 were assessed for eligibility. Only 29 studies (two prospective) met the inclusion criteria, reporting data on 556 patients [mean age 53 (18–83) years, 46% female]. Previous history of surgery for haemorrhoidal disease accounted for three quarters of cases. A total of 14 types of anoplasty were found, with the Y–V flap being the most performed technique [27% of cases (n = 149)]. Complications frequently occurred, with a pooled prevalence of 10.2% (95% CI 3.9%–24.1%) after Y–V flap and 11.5% (5.3%–23.0%) after rhomboid/diamond flap. Patients undergoing house flap achieved better results in terms of clinical improvement, satisfaction and quality of life compared with Y–V flap and rhomboid/diamond flap. When considering only studies with at least 12 months of follow-up, the pooled prevalence of recurrence was 4.7% (2.2%–9.8%), with significantly higher rates observed in the prospective versus retrospective series [pooled prevalence 18.9% (11.5%–29.5%) vs. 3.6% (1.7–7.8%), respectively; $p < 0.001$].

Gaetano Gallo and Arcangelo Picciariello contributed equally.

If the manuscript is provisionally accepted, a VIDEO ABSTRACT will be required prior to final acceptance.

This is an open access article under the terms of the Creative Commons Attribution-NonCommercial-NoDerivs License, which permits use and distribution in any medium, provided the original work is properly cited, the use is non-commercial and no modifications or adaptations are made.
© 2022 The Authors. *Colorectal Disease* published by John Wiley & Sons Ltd on behalf of Association of Coloproctology of Great Britain and Ireland.

Conclusion: Both complications and recurrence were significantly lower after house flap compared with rhomboid/diamond and Y–V flap. Better designed multicentre studies with longer follow-up are needed to confirm these findings.

PROSPERO registration number: CRD42021239493.

KEYWORDS

anal stenosis, anal stricture, anoplasty, recurrence, systematic review

INTRODUCTION

Anatomical anal stenosis (AS) is a rare but severe sequela of several surgical procedures targeting the anal canal [1]. This condition may severely affect a patient's quality of life due to difficulty in rectal emptying, altered stool consistency, bleeding, pain and the need for chronic use of laxatives [2].

Excisional haemorrhoidectomy represents the main cause of morphological changes within the anal canal, with anelastic fibrotic tissue replacing the normal soft anodermal tissue, leading to AS in 5%–10% of cases [3–5]. Less frequently, AS may result from surgery for anal fissure and fistula-in-ano, anal trauma, perianal Crohn's disease, tuberculosis, radiotherapy and chronic intake of ergotamine [6]. The common pathophysiological mechanism underlying the development of AS is gradual and irreversible scarring involving the subcutaneous space.

Based on morphology, extension and severity, Milsom and Mazier classified AS into mild, moderate and severe, with symptoms of obstructive defaecation and the impossibility of performing a digital rectal examination [7].

While mild to moderate AS can be managed with conservative strategies including bulking agents, alone or in combination with anal dilation or lateral internal sphincterotomy, surgery still represents the mainstay of treatment for moderate to severe AS refractory to conservative approaches [8]. The surgical management of AS is challenging and includes several procedures with the common goal of increasing the size of the anal canal by restoring the elasticity of affected tissues. The best surgical strategy strictly depends on the level of AS, generally classified as low, middle or high based on the distance from the dentate line [9].

Over the last two decades, several technical variations of anoplasty have been proposed [10]. However, there is no consensus on which is the best surgical option or on validated therapeutic algorithms. The outcomes of several types of anoplasty with or without a sphincterotomy have been retrospectively assessed in relatively small series with limited follow-up.

The aim of this systematic review is to evaluate the rates of complications and recurrence associated with different anoplasty techniques performed to treat AS.

What does this paper add to the literature?

This review provides a comprehensive scrutiny of anoplasty for anatomical anal stenosis. Patients undergoing house flap achieved better results in terms of clinical improvement, satisfaction and quality of life than those with Y–V flap or rhomboid/diamond flap.

METHOD

Protocol registration

The protocol for this review was made a priori and registered with the International Prospective Register of Systematic Reviews (PROSPERO ID, CRD42021239493). This study was reported according to the Preferred Reporting Items for Systematic Reviews and Meta-Analyses 2020 statement [11].

Study characteristics

All published reports of anoplasty (i.e. any surgical procedure aimed to restore the anatomy of the anal canal) for AS to the date of final search (31 May 2021), with at least the abstract in English, were systematically reviewed. Studies were excluded if they reported on patients with only functional AS (e.g. resulting from a hypertonic internal anal sphincter), AS with other abnormalities (e.g. ectropion), nonadults (i.e. under 18 years of age) or those solely undergoing internal anal sphincterotomy or nonsurgical treatments for AS (including injections of agents promoting smooth muscle relaxation). Studies reporting on mixed populations in which data from patients undergoing anoplasty for AS could not be segregated from the whole cohort were also excluded, as well as reviews, guidelines and editorials.

Information sources and study selection

The authors performed a comprehensive search of the literature using Medline (PubMed), Embase, Cochrane Library of Systematic

14631318, 2022, 12, Downloaded from https://onlinelibrary.wiley.com/doi/10.1111/codi.16248 by University Of Siena Sist Bibliot Di Ateneo, Wiley Online Library on [02/12/2024]. See the Terms and Conditions (https://onlinelibrary.wiley.com/terms-and-conditions) on Wiley Online Library for rules of use; OA articles are governed by the applicable Creative Commons License

Review, Web of Science and Scopus and by hand. Search term definitions were inclusive, promoting a sensitive search of studies reporting patients with surgically treated AS (Table S1). Reference lists of all full-text articles were examined for any additional studies.

Data extraction and outcomes

Screening was performed independently at the abstract level by four authors (GG, AP, PP and UG), excluding studies not meeting eligibility criteria where these could be readily determined from the abstract alone. Full-text copies of remaining studies were also independently obtained and assessed by the above authors, who were unblinded to the names of studies, authors, institutions and year of publication. Study characteristics and outcome data were extracted independently onto a Microsoft Excel spreadsheet (Office 365 for Mac, Microsoft Corp.), with disagreements resolved by consensus.

The following data were extracted for each study: first author, year of publication, first author's country, study design and length (in years), number of patients, patient demographics (gender, age, ethnicity), type and duration of symptoms, aetiology of AS, severity and level of the stenosis within the anal canal, perioperative characteristics (e.g. bowel preparation, patient positioning, antibiotic prophylaxis and type of anaesthesia), type of anoplasty, complications, last follow-up, recurrence and information for assessment of the risk of bias. Although the primary outcome was originally defined as success (i.e. anatomical and/or clinical resolution of AS) at the time of registration on PROSPERO, this was reconsidered due to the unavailability of data and replaced by the rates of complications and recurrence (within the study follow-up time frame).

Qualitative assessment of studies was performed using the Joanna Briggs Institute (JBI) Critical Appraisal Checklist for Case Reports and Case Series [12]. The JBI critical appraisal tools have been developed by the JBI and collaborators and approved by the JBI Scientific Committee following extensive peer review. Although designed for use in systematic reviews, the JBI critical appraisal tools can also be used when creating critically appraised topics, in journal clubs and as an educational tool [12]. Of the 10 question items included in this tool some relate to risk of bias while others relate to ensuring adequate reporting and statistical analysis. A response of 'no' to any of the questions has a negative impact on the quality of a case report or series.

Statistical analysis

Meta-analyses of proportions for the primary outcomes were performed using a random effects model to pool prevalence specifying a binomial distribution to model the within-study variability, with 95% CIs calculated by the Wilson method. Heterogeneity was assessed by a formal test of homogeneity and by the proportion of variability across studies attributable to heterogeneity rather than chance (I^2). Meta-analyses were performed using the metaprop_one command in Stata 16 (StataCorp LLC).

RESULTS

Study selection

From the total of 3223 records identified, 2705 were screened after duplicates were removed. Of these, 2550 (94.3%) were excluded (Figure 1) for the following reasons: out of scope (n = 2,282), nonadult population (n = 235), nonsurgical treatments for AS (n = 29), abstract not in English (n = 3), superseded series (n = 1). Of the 155 reports sought for retrieval, 4 (2.6%) could not be retrieved, thus leaving 151 reports assessed for eligibility. Reasons for exclusion after full-text review were: out of scope articles (n = 46); reviews (n = 19); studies with nonextractable data (n = 17); studies reporting on nonsurgical treatment for AS (n = 14); non-English articles (n = 12); book chapters (n = 9); studies reporting on a nonadult population (n = 3); editorials (n = 2).

Overall, 29 studies met the inclusion criteria reporting data on 556 patients. There were nine reports of single cases and 20 case series (Table 1). Of the latter, only two were prospective, both from Egypt [2, 13]. Study length was reported in 17 out of 21 case series and varied between 30 months and 20 years (median, 5 years).

Demographic and clinical characteristics

Age was reported in 22 (75.9%) studies in a total of 428 (77.0%) patients. Mean age was 53.2 years (SD 13.4 years), ranging from 18 to 83 years. Twenty six (89.7%) studies reported patient gender for a total of 444 (79.9%) subjects, of whom 206 (46.4%) were female.

Clinical presentation was described in 24 (82.8%) studies. Difficult and painful defaecation occurred in isolation or coexisted with bleeding in all cases. In four studies [14–17], patients also complained of faecal incontinence.

Aetiology of AS

All studies except one [18] described the aetiology of AS in a total of 548 (98.6%) patients. Previous history of surgery for haemorrhoidal disease accounted for three quarters of cases. The prevalence of AS was higher after Whitehead than Milligan–Morgan haemorrhoidectomy. Although rarer, it also occurred after haemorrhoidopexy [15] or sclerotherapy [19]. Apart from treatment of chronic fissure and abscess or fistula-in-ano, several further causes—each accounting for less than 1% of cases—were reported, including trauma, surgery for neoplasia (e.g. anorectal cancer, Bowen's disease. Paget's disease), congenital anomalies, rectal prolapse, previous irradiation, involutional senile stenosis and inflammatory bowel disease.

14631318, 2022, 12, Downloaded from https://onlinelibrary.wiley.com/doi/10.1111/codi.16248 by University Of Siena Sist Bibliot Di Ateneo, Wiley Online Library on [02/12/2024]. See the Terms and Conditions (https://onlinelibrary.wiley.com/terms-and-conditions) on Wiley Online Library for rules of use; OA articles are governed by the applicable Creative Commons License

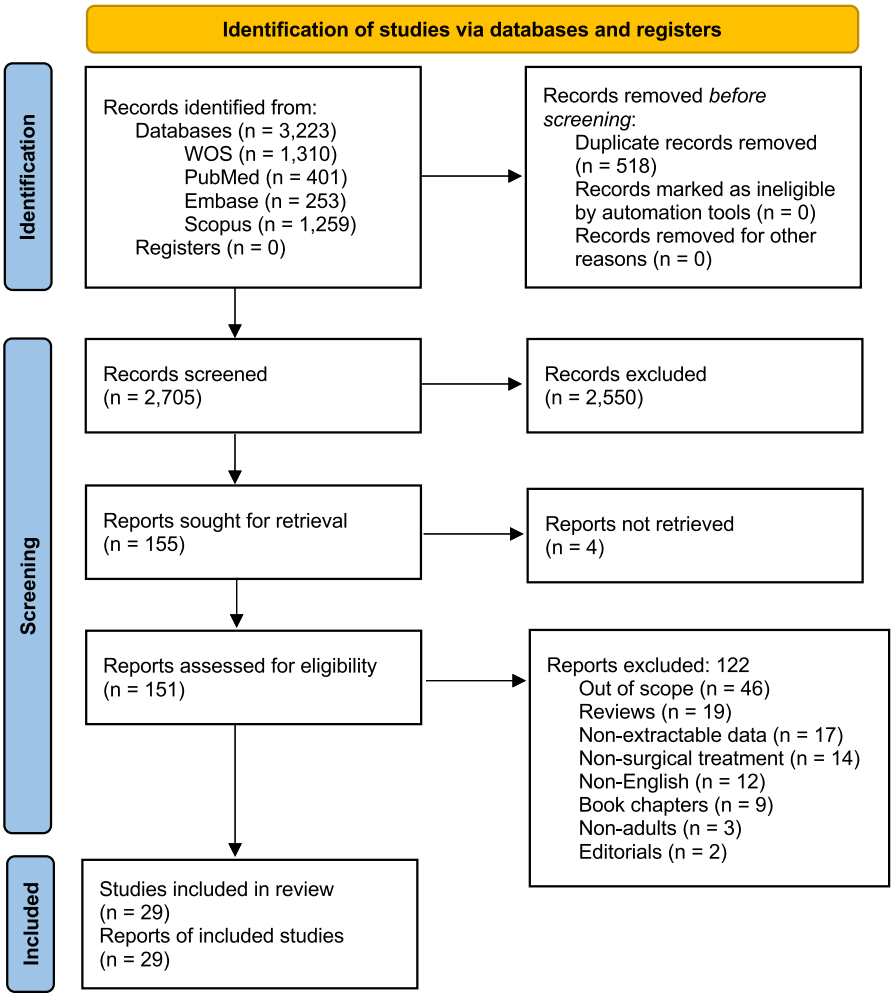

FIGURE 1 PRISMA 2020 flow diagram for new systematic reviews

Perioperative management (Table 2)

Bowel preparation

Details on bowel preparation were reported in 13 studies on 242 (43.5%) patients. This was full mechanical preparation in eight studies [20–27], consisting of one or two rectal enemas in four studies [2, 13, 15, 28], and variable in one study (i.e. full only for planned bilateral flap) [18].

Patient positioning

Patient positioning was described in 18 studies, for a total of 314 (56.5%) patients. Lithotomy was the most popular, with 258 (82.2%) patients; 48 (15.3%) patients were operated on in the prone jack-knife position. Either position was described in one study on eight patients [18].

Antibiotic prophylaxis

A total of 14 studies on 250 (45.0%) patients provided details on antibiotic prophylaxis. Apart from one study [25], this was routinely given either peri- or postoperatively for 4–5 days, with cephalosporins and metronidazole being the most popularly prescribed medications.

Types of anaesthesia

Sixteen studies on 390 (70.1%) patients described the type of anaesthesia, which was general in five studies (n = 47 patients) [20, 26–29], spinal in four studies (n = 36 patients) [13, 24, 25, 30], local with or without conscious sedation in two studies (n = 96 patients) [21, 31], and either general or spinal in five studies (i.e. mixed patient population; n = 211 patients) [2, 4, 7, 15, 18].

Type of anoplasty

All studies reported on a single type of anoplasty, except for six comparing the outcomes of two [7, 23, 25, 32] or three techniques [2, 14]. A total of 14 anoplasties were found, with the Y–V flap being the most performed technique accounting for 26.8% (n = 149) of cases from 10 series (Figure 2) [2, 14, 17, 19, 23, 25, 28, 30, 32, 33]. Apart from the study by Gülen et al. [26], the terms 'rhomboid' and

14631318, 2022, 12, Downloaded from https://onlinelibrary.wiley.com/doi/10.1111/codi.16248 by University Of Siena Sist Bibliot Di Ateneo, Wiley Online Library on [02/12/2024]. See the Terms and Conditions (https://onlinelibrary.wiley.com/terms-and-conditions) on Wiley Online Library for rules of use; OA articles are governed by the applicable Creative Commons License

TABLE 1 Study characteristics

First author	Year	Country	Design	N	Female (%)	Age (years)[a]	Type of flap	Study length (years)	Follow-up(months)
Oh [20]	1982	USA	RCS	12	50	50	C-plasty	5	12
Milsom [7]	1986	USA	RCS	28[b]	NR	NR	V–Y, Rectal advancement	4	9.3
Oh [21]	1992	USA	CR	1[b]	NR	NR	S-plasty	NA	3
Neelakandan [30]	1996	India	RCS	2	0	41.5	Y–V	NR	39
Saldana [22]	1996	USA	CR	1	0	80	Internal pudendal flap	NA	1
Maria [23]	1998	Italy	RCS	42	31	63	Y–V, Diamond	6	24
Sakai [24]	1999	Japan	CR	1	0	52	Prepuce flap	NR	0.5
Mentes [33]	2001	Turkey	CR	1	0	43	Y–V	NR	NR
Rakhmanine [31]	2002	USA	RCS	95	58	68	Rectal advancement	19	50
Filingeri [28]	2006	Italy	RCS	7	43	46.1	Y–V	3	12
Casadesus [25]	2007	Cuba	RCS	19[b]	35	34–68	Y–V, Rectal advancement	5	12
Alver [18]	2008	Turkey	RCS	8[b]	NR	52.1	House	4	26.4
Selvaggio [32]	2009	Italy	RCS	75	NR	NR	Y–V, house	17	NR
Duieb [14]	2010	Australia	RCS	11	27	66	Mixed[c]	3	15.9
Farid [2]	2010	Egypt	PCS	60	28	34	Mixed[d]	7	12
Thin [16]	2011	UK	CR	1	0	74	House	NA	24
Tsuchiya [37]	2011	Japan	RCS	3	0	55	Gluteal fold	3	12
Szeto [29]	2012	USA	CR	1	0	21	Full-thickness skin graft	NA	18
Singh [19]	2014	India	RCS	2	100	NR	Y–V	NR	6
Gülen [26]	2016	Turkey	RCS	18	33	39	Diamond	2.5	12
Okumura [36]	2017	Japan	CR	1	0	NR	V–Y	NA	12
Sloane [27]	2017	Australia	RCS	9	67	60.1	Rhomboid	12	12
Tahamtan [17]	2017	Iran	RCS	25	60	48.2	Y–V	5	9
Asfar [4]	2018	Kuwait	RCS	65	18	45.6	Anal advancement	20	60
Handaya [38]	2019	Indonesia	RCS	2	0	NR	S-plasty	NR	12
Klimasauskiene [34]	2020	Lithuania	CR	1	100	71	House	NA	1
Acar [35]	2020	Switzerland	CR	1	0	57	House	NA	6
Shehata [13]	2020	Egypt	PCS	14	71	43.7	Diamond	3	12
Gallo [15]	2020	Italy	RCS	50	54	57.9	Rhomboid	15	97

Abbreviations: CR, case report; NA, not applicable; NR, not reported; PCS, prospective case series; RCS, retrospective case series.

[a]Mean, median or range variably reported across studies.

[b]Subgroup of patients who underwent anoplasty for anal stenosis.

[c]Y–V, diamond, transverse closure.

[d]Y–V, house, rhomboid.

14631318, 2022, 12, Downloaded from https://onlinelibrary.wiley.com/doi/10.1111/codi.16248 by University Of Siena Sisi Bibliot Di Ateneo, Wiley Online Library on [02/12/2024]. See the Terms and Conditions (https://onlinelibrary.wiley.com/terms-and-conditions) on Wiley Online Library for rules of use; OA articles are governed by the applicable Creative Commons License

TABLE 2 Peri-operative management of patients undergoing anoplasty for anal stenosis

Bowel preparation	Patient positioning	Antibiotic prophylaxis	Type of anaesthesia
Full mechanical [20–27] One or two rectal enemas [2, 13, 15, 28] Variable[a] [18]	Lithotomy [2, 4, 13, 15, 20–24, 27, 37] Prone jack-knife [25, 26, 28, 29, 34, 38] Variable[b] [18]	Peri- or postoperative for 4–5 days [2, 4, 13, 15, 18, 20–22, 27–29, 35, 38] None [25]	General [20, 26–29] Spinal [13, 24, 25, 30] Local [21, 31] Variable[c] [2, 4, 7, 15, 18]

[a]Full only in case of bilateral flap.

[b]Lithotomy or jack-knife.

[c]General or spinal.

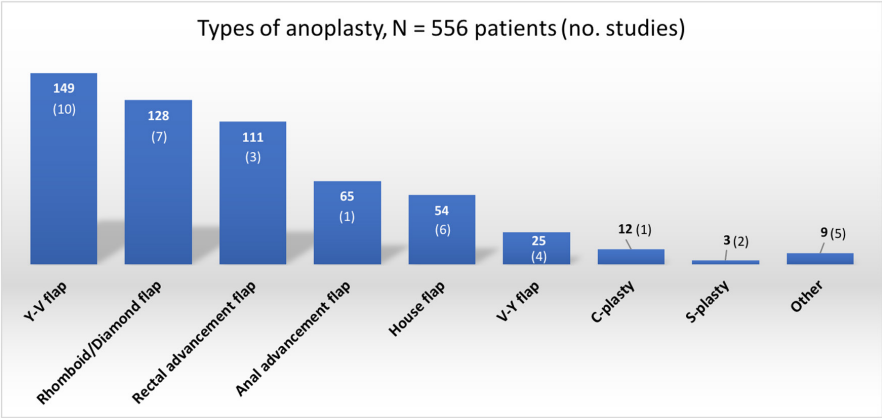

FIGURE 2 Types of anoplasty. The group 'other' included gluteal fold flap ($n = 3$), transverse closure ($n = 3$), internal pudendal flap ($n = 1$), prepuce flap ($n = 1$) and full-thickness skin graft ($n = 1$)

'diamond' referred to an identical flap shape [2, 13–15, 23, 27]. While several studies reported the outcomes of the house flap for AS [2, 16, 18, 32, 34, 35], a smaller number described those of a rectal advancement flap [7, 25, 31], anal advancement flap [4], V–Y flap [7, 36] or C-plasty [20]. Eight studies reported early experience with more technically demanding operations, but these were limited to one to three cases [4, 14, 21, 22, 24, 29, 37, 38].

Flaps were typically fixed with interrupted 3/0 or 4/0 polyglactin subcuticular sutures and 2/0 or 3/0 monofilament skin sutures. In some series [15, 18, 26, 31, 32], bilateral flaps were fashioned whenever the obtained calibre of the anal canal after a unilateral anoplasty was deemed unsatisfactory.

In three series [22, 23, 27], the use of anal dilators was recommended postoperatively for 2–3 weeks when the stenotic process had still not reached the fibrotic stage.

Outcomes

Comparative studies showed that patients undergoing a house flap achieved better results in terms of clinical improvement, satisfaction and quality of life compared with Y–V flap [2, 32] and rhomboid/diamond flap [32]. No substantial differences were found between Y–V flaps and rhomboid/diamond [23] or rectal advancement flap [25].

Complications [e.g. wound dehiscence, bleeding, abscess, pain, urinary retention and transient minor (i.e. gas or soiling) incontinence] frequently occurred, with a pooled prevalence of 10.2% (95% CI 3.9%–24.1%) after Y–V flap ($n = 10$ studies [2, 14, 17, 19, 23, 25, 28, 30, 32, 33]; $I^2 = 51.15\%$) and 11.5% (5.3%–23.0%) after rhomboid/diamond flap ($n = 6$ studies [2, 13, 15, 23, 26, 27]; $I^2 = 53.77\%$). Meta-analysis of proportions of complications could not be performed for the other techniques due to limited data (Farid et al. [2] reported a 5% complication rate after house flap).

With a median follow-up of 12 months (interquartile range 9.2–21.0 months), the recurrence rates ranged widely between 0% and 20%. When considering only studies with at least 12 months of follow-up, the pooled prevalence was 4.7% (2.2%–9.8%; $I^2 = 36.64\%$), with significantly higher rates observed in the two prospective series [2, 13] compared with retrospective series [4, 14, 15, 18, 20, 23, 25–28, 30, 31, 37, 38] [pooled prevalence 18.9% (11.5%–29.5%) vs. 3.6% (1.7%–7.8%), respectively; $p < 0.001$].

Qualitative assessment

Clarity of inclusion criteria, methods of assessment and outcome reporting were satisfactorily detailed in more than 70% of the case series (Figure 3), as opposed to completeness (35%). Recruitment was consecutive in almost two thirds of studies. However, AS was

14631318, 2022, 12, Downloaded from https://onlinelibrary.wiley.com/doi/10.1111/codi.16248 by University Of Siena Sist Bibliot Di Ateneo, Wiley Online Library on [02/12/2024]. See the Terms and Conditions (https://onlinelibrary.wiley.com/terms-and-conditions) on Wiley Online Library for rules of use; OA articles are governed by the applicable Creative Commons License

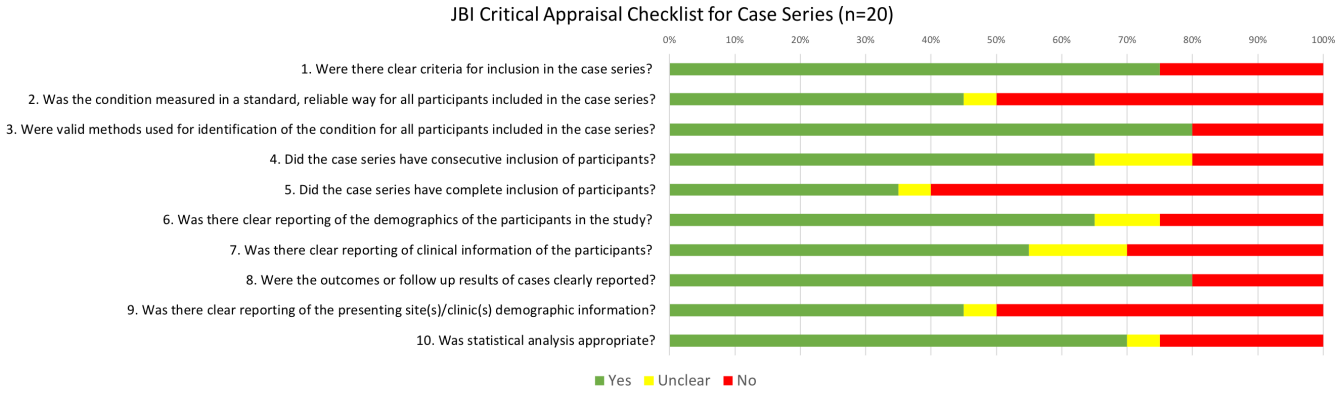

FIGURE 3 Joanna Briggs Institute critical appraisal checklist for case series

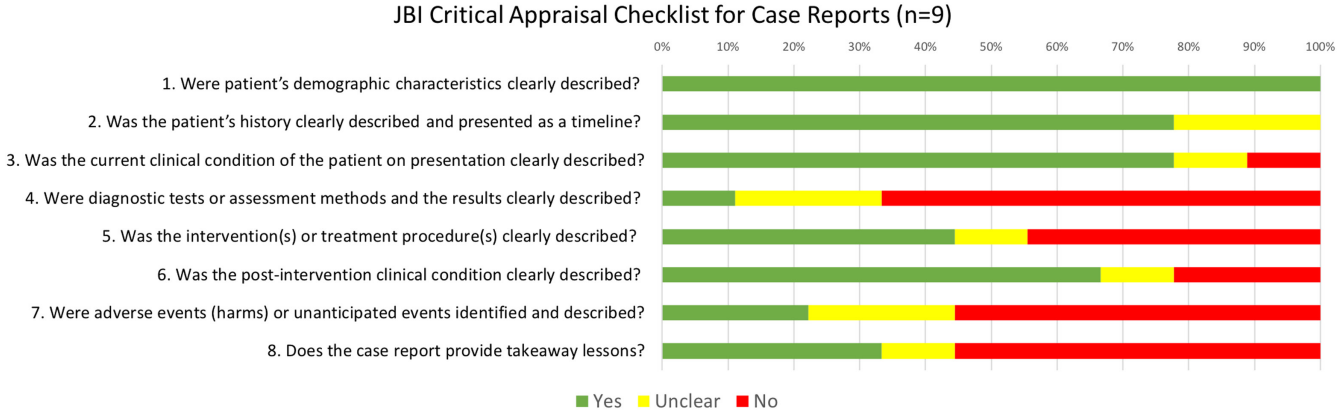

FIGURE 4 Joanna Briggs Institute critical appraisal checklist for case reports

measured in a standard, reliable way in only 45% of series (i.e. using a classification system). Within the case reports, patient demographics, history and clinical condition were adequately described. On the other hand, the lack of a clear description of assessment methods, adverse events and takeaway lessons represented the main flaws (Figure 4).

DISCUSSION AND CONCLUSION

This systematic review showed that several surgical options exist for the management of anatomical AS. Despite the pooled rate of complications being nonnegligible (affecting about 10% of patients in studies reporting on two popular techniques), these seldom led to reintervention. The recurrence rate was significantly higher in prospective than retrospective series, reaching almost one in five patients 12 months postoperatively. Both complications and recurrence were significantly lower after house flap compared with rhomboid/diamond and Y–V flap.

Although an attempt to summarize the therapeutic strategies and discuss the pros and cons of each technique was made by other authors [9, 10, 39–41] these were in the form of narrative reviews and, as such, they lacked a rigorous methodological approach.

Nevertheless, it must be acknowledged that the relative lack of high-quality studies has undoubtably resulted in a degree of selection bias. Apart from two studies, all data retrieved from our search were retrospective and heterogeneity of reporting limited full description of patients and characteristics of AS. The low rate of completeness of the included case series limits their reliability. The confusing and interchangeable terminology (e.g. rhomboid/diamond) was a challenge to making comparisons between studies.

Our results confirm the key role played by previous history of surgery for haemorrhoidal disease in the aetiopathogenesis of AS, also supported by the demographic characteristics of the overall population, with well-balanced gender distribution (47% female) and a mean age of 53 years. Indeed, previous studies showed that peak prevalence of (and surgery for) haemorrhoidal disease occurs in middle age in both sexes [42, 43].

With regards to perioperative management, preoperative rectal enemas replaced full mechanical bowel preparation in most recent series, in line with current clinical practice guidelines [44]. Despite existing evidence of nonimproved outcomes with its use after haemorrhoidectomy and perianal abscess surgery [45, 46], antibiotic prophylaxis was adopted up to 5 days after anoplasty in most series. Two previous studies have shown that oral antibiotic prophylaxis significantly reduced dermatological surgical site infection [47, 48].

14631318, 2022, 12, Downloaded from https://onlinelibrary.wiley.com/doi/10.1111/codi.16248 by University Of Siena Sist Bibliot Di Ateneo, Wiley Online Library on [02/12/2024]. See the Terms and Conditions (https://onlinelibrary.wiley.com/terms-and-conditions) on Wiley Online Library for rules of use; OA articles are governed by the applicable Creative Commons License

Patient positioning is determined by surgeon preference and/or the orientation of the pathology within the anal canal. Given the horizontally oriented operative field in most cases (i.e. Y–V, rhomboid/diamond or house flap), the former reason has probably represented the main driver for the choice.

Spinal anaesthesia was an alternative to general anaesthesia in some series. Various factors (e.g. patient choice, fear of the alternative technique, stress/anxiety) have been identified as the main drivers for a patient's choice of short-acting local anaesthesia or general anaesthesia [49]. As previously claimed [50], an ever more rapid recovery is nowadays influenced by the need to preserve health resources while facing the Covid-19 pandemic.

With the caveat of a longer operating time, better outcomes in terms of clinical improvement, patient satisfaction and quality of life were observed after house flap compared with rhomboid/diamond and Y–V flaps. The longer full-thickness section of anoderm achieved with the former technique may somehow explain this finding. As suggested by Christensen et al. [51], who first advocated its use in the treatment of AS, the house pedicle flap provides both a broad skin flap for the entire length of the involved anal canal and primary closure of the donor site in addition to avoidance of extensive mobilization of tissue, maintenance of a good blood supply with minimal tension and absence of a small tip prone to necrosis [2].

Despite further several variants of anoplasty, no conclusions can be drawn on the superiority of one technique over another. Furthermore, some of these operations (often technically demanding and burdened by prolonged postoperative stay) have become unpopular or been abandoned [18, 23]. Multicentre studies are needed given the rarity of the condition. Indeed, several published experiences took more than one decade to recruit fewer than 100 patients [4, 15, 31, 32].

The decision whether to perform a bilateral flap remains equally controversial and left to the intraoperative judgement of the surgeon based on the anal calibre achieved after a unilateral flap. In this context, only a few studies described a more objective and standardized method of assessment of the anal calibre than that proposed by Milsom and Mazier [7], and used it as an outcome measure [2, 15, 26].

In addition to those mentioned above, there are further limitations to acknowledge. First, meta-analysis was only method to offer early insights and give the opportunity to highlight heterogeneity across studies. Additionally, it was only possible to pool crude data from studies despite the attempts to contact corresponding authors. Pooling data by an individual patient data meta-analysis was not feasible as originally planned due to the observed heterogeneity across studies. Indeed, the CIs were very wide for all outcomes, indicating little knowledge about the effect. However, besides providing a first summary of the poor available evidence, the pooling will also offer food for thought for comparisons with primary studies and future meta-analyses.

However, despite these drawbacks, our review provides a comprehensive scrutiny of anoplasty for anatomical AS, paving the way to better designed studies with longer follow-up aiming at confirming the superiority of one technique over another. Several unmet needs should be addressed to achieve this goal, including the development of a standardized terminology and an agreed core outcome set. Moreover, this systematic review suggests the need for a more cohesive way to design, conduct and report studies on this topic.

AUTHOR CONTRIBUTION

Study conception and design: GG, AP, GLDT. Data acquisition: GG, AP, PP, UG. Statistical analysis: GLDT. Drafting of manuscript: UG, MT, DFA, FR, CF, GAS. Data analysis and interpretation, critical revision and final approval of the manuscript: all authors.

FUNDING INFORMATION

None.

ACKNOWLEDGEMENT

Open Access Funding provided by Universita degli Studi di Padova within the CRUI-CARE Agreement.

CONFLICT OF INTEREST

The authors have no conflicts of interest to declare.

ETHICS STATEMENT

Not required.

INFORMED CONSENT

Not required.

DATA AVAILABILITY STATEMENT

The data that support the findings of this study are available from the corresponding author upon reasonable request.

ORCID

Gaetano Gallo https://orcid.org/0000-0003-1066-4671
Arcangelo Picciariello https://orcid.org/0000-0002-6361-1111
Gian Luca Di Tanna https://orcid.org/0000-0002-5470-3567
Patrizia Pelizzo https://orcid.org/0000-0002-7839-0761
Donato Francesco Altomare https://orcid.org/0000-0001-8980-2752
Mario Trompetto https://orcid.org/0000-0002-1190-4692
Giulio Aniello Santoro https://orcid.org/0000-0002-0086-3522
Franco Roviello https://orcid.org/0000-0003-4122-1259
Carla Felice https://orcid.org/0000-0001-6646-6231
Ugo Grossi https://orcid.org/0000-0001-5372-2873

REFERENCES

1. Khubchandani IT. Anal stenosis. Surg Clin North Am. 1994;74(6):1353–60.
2. Farid M, Youssef M, El Nakeeb A, Fikry A, El Awady S, Morshed M. Comparative study of the house advancement flap, rhomboid flap, and Y–V anoplasty in treatment of anal stenosis: a prospective randomized study. Dis Colon Rectum. 2010;53(5):790–7.
3. Eu KW, Teoh TA, Seow-Choen F, Goh HS. Anal stricture following haemorrhoidectomy: early diagnosis and treatment. Aust N Z J Surg. 1995;65(2):101–3.

14631318, 2022, 12, Downloaded from https://onlinelibrary.wiley.com/doi/10.1111/codi.16248 by University Of Siena Sist Bibliot Di Ateneo, Wiley Online Library on [02/12/2024]. See the Terms and Conditions (https://onlinelibrary.wiley.com/terms-and-conditions) on Wiley Online Library for rules of use; OA articles are governed by the applicable Creative Commons License

4. Asfar S. Anoplasty for post-hemorrhoidectomy low anal stenosis: a new technique. World J Surg. 2018;42(9):3015–20.
5. Wolff BG, Culp CE. The Whitehead hemorrhoidectomy. An unjustly maligned procedure. Dis Colon Rectum. 1988;31(8):587–90.
6. Sayfan J. Ergotamine-induced anorectal strictures: report of five cases. Dis Colon Rectum. 2002;45(2):271–2.
7. Milsom JW, Mazier WP. Classification and management of postsurgical anal stenosis. Surg Gynecol Obstet. 1986;163(1):60–4.
8. Pearl RK, Hooks VH III, Abcarian H, Orsay CP, Nelson RL. Island flap anoplasty for the treatment of anal stricture and mucosal ectropion. Dis Colon Rectum. 1990;33(7):581–3.
9. Shawki S, Costedio M. Anal fissure and stenosis. Gastroenterol Clin North Am. 2013;42(4):729–58.
10. Brisinda G, Vanella S, Cadeddu F, Marniga G, Mazzeo P, Brandara F, et al. Surgical treatment of anal stenosis. World J Gastroenterol. 2009;15(16):1921–8.
11. Page MJ, McKenzie JE, Bossuyt PM, Boutron I, Hoffmann TC, Mulrow CD, et al. The PRISMA 2020 statement: an updated guideline for reporting systematic reviews. BMJ. 2021;372:n71.
12. Aromataris E, Munn Z, editors. JBI Manual for Evidence Synthesis. JBI 2020 2020. Available from: https://synthesismanual.jbi.global
13. Shehata M. Surgical management of iatrogenic anal stenosis. Egypt J Surg. 2020;39(3):774–9.
14. Duieb Z, Appu S, Hung K, Nguyen H. Anal stenosis: use of an algorithm to provide a tension-free anoplasty. ANZ J Surg. 2010;80(5):337–40.
15. Gallo G, Stratta E, Realis Luc A, Clerico G, Trompetto M. A tailored rhomboid mucocutaneous advancement flap to treat anal stenosis. Colorectal Dis. 2020;22(10):1388–95.
16. Thin NN, Carrington EV, Grimmer K, Knowles CH. Advancement anoplasty and sacral nerve stimulation: an effective combination for radiation-induced anal stenosis. Int J Colorectal Dis. 2011;26(2):211–3.
17. Tahamtan M, Ghahramani L, Khazraei H, Tabar YT, Bananzadeh A, Hosseini SV, et al. Surgical management of anal stenosis: anoplasty with or without sphincterotomy. J Coloproctol. 2017;37(1):13–7.
18. Alver O, Ersoy YE, Aydemir I, Erguney S, Teksoz S, Apaydin B, et al. Use of "house" advancement flap in anorectal diseases. World J Surg. 2008;32(10):2281–6.
19. Singh S, Shah I, Sharma A, Watali Y, Masoodi O, Rayees S. Anal stenosis following sclerotherapy managed by anoplasty. JK Sci. 2013;15(4):211–2.
20. Oh C, Zinberg J. Anoplasty for anal stricture. Dis Colon Rectum. 1982;25(8):809–10.
21. Oh C, Albanese C. S-plasty for various anal lesions. Am J Surg. 1992;163(6):606–8.
22. Saldana E, Paletta C, Gupta N, Vernava AM, Longo WE. Internal pudendal flap anoplasty for severe anal stenosis. Report of a case. Dis Colon Rectum. 1996;39(3):350–2.
23. Maria G, Brisinda G, Civello IM. Anoplasty for the treatment of anal stenosis. Am J Surg. 1998;175(2):158–60.
24. Sakai S, Yoshinaga R. The prepuce flap in the reconstruction of male anal stenosis. Br J Plast Surg. 1999;52(8):660–2.
25. Casadesus D, Villasana LE, Diaz H, Chavez M, Sanchez IM, Martinez PP, et al. Treatment of anal stenosis: a 5-year review. ANZ J Surg. 2007;77(7):557–9.
26. Gulen M, Leventoglu S, Ege B, Mentes BB. Surgical treatment of anal stenosis with diamond flap anoplasty performed in a calibrated fashion. Dis Colon Rectum. 2016;59(3):230–5.
27. Sloane JA, Zahid A, Young CJ. Rhomboid-shaped advancement flap anoplasty to treat anal stenosis. Tech Coloproctol. 2017;21(2):159–61.
28. Filingeri V, Gravante G, Cassisa D. Radiofrequency Y–V anoplasty in the treatment of anal stenosis. Eur Rev Med Pharmacol Sci. 2006;10(5):263–7.
29. Szeto P, Ambe R, Tehrani A, Cagir B. Full-thickness skin graft anoplasty: novel procedure. Dis Colon Rectum. 2012;55(1):109–12.
30. Neelakandan B. Double Y–V plasty for postsurgical anal stricture. Br J Surg. 1996;83(11):1599.
31. Rakhmanine M, Rosen L, Khubchandani I, Stasik J, Riether RD. Lateral mucosal advancement anoplasty for anal stricture. Br J Surg. 2002;89(11):1423–4.
32. Selvaggio I, Cadeddu F, Grande M, Milito G. Surgical management of anal stenosis. BMC Geriatr. 2009;9(1):A40.
33. Mentes BB, Yavuzer R, Cavusoglu T, Isik AF, Tatlicioglu E, Ferahkose Z. Surgical treatment of anal stenosis following perineal shotgun injury. Plast Reconstr Surg. 2001;107(3):891–3.
34. Klimasauskiene V, Dulskas A, Samalavicius NE. House advancement flap anoplasty for severe post-haemorrhoidectomy anal stenosis – a video vignette. Colorectal Dis. 2020;22(9):1207–8.
35. Acar T, Acar N, Tosun F, Ayaroglu C, Haciyanli M. House advancement flap anoplasty for severe post-hemorrhoidectomy anal stenosis. Tech Coloproctol. 2020;24(3):261–2.
36. Okumura K, Kubota T, Nishida K, Lefor AK, Mizokami K. Treatment of complete anal stricture after diverting colostomy for Fournier's gangrene. Case Rep Surg. 2017;2017:2062157. https://doi.org/10.1155/2017/2062157
37. Tsuchiya S, Sakuraba M, Asano T, Miyamoto S, Saito N, Kimata Y. New application of the gluteal-fold flap for the treatment of anorectal stricture. Int J Colorectal Dis. 2011;26(5):653–9.
38. Handaya Y, Sunardi M. Bilateral rotational S flap technique for preventing restenosis in patients with severe circular anal stenosis: a review of 2 cases. Ann Coloproctol. 2019;35(4):221–4.
39. Katdare MV, Ricciardi R. Anal stenosis. Surg Clin North Am. 2010;90(1):137–45.
40. Lagares-Garcia JA, Nogueras JJ. Anal stenosis and mucosal ectropion. Surg Clin North Am. 2002;82(6):1225–31. vii.
41. Liberman H, Thorson AG. How I do it. Anal stenosis. Am J Surg. 2000;179(4):325–9.
42. Lohsiriwat V. Hemorrhoids: from basic pathophysiology to clinical management. World J Gastroenterol. 2012;18(17):2009–17.
43. Lee KC, Chen HH, Chung KC, Hu WH, Chang CL, Lin SE, et al. Meta-analysis of randomized controlled trials comparing outcomes for stapled hemorrhoidopexy versus LigaSure hemorrhoidectomy for symptomatic hemorrhoids in adults. Int J Surg. 2013;11(9):914–8.
44. Carmichael JC, Keller DS, Baldini G, Bordeianou L, Weiss E, Lee L, et al. Clinical practice guidelines for enhanced recovery after colon and Rectal surgery from the American Society of Colon and Rectal Surgeons and Society of American Gastrointestinal and Endoscopic Surgeons. Dis Colon Rectum. 2017;60(8):761–84.
45. Khan KI, Akmal M, Waqas A, Mahmood S. Role of prophylactic antibiotics in Milligan Morgan hemorrhoidectomy – a randomized control trial. Int J Surg. 2014;12(8):868–71.
46. Sozener U, Gedik E, Kessaf Aslar A, Ergun H, Halil Elhan A, Memikoglu O, et al. Does adjuvant antibiotic treatment after drainage of anorectal abscess prevent development of anal fistulas? A randomized, placebo-controlled, double-blind, multicenter study. Dis Colon Rectum. 2011;54(8):923–9.
47. Amland PF, Andenaes K, Samdal F, Lingaas E, Sandsmark M, Abyholm F, et al. A prospective, double-blind, placebo-controlled trial of a single dose of azithromycin on postoperative wound infections in plastic surgery. Plast Reconstr Surg. 1995;96(6):1378–83.
48. Saleh K, Sonesson A, Persson B, Riesbeck K, Schmidtchen A. A descriptive study of bacterial load of full-thickness surgical wounds in dermatologic surgery. Dermatol Surg. 2011;37(7):1014–22.
49. Capdevila X, Aveline C, Delaunay L, Bouaziz H, Zetlaoui P, Choquet O, et al. Factors determining the choice of spinal versus general anesthesia in patients undergoing ambulatory surgery: results of a multicenter observational study. Adv Ther. 2020;37(1):527–40.
50. Gallo G, Sturiale A, De Simone V, Di Tanna GL, Giani I, Grossi U, et al. A worldwide survey on proctological practice during COVID-19 lockdown (ProctoLock 2020): a cross-sectional analysis. Colorectal Dis. 2021;23(1):246–64.

14631318, 2022, 12, Downloaded from https://onlinelibrary.wiley.com/doi/10.1111/codi.16248 by University Of Siena Sist Bibliot Di Ateneo, Wiley Online Library on [02/12/2024]. See the Terms and Conditions (https://onlinelibrary.wiley.com/terms-and-conditions) on Wiley Online Library for rules of use; OA articles are governed by the applicable Creative Commons License

51. Christensen MA, Pitsch RM Jr, Cali RL, Blatchford GJ, Thorson AG. 'House' advancement pedicle flap for anal stenosis. Dis Colon Rectum. 1992;35(2):201–3.

SUPPORTING INFORMATION

Additional supporting information can be found online in the Supporting Information section at the end of this article.

How to cite this article: Gallo G, Picciariello A, Di Tanna GL, Pelizzo P, Altomare DF & Trompetto M et al. Anoplasty for anatomical anal stenosis: systematic review of complications and recurrences. Colorectal Dis. 2022;24:1462–1471. https://doi.org/10.1111/codi.16248

14631318, 2022, 12, Downloaded from https://onlinelibrary.wiley.com/doi/10.1111/codi.16248 by University Of Siena Sist Bibliot Di Ateneo, Wiley Online Library on [02/12/2024]. See the Terms and Conditions (https://onlinelibrary.wiley.com/terms-and-conditions) on Wiley Online Library for rules of use; OA articles are governed by the applicable Creative Commons License