



UNIVERSITÀ  
DI SIENA  
1240

**DEPARTMENT OF MEDICAL BIOTECHNOLOGIES**

*DOCTORATE in GENETICS, ONCOLOGY and CLINICAL MEDICINE (GenOMeC)  
XXXV Cycle*

## **Proactive sinecatechins for the treatment of cutaneous HPV related lesions**

GenOMeC PhD project

**Coordinator**

**Prof. Alessandra Renieri**

**Tutor**

**Prof. Pietro Rubegni**

**PhD Student**

**Dr. Marco Campoli**

**Session 2021/2022**



## Index

Chapter 1 – Human PapillomaVirus.....	pag.6
1.1 Introduction.....	6
1.2 History and evolution.....	7
1.3 Classification.....	9
1.4 Virion and genomic structure.....	10
1.5 HPV and cancer.....	13
1.6 Productive infection and life cycle of HPV.....	15
1.7 Non-productive infection and transformation.....	23
1.8 Clinical features.....	24
1.8.1 Skin infections.....	25
1.8.2 Genital and airway infections.....	27
1.9 General concepts of therapy.....	32
1.10 Vaccine.....	32
Chapter 2 – External genital warts.....	pag.34
2.1 Introduction.....	34
2.2 Epidemiology.....	34
2.3 Transmission.....	36
2.4 Clinical manifestations.....	37
2.4.1 Clinical aspects.....	37
2.4.2 Localization.....	40
2.4.3 Associated symptoms.....	40

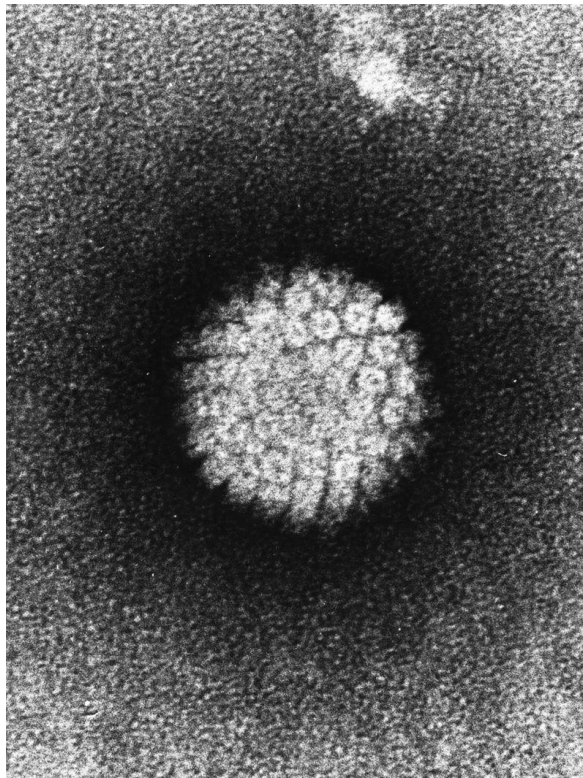
2.4.4 Incubation.....	40
2.5 Diagnosis.....	40
2.6 Patient classification.....	41
2.7 Therapy.....	42
2.7.1 Objectives of treatment.....	42
2.7.2 Treatments.....	43
2.8 Follow up.....	50
2.9 Counseling.....	50
2.10 Management of sexual partners.....	51
Chapter 3 – Clinical study.....	pag.52
3.1 Preliminary considerations.....	52
3.2 Proactive sequential therapy.....	52
3.3 Aim of the study.....	54
3.4 Materials and methods.....	55
3.4.1 Study project.....	55
3.4.2 Subjects.....	55
3.4.3 Endpoints.....	59
3.4.4 Statistic analysis.....	60
3.5 Results.....	60
3.6 Discussion.....	66
3.7 Conclusion.....	69
Bibliography.....	pag. 70



## Chapter 1- Human PapillomaVirus

### 1.1 Introduction

Human papillomavirus (HPV) (Fig.1) is a double-stranded deoxyribonucleic acid (DNA) virus with exclusive tropism for multilayered epithelial tissues of skin and mucous membranes; its involvement in the development of some neoplasms is known, in particular cervical cancer, other anogenital tumors, but also other oral and nasal cavity carcinomas and rare periungual carcinomas linked to specific HPV infections.



*Figure 1 HPV, electronic microscope – Wikipedia*

## 1.2 History and evolution

Papillomaviruses were first identified as viral particles in 1949<sup>1</sup>. Although the infectious origin of animal and human warts had been established since 1890, no other group of viruses has experienced such explosive recognition of distinct types and variations in pathogenicity in recent years. In 1976 and 1977, the considerable heterogeneity of HPV<sup>2-4</sup> types was evident.

Even if these facets suggest a remarkable biological plasticity and a rapid development of HPV mutational adaptations, the most recent evidence points in another direction. Specific isolates from non-human primates are related to specific human genotypes (eg, pygmy chimpanzee papillomavirus and HPV 13 or rhesus monkey papillomavirus and HPV 16). Obviously, the divergence of many human pathogenic genotypes took place in the early prehomimid period; thus, papillomaviruses along with herpesviruses, adenoviruses, and polyomaviruses and probably others, developed long before the appearance of humans. Indeed, these viruses represent fascinating tools for studying the evolutionary aspects of pre-hominid family trees and early hominid migration patterns<sup>5</sup>. Papillomaviruses have also been found in reptiles (turtles), birds and many mammals. Therefore, the heterogeneity of this group (Fig.2) reflects not so much the rapid acquisition of genome modifications, but rather an ancient history of virus adaptations to specific host cells and host-mediated control of these infections. Studies

have established a theoretical framework for evolution of papillomaviruses, suggesting a model based on an ancient intrahost viral divergence on a niche adaptation followed by a virus-host codivergence (Fig.3)<sup>6</sup>.

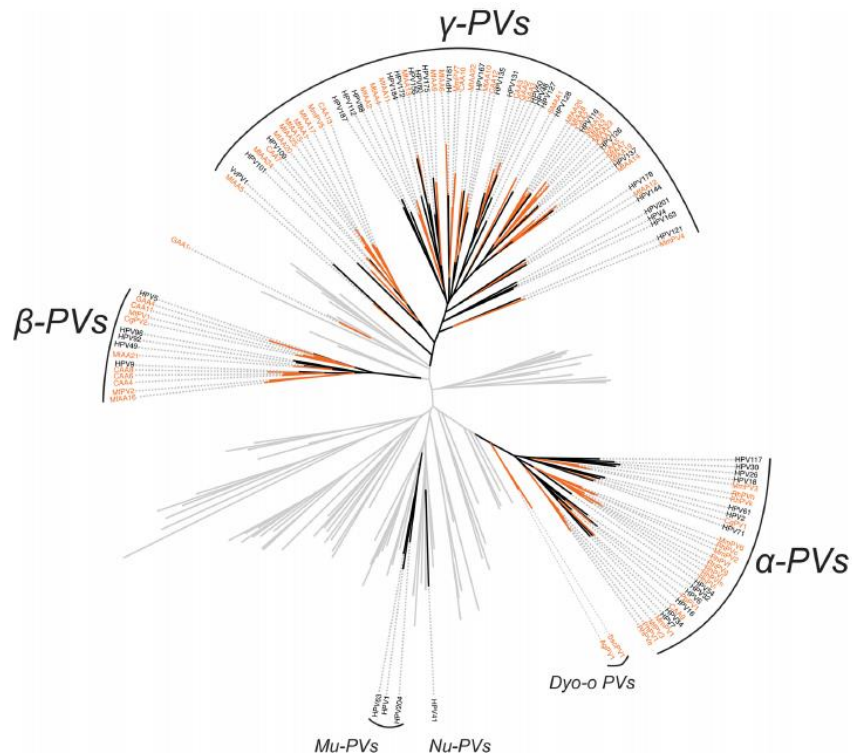


Figure 2 Primate papillomavirus phylogeny. Chen, Z. et al. Non-human Primate Papillomaviruses Share Similar Evolutionary Histories and Niche Adaptation as the Human Counterparts. *Front. Microbiol.* 10, (2019).

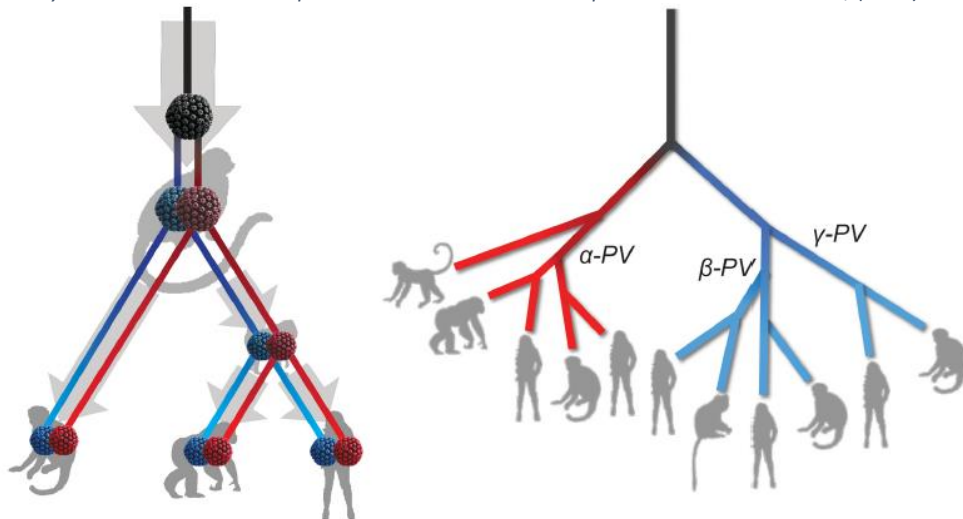


Figure 3 Schematic model of ancient intrahost viral divergence followed by virus-host codivergence in primate papillomaviruses. Chen, Z. et al. Non-human Primate Papillomaviruses Share Similar Evolutionary Histories and Niche Adaptation as the Human Counterparts. *Front. Microbiol.* 10, (2019).



A causal relationship with a common form of cancer, cervical carcinoma, had not been considered until 1974<sup>7,8</sup> although members of this virus group were known to be carcinogenic in rabbits<sup>9</sup> and capable of inducing malignant transformation of some rodent cells<sup>10</sup>. Paradigmatic were the observations made by the Italian physician Rigoni-Stem, published in 1842 in Rome, based on the high prevalence of cervical cancer in prostitutes and its virtual absence in nuns.

### 1.3 Classification

HPVs are members of a distinct family of viruses, the Papillomaviridae. The family Papillomaviridae is divided into 39 genera<sup>11-13</sup>, based on L1 sequence equality of 60% or greater, with each genus designated by a letter of the Greek alphabet. Papillomaviruses within a genus that share 60–70% L1 sequence equality are termed species<sup>11-13</sup>. Furthermore, within a species, papillomaviruses with L1 sequence equality of 71–89% are considered a type<sup>11,12</sup>. As of 2016, 205 different HPV types have been identified, which have been classified into five genera including: 65 Alphapapillomaviruses, 51 Betapapillomaviruses, 84 Gammapapillomaviruses, 4 Mupapillomaviruses and a single Nupapillomavirus (Table 1)<sup>14</sup>. At least 19 additional types have been identified, however these viruses are currently awaiting classification. HPVs with L1 sequence equality of 90-98% are termed subtypes, and those with L1 sequence equality greater than 98% are considered variants<sup>11,13</sup>. Arguably, HPVs in the alpha genus are of the greatest

medical importance as they are associated with oral and mucosal cancers, as well as cancers of the anogenital tract.

Genus	Species	Representative HPV types	Tropism	Associated Diseases
Alpha-PV	$\alpha 1$	32	mucosal	Heck's disease
	$\alpha 2$	3, 10, 28	cutaneous	flat warts
	$\alpha 4$	2, 27, 57	cutaneous	common warts
	$\alpha 7$	18, 39, 45, 59, 68	mucosal	intraepithelial neoplasia, invasive carcinoma
	$\alpha 9$	16, 31, 33, 35, 52, 58	mucosal	intraepithelial neoplasia, invasive carcinoma
	$\alpha 10$	6, 11	mucosal	condylomata acuminata
		13		Heck's disease
Beta-PV	$\beta 1c$	5, 8, 12, 14, 19, 20, 21, 24, 25, 36, 47	cutaneous	Epidermodysplasia verruciformis
	$\beta 2$	9, 15, 17, 22, 23, 37, 38	cutaneous	Epidermodysplasia verruciformis
	$\beta 3$	49	cutaneous	Epidermodysplasia verruciformis
Gamma-PV	$\gamma 1$	4, 65	cutaneous	Warts
	$\gamma 4$	60	cutaneous	Warts
Mu-PV	$\mu 1$	1	cutaneous	plantar warts
	$\mu 2$	63	cutaneous	Warts
Nu-PV	v	41	cutaneous	Warts

Table 1: This table summarizes information on the main HPV genotypes, their tropism and associated diseases. Heck's disease, also known as focal epithelial hyperplasia (FEH), is a rare benign mucosal neoplasm that is strongly associated with HPV infection. Harden, M. E. & Munger, K. Human papillomavirus molecular biology. *Mutat. Res. Mutat. Res.* 772, 3–12 (2017).

#### 1.4 Virion and genomic structure

HPVs are non-enveloped DNA viruses with a tropism for squamous epithelia. Each viral particle consists of an icosahedral capsid of about 60 nm in diameter, containing a single double-stranded circular DNA molecule of about 8,000 base pairs<sup>15</sup>. Only one strand of the double-stranded DNA genome is used as a template for transcription and this coding strand contains three genomic regions, including about ten open reading frames (ORFs) (Fig.4).

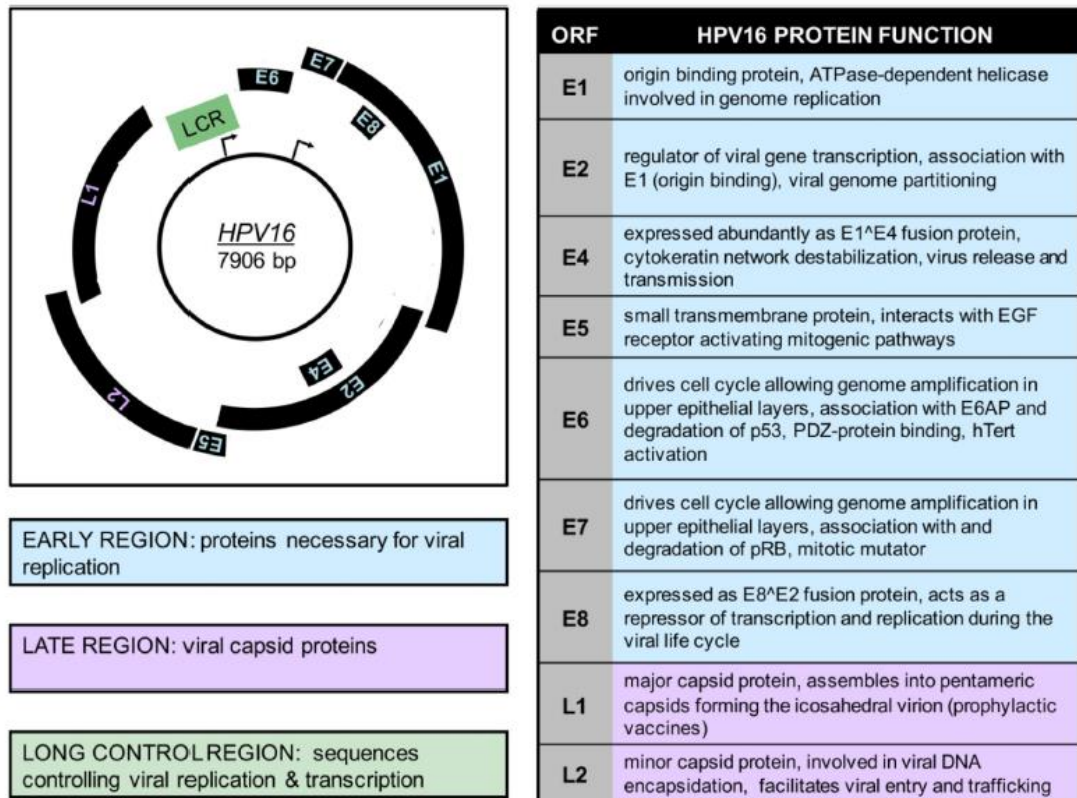


Figure 4 HPV16 genome organization and protein function: The HPV16 genomic map of 7906 base pairs is shown on the left. Only the coding strand is included and transcription occurs clockwise. The early promoter (P97) is indicated by an arrow at the approximate location of the RNA start site in the LCR control region. The late promoter (P670) is also indicated by an arrow at its initiation site in ORF E7. The initial region is represented in blue and contains proteins required for viral replication including E1, E2, E3, E4, E5, E6 and E7. The late region is shown in purple and contains the viral capsid proteins L1 and L2. The LCR is shown in green and contains sequences that control viral replication and transcription. On the right, a table of HPV16 ORFs and a brief description of their corresponding viral functions is shown. Harden, M. E. & Munger, K. Human papillomavirus molecular biology. *Mutat. Res. Mutat. Res.* 772, 3–12 (2017)

Many viral proteins are expressed by polycistronic messenger ribonucleic acids (mRNA)<sup>16,17</sup>. The early region (E) contains up to seven ORFs encoding viral regulatory proteins and the late region (L) encodes two viral capsid proteins. Each ORF in the early region is designated "E" followed by a number, indicative of the length of the ORF. The third region of the genome was defined as the long control region (LCR), upstream regulatory region (URR), or noncoding region (NCR). This

genomic region contains the origin of DNA replication as well as transcriptional control sequences<sup>15</sup>.

Early ORFs include E1, E2, E4, E5, E6, E7, and E8<sup>17,18</sup> (Fig.4):

- E1 encodes a viral adenosine triphosphate (ATP)-dependent DNA helicase<sup>19</sup> that can bind to the adenine-thymine-rich origin of replication and the function of E2 proteins in viral transcription, replication and genome partitioning;
- Integral E2 encodes for a transcriptional activator. Conversely, a truncated form of E2 transcribed from an internal ATG sequence and the E8-E2 fusion repress transcription<sup>20</sup>;
- E4 is incorporated into the E2 gene and is mainly expressed as an E1-E4 fusion protein during the last stages of the viral life cycle. E4 binds to cytokeratin filaments, disrupting their structure, and is thought to play a role in viral release from the cornified epithelial layers<sup>21</sup>;
- E5 is a small transmembrane protein, which has been best studied in bovine papillomavirus type 1 (BPV1). BPV1 E5 is an oncogenic, hydrophobic, single-step transmembrane protein that forms dimers and interacts with, and activates, certain receptors, including epidermal growth factor (EGF) and platelet-derived growth factor (PDGF) receptors. Similar properties have also been attributed to HPV E5, which encodes polytopic transmembrane proteins that share only limited sequence similarity with BPV1

- E5<sup>22</sup>. HPV E5 proteins have also been reported to play a role in apoptosis and immune evasion<sup>22</sup>;
- E6 and E7 both drive cell cycle entry to enable genome amplification in the upper epithelial layers. High-risk (HR) HPV E6 proteins have oncogenic activity. They bind and degrade p53, as well as cellular PDZ proteins, and activate telomerase<sup>23</sup>. HR HPV E7 proteins bind to and degrade retinoblastoma tumor suppressor (pRB), and contribute to malignant progression by inducing genomic instability<sup>24,25</sup>;
  - the late region codes for the major (L1) and minor (L2) capsid proteins. Since ORF L1 is the most conserved in papillomaviruses, it is used for the phylogenetic organization and classification of HPVs. In particular, L1 spontaneously assembles into virus-like particles, a condition that is the basis for currently available prophylactic vaccine formulations<sup>26</sup>.

### 1.5 HPV and cancer

The first HPVs associated with cancer were beta HPVs 5 and 8. They have been detected in warts and tumors arising in patients with a rare genetic disorder, epidermodysplasia verruciformis (EV)<sup>27,28</sup>. Most of these patients carry mutations in one of two EVER genes, EVER1 and EVER2 (also called TMC6 and TMC8, respectively), located on chromosome 17q25.3<sup>29</sup>. Although the molecular basis remains largely unknown, patients with EV cannot effectively clear beta HPV infections and develop

warts all over their bodies. These warts can progress malignantly in sun-exposed areas of the body. Beta HPVs also contribute to non-melanoma skin cancers (NMSCs) which occur as a frequent complication in long-term immunosuppressed organ transplant patients. Of note, HPV sequences are not detected in every tumor cell, suggesting that these viruses may contribute to tumor induction, but may not be required for transformation maintenance. Studies with transgenic mice have shown that E6, E7 and E2 have oncogenic activity.

The approximately 40 alpha HPVs that infect mucosal epithelia are classified as low-risk (LR) or HR based on their clinical association with warts or generally benign lesions that have a propensity for malignant progression. LR HPVs, such as HPV 6 and 11, cause genital warts or oral focal epithelial hyperplasia (Heck's disease) depending on the site of infection. HR HPVs, such as HPV 16 and 18, cause intraepithelial neoplasms, which can progress to invasive carcinomas. HR HPVs are the causative agents of approximately 5.2% of all human cancers worldwide, and HR HPV-associated cervical cancer is the fourth most common cancer among women worldwide<sup>30-32</sup>. Nearly all cervical cancers are caused by HR HPV, and HPV 16 and 18 are detected in up to 70% of all cervical cancers<sup>33</sup>. HR HPV infections are also found in 95% of anal cancers, 70% of oropharyngeal cancers<sup>34</sup>, 60% of vaginal cancers, 50% of vulvar cancers, and 35% of penile cancers<sup>35</sup>. HPV 16 is by far the most common

HPV type detected in these cancers. HPV-associated tumors generally represent nonproductive infections.

### 1.6 Productive infection and life cycle of HPV

A hallmark of the HPV life cycle is its close association with the differentiation program of the infected host's squamous epithelium. HPVs first infect undifferentiated basal epithelial cells and then the viral progeny is produced in differentiated daughter cells in the upper epithelial layers (Fig.5)<sup>36</sup>.

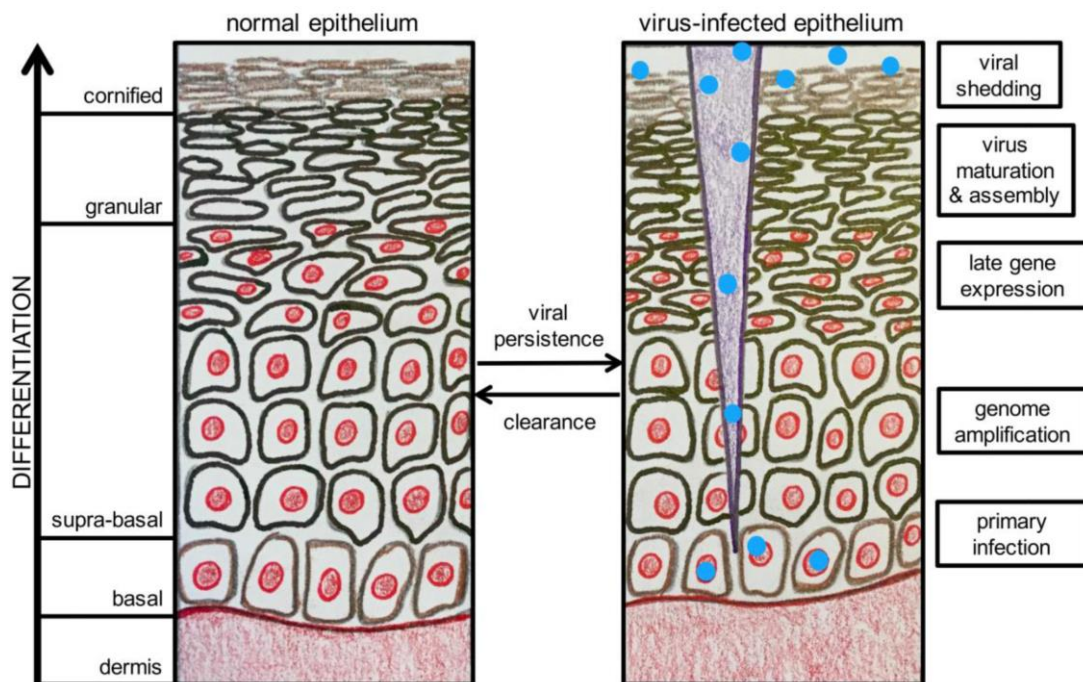


Figure 5 HPV life cycle in differentiating squamous epithelium: illustration of normal squamous epithelium is at left. On the right, a brief description of the HPV life cycle is shown. Harden, M. E. & Munger, K. Human papillomavirus molecular biology. *Mutat. Res. Mutat. Res.* 772, 3–12 (2017).

- Methods for studying the life cycle of the virus

Historically, it has been difficult to study the human papillomavirus life cycle in laboratory. Organotypic cultures, in which epithelial cells are

grown on a fibroblast-containing matrix at the liquid-air interface where they form a layered skin-like structure, have provided the breakthrough needed to recapitulate the entire viral life cycle and produce infectious HPV in cultures<sup>37,38</sup>. Virus-like particles (VLPs) are produced by ectopic expression of L1 alone or in combination with L2 in mammalian cells. Pseudoviruses are VLPs that contain viral genomes or reporter plasmids and can be produced in a similar way. Given their relative ease of production, VLPs and pseudoviruses have been the primary tools used to study HPV structure, assembly, entry, and infectivity. Due to the selectivity of papillomavirus species, it was not possible to use an animal model that could closely represent HPV infection and disease in humans. In 2010, a new papillomavirus (MmuPV) was identified in the common house mouse (*Mus musculus*), allowing for the first time studies of papillomaviruses in laboratory mice<sup>39</sup>. MmuPV infection of mice resembles human cutaneous HPV infection, and information gleaned from studies of laboratory mouse MmuPV infections may be helpful in better understanding human HPV-associated pathogenesis.

- Infection

The only cells capable of undergoing cell division in the squamous epithelium are the basal cells. As a result, papillomaviruses must specifically infect these cells to establish persistent infection. For an HPV infection to be persistently maintained, epithelial stem cells in the basal layer must be infected<sup>40,41</sup>. However, since the basal epithelial cells are



physiologically protected by different layers of differentiated cells, they are not easily accessible and the virus can infect these cells through micro-injuries that expose the lower epithelial layers<sup>15</sup>. Furthermore, cells located in the squamocolumnar junction in the cervix and anus have been shown to be particularly vulnerable to HPV infection<sup>42</sup>.

- Virus attack and entry

Virions initially bind to heparan sulfate proteoglycans (HSPGs), which serve as primary receptors on basement cells or basement membrane exposed by trauma or permeabilization<sup>43</sup>. The initial attachment of L1 to HSPGs induces conformational changes in the virus capsid, with consequent loss of affinity for the primary receptor and transfer of the virus to a not yet sufficiently characterized entry receptor. Eventually, the amino-terminal portion of L2 is exposed, rendering L2 susceptible to cleavage by furin-related protease, which is required for infection with some HPVs<sup>44-46</sup>. Internalization of capsids from the cell surface is asynchronous and can take two to four hours, with some capsids remaining on the surface much longer than others. The capsids on the surface are propelled by direct movement from the filopodia to the cell body via the retrograde flow of actin<sup>47,48</sup>. There can be a gap of 1-3 days between cell surface binding and transcription of the viral genome<sup>49,50</sup>. However, if infected cells are close to mitosis, entry into the nucleus and detection of viral gene expression can also occur soon after infection<sup>51</sup>.

The virus is endocytosed through a peculiar mechanism, similar to macropinocytosis, which is independent of clathrin, caveolin and lipid raft<sup>52</sup>. The virions are then transported through the endosomal system where they undergo further structural changes resulting in partial denudation<sup>53</sup>. During viral denudation into acidified endosomes, cyclophilin B aids in the dissociation of L1 from the L2/viral genome complex and L1 is routed to lysosomes for degradation<sup>54</sup>. The minor capsid protein L2 mediates the delivery of the viral genome from the early endosome to the trans Golgi network through direct interactions with the retromeric complex<sup>55,56</sup>. In particular, L2 associates with nexin 17 to allow the exit of the L2 complex/viral genome from the late endosomal compartments<sup>57</sup>. This interaction is conserved across multiple HPV types and is essential for viral infection<sup>58</sup>. L2 also interacts directly with nexin 27, another member of the host retromeric complex, to promote viral transport<sup>59</sup>. Virus movement through the cytoplasm to the nucleus likely occurs along microtubules via association of L2-associated vesicles with the light chains of the motor protein dynein<sup>60,61</sup>. Entry of the viral genome into the nucleus requires mitosis<sup>62</sup> and this process is mediated by L2. Upon entry into the nucleus, L2 and the viral genome locate in the ND10 domains, which is a critical step in establishing infection and allows transcription of the viral genome<sup>63</sup>.

- Genome replication and gene expression

After infection, initial genome amplification occurs before maintenance of the viral genome in the nuclei of infected basal epithelial cells. Viral DNA is maintained in the basal epithelial cells as a stable multicopy plasmid or episomal form. E1 and E2 are among the first viral proteins to be expressed, and while initial amplification is thought to require E1 and E2, E1 may not be required once the viral copy number has reached a threshold of 50–100 copies<sup>64</sup>. Based on cell line studies, the episomal copy number is thought to be approximately 200 per cell<sup>65</sup>. However, 50–100 copies per cell have been detected in the basal layer of productive warts using laser acquisition methods<sup>64</sup>. Viral genomes replicate once each cell cycle, on average, during S phase, ensuring persistent basal cell infection. In this "latent" stage of the viral life cycle, HPV genomes are thought to persist in basal epithelial cells for years or decades. However, at some point, a switch from stable replication (maintenance of the genome) to vegetative replication of viral DNA must occur to allow for the production of genomes to be packaged into virions. Little is known about the mechanism that regulates this step. Vegetative replication of viral DNA occurs in differentiated cells of the squamous epithelium. Two HPV proteins, E1 and E2, are actively involved in viral genome replication. E1 is the only enzyme encoded by the virus and functions as an ATP-dependent helicase<sup>19</sup>. E1 binds adenine-thymine-rich sequences at the origin of replication with low affinity and is required for the initiation and continuation of viral DNA synthesis. E2 stabilizes the binding of E1 to the origin of replication by interacting with ACCN6GGT sequences adjacent

to the origin, resulting in high affinity binding of the E1/E2 complex to the origin of replication<sup>20</sup>. HPVs do not encode other replication enzymes and must hijack the host DNA synthesis machinery to achieve viral genome replication. E1 and E2 recruit cellular DNA polymerases and other accessory enzymes essential to enable viral genome replication. Normally, differentiated cells would not be able to support DNA synthesis as they exited the cell cycle upon exiting the basal layer of the epithelium. However, HPVs are capable of activating mechanisms for cellular DNA replication to allow for vegetative synthesis of viral DNA through the actions of E6 and E7.

E6 and E7 contribute to the viral life cycle by modifying the cellular environment to allow for amplification of the viral genome in terminally differentiated cells, which would normally be incompetent for DNA replication. In particular, HR E6 and E7 drive cell proliferation in the basal and parabasal layers causing an increase in the size of the initial infected area. Many human papillomavirus E7 proteins target pRB and related pocket proteins p107 and p130<sup>25,66-69</sup>. HR HPV E7 proteins target pocket proteins for degradation via the ubiquitin/proteasome system. By binding to pocket proteins and/or triggering their degradation, E7 causes the release of pocket protein-bound E2F family members from transcriptional repressive complexes. This results in a constitutive activation of E2F-modulated gene expression programs that control DNA synthesis and cell proliferation<sup>70</sup>. Furthermore, some HPV E7 proteins avoid triggering G1 arrest during epithelial cell differentiation by

inactivating the inhibitors CDK2, CDKN1A and CDKN1B<sup>71</sup>. HR HPV E6 proteins inactivate the p53 suppressor by targeting it for proteasomal degradation via the associated E3 ubiquitin ligase, UBE3A (E6AP). This action blocks the antiproliferative and proapoptotic activities of p53 in response to DNA damage and cellular stress caused by inappropriate entry into the S phase<sup>72</sup>. HR HPV E6 expression also upregulates telomerase activity, allowing telomere integrity to be maintained despite repeated cell division<sup>73-75</sup>. Additionally, HR HPV E6 proteins target the cellular PDZ domain containing proteins that regulate cell contact and signaling pathways<sup>76,77</sup>. LR HPV E6 proteins, although capable of interacting with UBE3A, do not directly bind p53, but can indirectly target p53 transcriptional activity by binding to p300 and/or TIP60<sup>78,79</sup>. Furthermore, LR HPV E6 proteins do not activate telomerase activity and lack the C-terminal PDZ-binding domain. Beta HPV E6 proteins do not appear to affect either of these pathways, but have been reported to inhibit NOTCH and TGF $\beta$  signaling by associating with MAML and SMAD proteins, respectively<sup>80-83</sup>. Importantly, HPV infection induces a DNA damage response (DDR), and HPVs hijack the DDR ATR and ATM signaling pathways in favor of their own differentiation-dependent life cycles<sup>84</sup>. The ATM pathway is particularly important for differentiation-dependent genome amplification. HPV E1 and E7 activate DDR ATM and E2 can also modulate this pathway through association with E1<sup>84,85</sup>. Furthermore, the ATR pathway appears to play a role in HPV replication in undifferentiated cells by affecting episomal maintenance<sup>86,87</sup>.

- Assembly, maturation and release of the virus

Completion of the viral life cycle results in exit from the cell cycle and expression of L1 and L2 to allow for genome packaging. Virion assembly occurs in the nuclei of terminally differentiated keratinocytes, where replication of the viral genome and expression of viral proteins has occurred<sup>15</sup>. Nuclear entry of L1 and L2 is mediated by cellular karyopherins<sup>88,89</sup>, which transport molecules between the nucleus and cytoplasm. L1 can be assembled into VLPs and L2 can increase the efficiency of this step<sup>90,91</sup>. The packaging of the viral genome is not considered sequence specific<sup>92</sup> and may involve a size determination mechanism<sup>15</sup>. Maturation of viral particles occurs in the upper layers of differentiated squamous epithelia, where the particles are exposed to an oxidizing environment. This maturation process involves the accumulation of disulfide bonds between L1 proteins, resulting in the condensation of the capsid, thus increasing its stability and resistance to proteolytic digestion<sup>93</sup>. HPVs are non-lytic and viral shedding occurs due to the normal loss of nuclear and cytoplasmic integrity during terminal differentiation of the infected keratinocyte<sup>15</sup>. E4 can also contribute to the release of virions by binding to cytokeratin filaments and disrupting their structure<sup>21</sup>.

## 1.7 Non-productive infection and transformation

HR HPV-associated tumors often represent nonproductive infections, in which viral proteins are expressed but no infectious virus is produced. Deregulation of viral gene expression can be caused by integration of the viral genome into high-grade premalignant lesions, often resulting in the expression of only two viral proteins, E6 and E7. Such integration events often cause disruption or deletion of the E2 ORF, which encodes a transcriptional repressor of E6/E7<sup>94,95</sup> expression. Thus, E6/E7 mRNA expression may be higher from the integrated HPV subgenera. Furthermore, E6/E7 mRNAs produced from integrated genomes have been reported to be more stable than mRNAs expressed from episomal genomes<sup>96</sup>. An extensive analysis of the HPV genome in cervical lesions and tumors has shown that HPV integration sites often directly flank chromosomal aberrations including focal amplifications, rearrangements, deletions and/or translocations<sup>97</sup>. Based on a "round-the-clock" model, these host genomic alterations are triggered when HPV integrator-mediated DNA replication and recombination form host/viral DNA concatemers. This also involves the amplification of viral genome fragments containing E6 and E7<sup>97</sup>. Interestingly, however, some cervical cancers retain viral genomes in an episomal form<sup>98-100</sup>. In these cases, viral gene expression is probably deregulated by aberrant epigenetic alterations of the viral genome<sup>101</sup>.

Thus, the expression of E6 and E7 is deregulated in cervical carcinomas at multiple levels, and the expression of cellular genes flanking viral

genome integration sites may also be impaired, at least in cases where viral genome integration has occurred<sup>102</sup>. Expression of E6 and E7 is thought to increase during progression from cervical intraepithelial neoplasia 1 (CIN1) to CIN3, and given the ability of HR HPV E6 and E7 to promote genomic instability, expression of E6 and E7 are important contributors to malignant progression<sup>103,104</sup>. A recent study demonstrated that cervical cancers contain recurrent mutations in cellular genes including EP300, FBXW7, PIK3CA, HLA-B, TP53, MAPK1, PTEN, ERBB2, NFE2L2 and STK11<sup>102</sup>.

## 1.8 Clinical features

Although some HPV types can infect different parts of the body (skin, mucosa), viral tropism is not absolute, in fact the DNA of HPV types that infect the skin can be found in genital or oral warts and, in rare cases, the types with preferential mucosal tropism may be associated with skin lesions. The clinical manifestations depend on the type of HPV involved, on the anatomical district and on the immune status of the host (Table 2).



CLINICAL MANIFESTATIONS AND ASSOCIATED HUMAN PAPILLOMAVIRUS (HPV) TYPES		
	Frequently detected	Less frequently detected
<b>SKIN LESIONS</b>		
• Common, palmar, plantar, myrmecial and mosaic warts	1, 2, 27, 57	4, 29, 41, 60, 63, 65
• Flat warts	3, 10	28, 29
• Butcher's warts	7	1, 2, 3, 4, 10, 28
• Digital squamous cell carcinoma and Bowen's disease	16	26, 31, 33, 34, 35, 51, 52, 56, 73
• Epidermodysplasia verruciformis (EV)	3, 5, 8	9, 12, 14, 15, 17, 19–25, 36–38, 47, 49, 50, etc.
• EV – squamous cell carcinoma	5, 8	14, 17, 20, 47
<b>MUCOSAL LESIONS</b>		
• Condylomata acuminata	6, 11	40, 42–44, 54, 61, 70, 72, 81
• High-grade intraepithelial neoplasias (including cervical condylomata plana, bowenoid papulosis, erythroplasia of Queyrat) and invasive cancer	16	18, 26*, 31, 33, 35, 39, 45, 51, 52, 53*, 56, 58, 59, 62, 66*, 68, 73, 82
• Buschke–Löwenstein tumor	6, 11	
• Recurrent respiratory papillomatosis, conjunctival papillomas	6, 11	
• Heck's disease (focal epithelial hyperplasia)	13, 32	
*Probably carcinogenic <sup>33</sup> .		

Table 2: clinical manifestations and associated HPV types. Genus Beta is in bold. *Dermatology: ExpertConsult. (Elsevier, 2012).*

### 1.8.1 Skin infections

Types of HPV with skin tropism include a small group of viruses that infect the skin and induce the formation of common warts (*verruca vulgaris*), palmar and plantar warts, mosaic warts, flat warts, and butcher's warts. In general, the classification of warts is based on morphology, histology and anatomical location.

- Common warts <sup>105</sup>

Common warts are hyperkeratotic, exophytic, dome-shaped papules or plaques that are typically associated with HPV 1, 2, 4, 27, or 57. These

warts are most frequently found on the fingers and dorsal surfaces of the hands or other sites prone to trauma such as the knees or elbows, but can occur anywhere on the skin surface. Involvement of the proximal nail fold and/or ablative therapy at this site may damage the matrix, resulting in onychodystrophy. Typical features of common warts are black dots on their surfaces representing thrombosed capillaries and bleeding after curettage of the hyperkeratotic surface, by decapitation of the lesion vessels. Self-inoculation caused by a scratch can result in a linear arrangement of the warts. Warts can also develop as thread-like formations, especially in the periorificial area of the face. Palmar and plantar warts appear as thick, endophytic papules on the palms, soles, and lateral surfaces of the hands and feet, with gently sloping sides and a central depression. On the soles of the feet they are often painful. Plantar warts that come together in large plaques are referred to as mosaic warts. Extensive chronic warts have often been observed in immunosuppressed patients. In Europe, the HPV types most frequently associated with the development of palmoplantar warts are 1, 2, 27 and 57, most commonly in patients aged 6 to 10 years. Although a higher incidence of HPV 2 has been found in atopic children, other authors have not found an association.

- Flat warts <sup>105</sup>

Flat warts are pinkish to brown, relatively smooth, flat-topped papules, most commonly located on the hands, arms, or face often in a linear arrangement. They are usually caused by HPV types 3 or 10 and less often by 28 and 29.

- Butcher's warts <sup>105</sup>

Named for their frequent occurrence in meat (or fish) processing professionals, butcher's warts appear as warty papules or cauliflower-like lesions on the dorsal, palmar, or periungual. These warts are associated with HPV 7, not animal papillomavirus types.

- Epidermodysplasia verruciformis <sup>105</sup>

Epidermodysplasia verruciformis, is a rare genetic disorder. It is characterized by a particular susceptibility to cutaneous infections by  $\beta$  HPVs, which do not produce clinical lesions in immunocompetent patients. The disease usually manifests in childhood as highly polymorphic and diffuse lesions. About two dozen specific HPV types have been described in patients with EVs, a subset of which (primarily types 5 and 8) are also detected in EV-associated skin cancers. EV is usually inherited in an autosomal recessive manner and is caused by mutations that cause truncation of two genes, TMC6 (EVER1) and TMC8 (EVER2), which encode transmembrane proteins located in the endoplasmic reticulum. These proteins form a complex that interacts with zinc transporter 1 (ZnT1) and interferes with the intracellular distribution of zinc, downregulating zinc-associated transcription factors. Inhibition of ZnT1-TMC6/8 function by HPV E5 protein is thought to facilitate viral infection;  $\beta$  HPV lacks E5, but becomes pathogenic in EV patients with TMC6/8 deficiency. Patients with EV have diffuse or

confluent papules resembling flat warts; other features are hypopigmented guttate macules and small scaly, pinkish plaques. Actinic keratoses usually arise after age 30 and can slowly transform into invasive squamous cell carcinomas in about half of patients with EVs. These tumors have a low metastatic potential and mainly develop on sun-exposed areas such as the forehead, ears and hands. Patients with EV should be counseled on the importance of minimizing sun exposure, and family members should be screened for the presence of similar lesions. Types of  $\beta$  HPV can also sporadically induce EV-like lesions in immunocompromised patients, including transplant recipients, those with AIDS, or hematologic disorders. Furthermore,  $\beta$  HPV sequences have been isolated from normal skin of healthy individuals with highly sensitive DNA detection methods, indicating that the general population may serve as a reservoir for these HPV types.

- WHIM syndrome<sup>105</sup>

WHIM syndrome is a rare, autosomal dominant primary immunodeficiency disorder characterized by HPV-induced cutaneous and genital warts, hypogammaglobulinaemia, recurrent bacterial infections, and neutropenia due to myeloid maturation arrest (retention of mature neutrophils in the bone marrow). It is caused by mutations in the gene encoding CXC chemokine receptor 4 (CXCR4) and results in impaired leukocyte movement.

- WILD syndrome<sup>105</sup>

WILD syndrome is a disorder characterized by the presence of warts, cellular immunodeficiency, primary lymphedema, and multifocal

anogenital dysplasia. Patients report extensive warts, including condylomata acuminata, and lesions clinically (but not histologically) resembling those of patients with EV. Various types of  $\alpha$  HPV have been detected in skin and genital lesions.

### 1.8.2 Genital and airway infections <sup>105</sup>

More than 40 HPV types preferentially infect the mucosa and skin of the anogenital area and the upper airways. Subclinical infections are very common.

- External genital warts

They will be discussed in more detail in Chapter 2.

- Bowenoid papulosis and erythroplasia of Queyrat <sup>105</sup>

Bowenoid papulosis manifests as numerous red-brown papules or confluent plaques on the external genitalia, perineum, or perianal area. These lesions primarily affect young adults and may clinically resemble genital warts, but histologically represent high-grade squamous intraepithelial lesion (HSIL) or squamous cell carcinoma in situ. Erythroplasia of Queyrat is a distinct entity, presenting clinically as a well-demarcated, velvety erythematous plaque on the hairless skin of the penis or vulva that is histologically a HSIL. A biopsy is required for pigmented, erosive, bleeding, and/or therapy-resistant genital lesions to rule out malignant transformation. Bowenoid papulosis and erythroplasia predominantly contain high-risk HPV types, such as HPV 16, and thus may represent precursor lesion to vulvar, penile, or perianal carcinomas.

- Buschke–Löwenstein tumor<sup>105</sup>

Buschke–Löwenstein tumor (or giant condyloma acuminatum), florid oral papillomatosis, plant epithelioma cuniculatum, and papillomatosis cutis carcinoides comprise a group of "semimalignant" verrucous carcinomas, which are locally invasive and destructive but rarely metastasize. Buschke-Löwenstein is a rare cancer of the anal area and external genitalia associated with low-risk HPV types (6 or 11) that usually cause condyloma acuminata. In rare cases, preexisting anogenital warts can progress to large exophytic tumor masses that deeply infiltrate the underlying tissues and form fistulas and abscesses. The histology of the Buschke–Löwenstein tumor may resemble that of condyloma acuminata, although frank focal malignant transformation may occur spontaneously or after X-irradiation. High-resolution imaging and large biopsies are essential to identify and possibly verify the extension of focal areas of squamous cell carcinoma.

- Oral warts<sup>105</sup>

Oral warts appear as small, soft, pink or white, slightly raised papules or plaques on the buccal, gingival or labial mucosa, tongue or hard palate. Oral warts are associated with HPV types 6 and 11 and can be acquired through oral-genital intercourse. In patients with HIV, oral lesions are very common and may contain uncommon types of HPV such as 7, 71, 72 and 73. In focal epithelial hyperplasia, or Heck's disease, multiple circumscribed papules resembling flat warts or common warts are found on the gingival, buccal or labial mucosa. This disease is rare in Caucasians but relatively common in children native to South American,

Greenlandic, or South African communities. It is associated exclusively with HPV 13 or 32. HPV (particularly type 16) is a causative agent in approximately 25% of oropharyngeal carcinomas, particularly those affecting the lingual and palatine tonsils. HPV-associated oropharyngeal cancers are relatively common in never-smokers and predominate in younger patients with high-risk sexual behaviors. Although histopathologically poorly differentiated, they appear to have a better prognosis than HPV-negative oropharyngeal tumors.

- Oral florid papillomatosis <sup>105</sup>

In oral florid papillomatosis, multiple, confluent verrucous lesions associated with HPV 6 or 11 are found in the oral cavity or sinuses. The development of these lesions is thought to be favored by smoking, X-rays and chronic inflammation. Patients with oral papillomas need frequent examinations and repeated biopsies for early diagnosis in case of progression to verrucous carcinoma.

- Recurrent respiratory papillomatosis <sup>105</sup>

Recurrent respiratory papillomatosis is represented by benign exophytic laryngeal papillomas caused by HPV-6 and -11. Patients typically present with a triad of symptoms characterized by hoarseness, stridor, and respiratory distress. Papillomas occur most often in the transition zones between the squamous and ciliated epithelia of the larynx and subglottis, but rarely may extend to the distal trachea, bronchi, or even bronchoalveoli. Malignant transformation of laryngeal papillomas into squamous cell carcinomas has been reported in patients with long-lasting

disease and associated with exogenous factors such as X-rays, smoking, chemical toxins, or chemotherapy.

### 1.9 General concepts of therapy<sup>105</sup>

There is currently no specific antiviral therapy to cure HPV infection. Existing modalities mainly focus on the destruction or removal of visible lesions or the induction of cytotoxicity against infected cells. Due to the benign and self-limiting nature of warts, harsh and disfiguring treatments should be avoided. There is no evidence that aggressive treatment will lead to a better long-term outcome and temporary interruption of therapy is an option<sup>105</sup>. HPV infection is generally diffuse and multifocal in the anogenital region and subclinical lesions are often present, thus recurrence rates are very high. Treatment of genital warts will be discussed in detail in Chapter 2.

### 1.10 Vaccine

HPV prophylactic vaccines based on recombinant virus-like particles have been developed. Two first-generation vaccines approved by the Food and Drug Administration (FDA) prevent infections and diseases caused by HPV 16 and HPV 18, the two HPV genotypes that cause cervical cancer, and one of these vaccines also prevents HPV 6 and HPV 11, the two HPV genotypes that cause approximately 90% of genital warts. A new generation vaccine, recently approved by the FDA, targets HPV 16, HPV 18 and five other HPV genotypes that together cause approximately 90% of cervical cancers, as well as HPV 6 and HPV 11 (Tab. 3). In clinical trials, these vaccines have shown high levels of efficacy against disease and



infection caused by the target HPV genotypes in female and male adolescents and adult females. The data indicate that the efficacy in the population (and therefore a good cost-effectiveness ratio) is higher in young HPV naïve females, ie before becoming sexually active. Countries that implemented HPV vaccination before 2010 have already reported a reduction in HPV-associated diseases in women and, by herd immunity, in heterosexual men. Importantly, after more than 100 million doses administered worldwide, HPV vaccination has demonstrated an excellent safety profile. With demonstrated efficacy, both in terms of cost and safety, universal HPV vaccination of all young adolescent women and at least high-risk groups of men should be a global health priority<sup>106</sup>.

	Cervarix (2vHPV)	Gardasil (4vHPV)	GARDASIL 9 (9vHPV)
Manufacturer	GSK	Merck	Merck
Targeted HPV types	HPV16 and 18	HPV6, 11, 16, and 18	HPV6, 11, 16, 18, 31, 33, 45, 52, and 58
Recommended vaccination schedule	0, 1, and 6 months	0, 2, and 6 months	0, 2, and 6 months
Vaccine composition	20 mg HPV16 and 20 mg HPV18 VLPs	20 mg HPV6, 40 mg HPV11, 40 mg HPV16, and 20 mg HPV18 VLPs	30 µg HPV6, 40 µg HPV11, 60 µg HPV16, 40 µg HPV18, 20 µg HPV31, 20 µg HPV33, 20 µg HPV45, 20 µg HPV52, and 20 µg HPV58 VLPs
Recombinant protein expression system	Baculovirus (insect) cell	<i>Saccharomyces cerevisiae</i> (bread yeast)	<i>Saccharomyces cerevisiae</i> (bread yeast)
Adjuvant	500 mg aluminum hydroxide and 50 mg 3- <i>O</i> -desacyl-4' monophosphoryl lipid A (MPL), a detoxified derivative of the lipopolysaccharide (LPS) of the Gram-negative bacterium <i>Salmonella</i> Minnesota R595 strain	225 mg amorphous aluminum hydroxyphosphate sulfate	225 mg amorphous aluminum hydroxyphosphate sulfate
FDA approvals (date) (link to package insert)	<ul style="list-style-type: none"> <li>● 9- to 25-year-old females (16 October 2009) (<a href="http://www.fda.gov/downloads/BiologicsBloodVaccines/Vaccines/ApprovedProducts/UCM186981.pdf">http://www.fda.gov/downloads/BiologicsBloodVaccines/Vaccines/ApprovedProducts/UCM186981.pdf</a>)</li> </ul>	<ul style="list-style-type: none"> <li>● 9- to 26-year-old females (8 June 2006)</li> <li>● 9- to 26-year-old males (for genital warts) (16 October 2009)</li> <li>● 9- to 26-year-old males (for anal cancer) (22 December 2010) (<a href="http://www.fda.gov/downloads/BiologicsBloodVaccines/Vaccines/ApprovedProducts/UCM111263.pdf">http://www.fda.gov/downloads/BiologicsBloodVaccines/Vaccines/ApprovedProducts/UCM111263.pdf</a>)</li> </ul>	<ul style="list-style-type: none"> <li>● 9- to 26-year-old females (10 December 2014)</li> <li>● 9- to 15-year-old males (10 December 2014) (<a href="http://www.fda.gov/downloads/BiologicsBloodVaccines/Vaccines/ApprovedProducts/UCM426457.pdf">http://www.fda.gov/downloads/BiologicsBloodVaccines/Vaccines/ApprovedProducts/UCM426457.pdf</a>)</li> </ul>
Current ACIP recommendations* [96]	<ul style="list-style-type: none"> <li>● Females: Routine vaccination with three-dose series at age 11 or 12 years, and through age 26 years if not vaccinated previously</li> </ul>	<ul style="list-style-type: none"> <li>● Females: Age 11 or 12 years, and through age 26 years if not vaccinated previously</li> <li>● Males: Age 11 or 12 years, through age 21 years if not vaccinated previously, and through age 26 years for men who have sex with men and men who are immunocompromised (including those with HIV infection)</li> </ul>	<ul style="list-style-type: none"> <li>● Females: Age 11 or 12 years, and through age 26 years if not vaccinated previously</li> <li>● Males: Age 11 or 12 years, through age 21 years if not vaccinated previously, and through age 26 years for men who have sex with men and men who are immunocompromised (including those with HIV infection)</li> </ul>

VLP, Virus-like particle.  
\* The vaccination series can begin at age 9 years.

Table 3 Basic information of the main HPV vaccines. Castle, P. E. & Maza, M. Prophylactic HPV vaccination: past, present, and future. *Epidemiol. Infect.* **144**, 449–468 (2016).

## Chapter 2 – External genital warts

### 2.1 Introduction

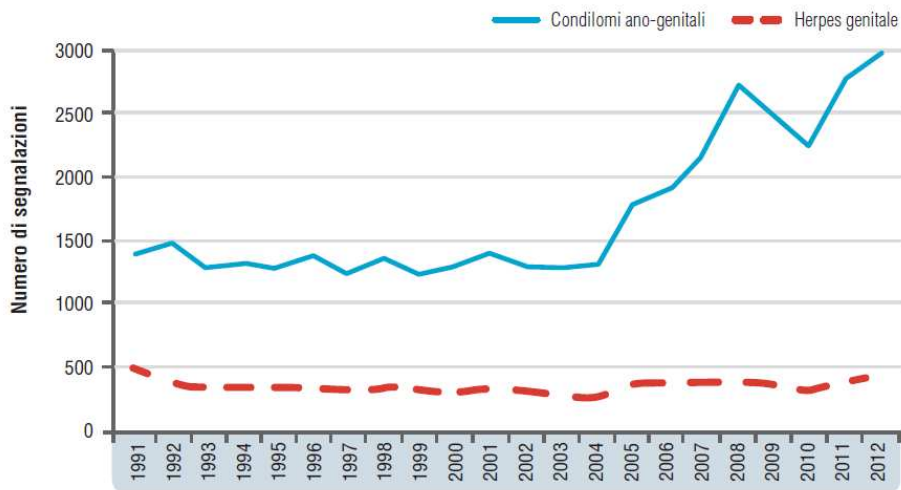
HPV infection is the most common of the sexually transmitted viral infections. Approximately 40 of the 150 HPV types have been associated with genital lesions in males and females. The subdivision between low-risk (LR HPV) or high-risk (HR HPV) viral types is commonly used in relation to the association that each viral type has with benign lesions (anogenital warts or condylomas) or with malignant lesions or potential malignant evolution (squamous cell carcinomas). Anogenital HPV infection is equally frequent in both sexes and is transmitted almost exclusively through sexual contact. Persistent HR HPV infection is the most common cause of anogenital cancers. However, this phenomenon occurs in a small percentage of infected individuals. HR HPV DNA is present in 100% of cervical cancers and in situ malignancies. Warts are the clinical manifestation of LR HPV infection, in particular HPV 6 and 11, present in more than 95% of benign lesions<sup>107,108</sup>, and occur, in both sexes, predominantly at a young age. The diagnosis of condyloma is often only clinical. In case of clinical doubt, the fundamental diagnostic procedure is histological examination. In all cases of warts it is important to exclude the presence of other sexually transmitted infections<sup>109</sup>.

### 2.2 Epidemiology

The epidemiology of genital warts is not entirely well defined. In the literature it is reported that anogenital HPV infection affects about 40%

of the population during their sexually active life. The peak prevalence is between 15 and 24 years with a slightly lower age for females. The annual incidence rate has recently been calculated to be 0.15% of the general adult population<sup>110</sup>. An increase in genital warts throughout the Western world is reported in the literature. This phenomenon is attributable to an earlier onset of sexual activity, as well as an increased total number of partners. The most robust statistical data comes from the United Kingdom<sup>111</sup>. In 2008, an incidence of 289/100,000 inhabitants was reported. The cost for each individual episode was estimated to be £113 with a global expenditure estimated at £16.8 million. In Italy there are no data relating to the general population. In a 2017 study carried out by gynecologists, they calculated an incidence of 3 cases per 1000 women and a prevalence of 3.8 cases per 1000 women<sup>112</sup>. In a previous study, an incidence of 0.47% and a prevalence of 0.76% were estimated for the male population of the same age group. Recent data are reported by the Istituto Superiore di Sanita (IST) in 2014<sup>113</sup> and refer to the sentinel surveillance system for STIs active since 1991. The study reports data on 12 sentinel clinical centers that recorded diagnoses of sexually transmitted infections. In the entire period, the diagnosis of anogenital warts was the most frequent, representing 38.7% of the total diagnoses. In males, anogenital warts accounted for 40.7% of reports, while in females 34.2%. The annual number of reports of anogenital warts remained constant until 2004 and then showed a progressive increase reaching the maximum peak in 2012 with an increase more than double compared to 2004 (Graph. 1). Furthermore, an important fact to consider is the epidemiological relationship between warts and human

immunodeficiency virus (HIV) infection. In the sentinel system, the prevalence of HIV infection out of the total number of sexually transmitted infections was 7.3% and in the year 2012 it was 6.4%. For warts observed in the period 1991-2012, the prevalence of HIV positivity was 7.7%. It should be emphasized that 31.1% of HIV positive subjects discovered their status when diagnosing warts; this data further underlines the importance of promoting HIV testing in all subjects who seek medical attention for anogenital warts.



Graph 1 Reporting trend of the main viral STIs (STI sentinel surveillance system based on clinical centers, 1991, 2012) (Notiziario IST 2014, mod.). Verruche Ano-genitali e Cutanee - Linee Guida e Raccomandazioni SIDeMaST 2016-2017

## 2.3 Transmission

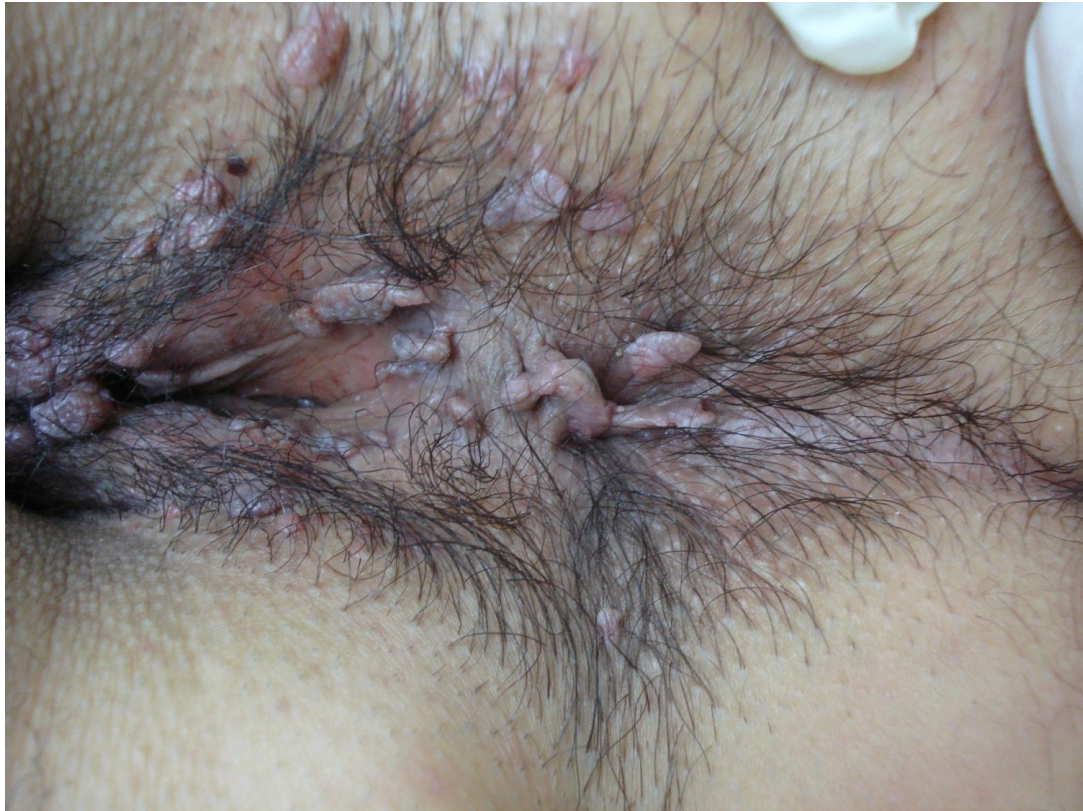Genital HPVs are transmitted through direct sexual contact; vertical transmission between mother and infant is also possible both during passage through the birth canal and after birth. Indirect transmission is not clearly documented. The phenomenon of self-inoculation is a documented but rare phenomenon. Indirect transmission via fomites or during surgical procedures (e.g. laser vapours) has never been

demonstrated<sup>114,115</sup>. Genital warts are transmitted with a 60% transmission rate between partners<sup>116</sup>.

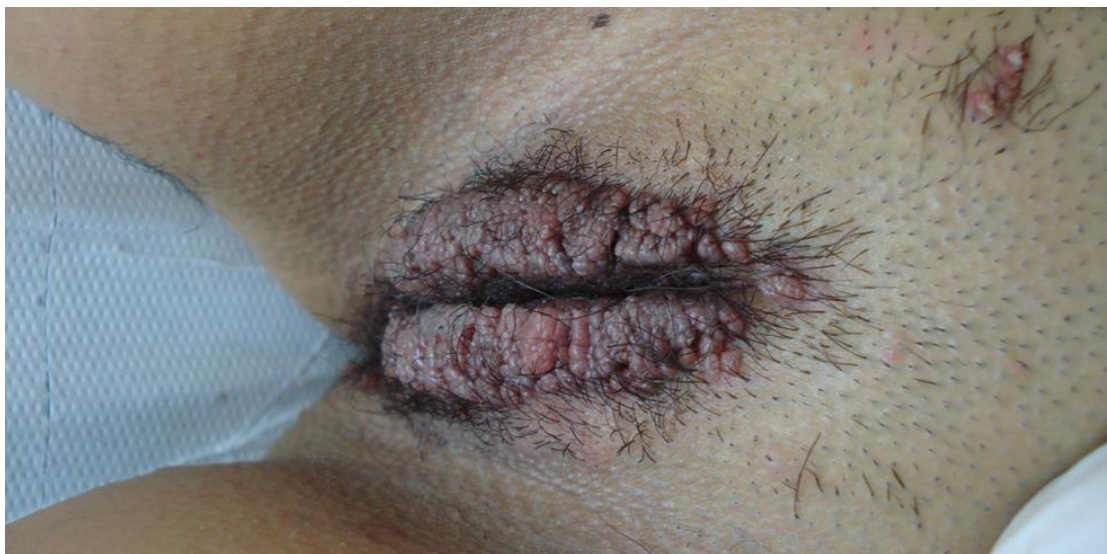## 2.4 Clinical manifestations

### 2.4.1 Clinical aspects

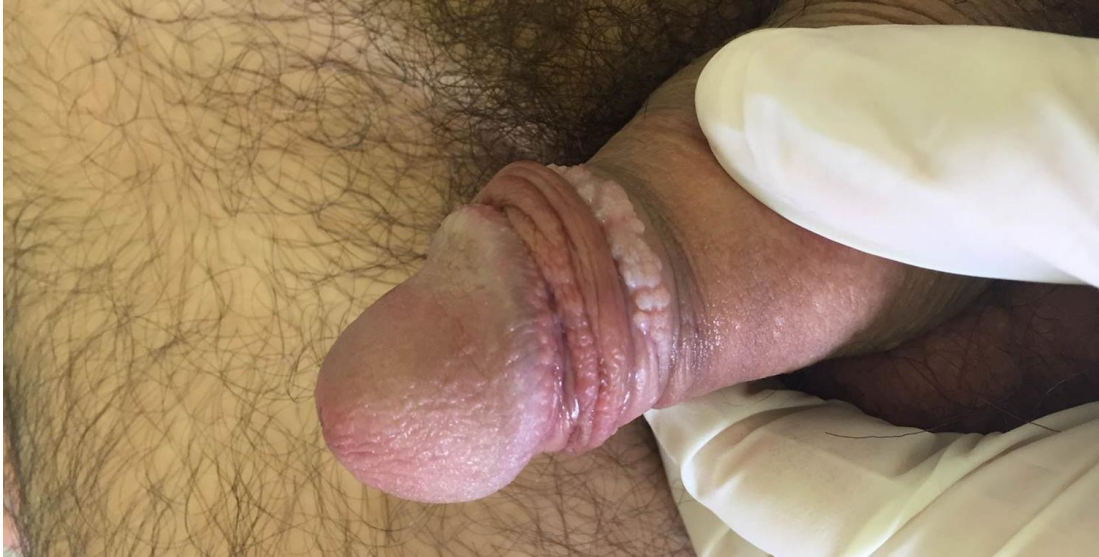Anogenital warts or condylomata acuminata can be located on the external genitalia, perineum, perianal area or on adjacent areas such as the inguinal fold and pubic region. Lesions may extend into the vagina, urethra, or anal canal (but rarely beyond the dentate line)<sup>105</sup>. Warts are usually sessile exophytic formations with a smooth or warty surface and can vary in color. They can be of different sizes. Warts can also appear as pedunculated or broad-based up to several centimeters in diameter or as large confluent plaques<sup>105</sup>. High-grade intraepithelial neoplasms are usually caused by high-risk types, mainly HPV16, 18, and 31, while benign lesions can contain both low-risk and high-risk HPV types. Other clinical features include flat, plaque, or papular pigmented lesions. At the level of the semimucous membranes, in areas without follicles, warts usually appear as non-keratinized and friable lesions, in contrast to warts which occur at the level of hairy areas which are usually hyperkeratotic and firm. They can be single or multiple (Fig.6-9)<sup>109</sup>.



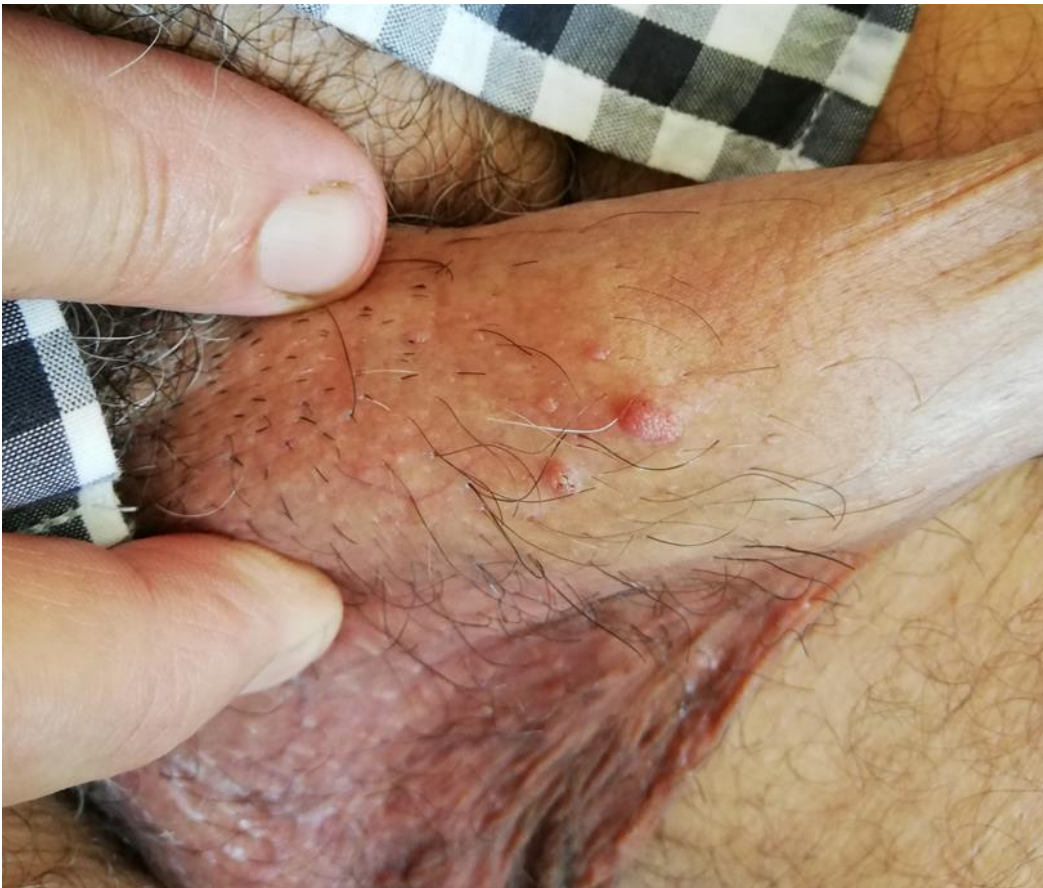*Figure 6 Perianal warts in a young woman*



*Figure 7 Extensive vulvar condylomatosis in a young woman treated with cyclosporine for psoriasis*



*Figure 8 Warts in the preputial site*



*Figure 9 Penile warts*

#### 2.4.2 Localization

HPV causes a multifocal infection of the entire anogenital region<sup>117</sup>; lesions are more frequent at sites of trauma during sexual intercourse, but can occur throughout the area<sup>116</sup>. Perianal lesions are common in both sexes and are not necessarily related to anal sex practices<sup>118</sup>. Patients report growth in the number and/or volume of lesions in the anogenital area. Extragenital lesions caused by the same HPV types that cause warts can be seen in the oral cavity, larynx, conjunctivae, and nasal cavity<sup>109</sup>.

#### 2.4.3 Associated symptoms

Warts are almost always asymptomatic. Symptoms may include local irritation, bleeding and itch/burning. Larger lesions may undergo maceration and ulceration, with secondary superinfection<sup>109</sup>.

#### 2.4.4 Incubation

The incubation period varies from 3 to 8 weeks, but it can reach 18 weeks and is usually longer in males<sup>119</sup>. It is not possible to recognize a new lesion from a recurrence or reinfection, although reinfections appear to be rare<sup>120</sup>.

#### 2.5 Diagnosis

The diagnosis of anogenital warts is clinical in most cases; it can sometimes be useful to use dermatoscopy to distinguish warts from other lesions. Histological examination is rarely necessary for diagnostic confirmation in atypical lesions.



The most frequent histological features include epidermal hyperplasia, parakeratosis, koilocytosis, and papillomatosis. The upper parts of the mucosalepithelium usually have some degree of cytoplasmic vacuolization, so its finding is specific for condyloma acuminata only if present in the deeper layers<sup>121</sup>.

An examination of the anal canal is indicated in case of anorectal symptoms such as discharge and irritation. Other high-risk HPV-related lesions may coexist with warts. The diagnosis of neoplastic intraepithelial lesions at the vulvar (VIN), vaginal (VAIN), perianal (PAIN) and penile (PIN) level should always be suspected in case of hyperpigmentation, especially in patients with immunodeficiency<sup>109</sup>.

## 2.6 Patient classification

- Examine the skin of the anogenital area and the surrounding region in good light conditions.
- Use any magnification systems for small lesions and uncertain diagnosis.
- Females must be examined with a speculum, in the absence of internal lesions it is not necessary to use the speculum at subsequent visits.
- Anoscopy is not indicated as a routine examination. It is indicated in patients with lesions on the edge of the anal sphincter or in patients with intraanal symptoms (inflammation, bleeding or losses).
- Meatoscopy can be used in case of intrameatal warts that are not totally visible.

- Urethroscopy is rarely needed for proximal warts.
- Depending on the history, observation of extragenital sites (oral cavity) may be indicated.
- Accurately describe the morphology of the lesions.
- It may be advisable to use a map at each visit to facilitate follow-up during treatment<sup>109</sup>.

## 2.7 Therapy

### 2.7.1 Objectives of the treatment

The treatment of warts has the following objectives:

- removal of visible lesions and/or relief of symptoms;
- prevention of recurrences;
- reduction of contagiousness;
- relief of stress related to the infection.

While the first objective is generally achievable with all treatments, the second is possible only with topical immunomodulators (imiquimod, sinecatechins). Infectiousness can be reduced but not eliminated by treatment, and virus transmission is possible even in the absence of visible lesions for a few months after the lesions have regressed. The stress linked to the infection is the greatest discomfort for the patient that he attributes to condylomas, linked to concerns about the methods and timing of the infection, the recurring nature of the lesions, the long healing times, the identification of the partner-source, the fear of spreading the infection, the difficulty in resuming sexual activity, the fear of being reinfected by the partner, the anxiety of betrayal, the fear of cancer and the contagion of the newborn at the time of delivery. Only the explanation, point by point, by the specialist and adequate

counseling can bring the relief that no treatment can obtain<sup>122</sup>. The efficacy of the treatments, which is difficult to standardize due to the lack of homogeneity of the studies reported in the literature, is measured on two parameters: the regression of the lesions and the frequency of recurrences (Table 4).

Trattamento	Regressione clinica (ITT)	Durata del trattamento	Frequenza delle recidive	Follow-up dalla fine del trattamento
Podofillotossina 0,5%	45-83%	3-6 settimane	13-100%	8-21 settimane
Nitrizinc complex <sup>1</sup>	90 %	1 – 8 settimane	-	-
Imiquimod 5%	35-68%	16 settimane	6-26%	10 settimane
Sinecatechine 10% <sup>2</sup>	53 %	16 settimane	5,8 %	12 settimane
Acido tricloroacetico	56-81%	8-10 settimane	36%	2 mesi
Crioterapia	44-75 %	6-10 settimane	21-42%	1-3 mesi
Diatermocoagulazione	94-100 %	1-6 settimane	22%	3 mesi
Laser CO <sub>2</sub> <sup>3</sup>	23-52 %	-	60-77%	3-18 mesi
Escissione chirurgica	89-100%	6 settimane	19-29%	10-12 mesi

Table 4 Lesion regression rates and recurrence frequencies reported in the literature for the main therapies

In the absence of a response after at least 2 months or in the case of recurrences without a reduction in the number of lesions, it is advisable to change the therapeutic option or to consider therapeutic abstention<sup>123</sup>. Given the possibility of spontaneous regression within 6 months described in 30% of untreated patients, a therapeutic break can be an option when treatments prove to be an additional source of pain and stress.

## 2.7.2 Treatments

They can be divided into two categories: destructive treatments, i.e. those that destroy the lesions with the use of chemical compounds or physical techniques, and immunomodulatory treatments (Table 5).

They can also be divided into treatments performed by the doctor (to be preferred in the case of large or difficult to identify lesions by and in the case of multi-district involvement) and treatments managed by the

patient (useful in the case of small, few, recurring lesions when they are easily identifiable by the patient)<sup>109</sup>.

	Provider-applied treatment regimens	Patient-applied treatment regimens
Procedure	Removal by healthcare provider Anesthesia may be required	Application by patient Patience and adherence of patient required
Pros	Fast clearance	Low risk of recurrence Convenience of patient, noninvasive
Cons	High risk of recurrence, risk of scarring and wound infection, pain during procedure	Slower clearance, slightly lower complete clearance rate, and irritation

Table 5 Pros and cons of the main therapies - Schöfer, H. et al. *Sinecatechins and imiquimod as proactive sequential therapy of external genital and perianal warts in adults*. *Int. J. STD AIDS* **28**, 1433–1443 (2017).

- Ablative treatments
  - Cryotherapy: treatment based on the application of liquid nitrogen capable to induce cytolysis. It is a simple, rapid method, which can be performed at the time of diagnosis, does not require injection anesthesia, especially suitable for small-medium sized mucosal lesions with rapid healing times (days). Cryotherapy is often accompanied by the onset of burning pain, lasting a few minutes, which is reduced if a topical anesthetic is applied at least an hour before. Not very effective on large lesions if not with multiple sessions. It does not cause scars, but can cause hypopigmentation if performed on skin with dark phototypes<sup>109</sup>.
  - Diathermocoagulation (DTC): it is the most effective treatment in the removal of medium-large lesions in a single session, especially if cutaneous. Given the epidermal localization of the lesions, the treatment must be carried out superficially, taking care to save healthy tissue between the wounds. It requires local, topical or more frequently injection anesthesia, with long healing times

(weeks) and painful wounds. It can cause dyschromia or pathological scars (keloids) in predisposed patients<sup>109</sup>.

- Carbon dioxide laser (CO<sub>2</sub>): CO<sub>2</sub> laser therapy is based on the use of a concentrated beam of infrared light energy, which vaporizes the target areas<sup>124</sup>. It is the most precise and safest treatment, especially suitable for numerous small-medium sized lesions, both cutaneous and mucous, with rapid healing times (days) and little painful wounds. It can also be used for lesions in the vaginal, anal and oral cavities and in the urethral meatus. It is a treatment that requires special precautions (smoke aspirator, safety measures), expert personnel and longer execution times than the previous ones<sup>109</sup>. After CO<sub>2</sub> laser removal, recurrences have been reported in up to 60%-77% of cases<sup>125</sup>.
- Surgical excision: can be performed superficially with the technique of shaving, scissors or scalpel, and suture is rarely necessary. It is indicated for small, large lesions with a pedunculated papillomatous appearance and in the case of excisional biopsy for histological examination<sup>109</sup>.
- Podophyllotoxin 0.5% solution: it is an antimitotic capable of inducing necrosis of the treated lesion. It is indicated for small lesions, especially if located on the mucous membranes, up to 10 cm<sup>2</sup>. Less effective in females and circumcised males. It is the ideal treatment for the home management of recurrences characterized by a few small lesions. It is contraindicated in pregnancy, as it is teratogenic, and in children < 12 years<sup>109</sup>.

- Trichloroacetic acid solution 60-90%: it is a caustic agent capable of inducing the coagulation of tissue proteins. Especially indicated for small-medium sized mucosal lesions, including intracavity lesions (vagina, rectum). It is applied by the doctor with a swab after drying the area. It can cause intense inflammation of the surrounding area which can be controlled with basic compounds (5% sodium bicarbonate or talc). The applications are repeated weekly until the lesion is completely removed. Given the absence of systemic absorption, there are no contraindications for use in pregnancy<sup>109</sup>.
- Nitrizinc complex: it is a cytolytic compound, which acts by "mummification" through protein denaturation. It is especially suitable for small-medium sized lesions, both mucous and cutaneous, and has the advantage that it is associated with a weak local inflammatory reaction. It should be applied by professional personnel in minimal quantities with a special capillary every week on the mucous membrane and every two weeks on the skin up to 4 times. Since there are no data on systemic absorption, it is not recommended for use during pregnancy and in children under 5 years of age. Responsibility is left to the specialist who is able to evaluate the risks and benefits of the treatment<sup>109</sup>.

- Immunomodulatory treatments

Unlike the previous ones, immunomodulatory treatments are less effective in removing the lesions, take longer, are irritating; anyway, they are associated with a lower frequency of recurrences. In the absence of

a response, even if partial, a change of treatment is recommended after 2 months.

- Imiquimod 5% cream: is an immunomodulator that activates the innate and local cell-mediated response, inducing the release of alpha interferon. It is indicated for small to medium sized lesions, multiple and extended over large areas and for recurring lesions. It is more effective and faster in women than in men. It should be applied 3 times/week in the evening and rinsed off after 8 hours until the lesions regress (2-4 months). It is always associated with a local inflammatory reaction that can limit patient compliance and more rarely with flu-like systemic symptoms, permanent hypopigmentation or worsening of phimosis, psoriasis, vitiligo and lichen planus. It can be used in immunocompromised patients, albeit with less efficacy<sup>115,117</sup>. Although it has not been shown to be teratogenic<sup>122,123</sup>, use during pregnancy is currently contraindicated.

- Sinecatechins 10% ointment: should be applied 3 times a day until the lesions regress or in any case up to 16 weeks and should be removed before sexual intercourse. Topical 10% sinecatechins is a patient-applied therapy with a low recurrence rate (6.5%) three months after completion of therapy in studies conducted to date<sup>126</sup>. It is an extract of green tea leaves from *Camellia sinensis*<sup>127</sup>. The main components of sinecatechins are polyphenols and in particular flavonoids, 85% of which are eight different catechins<sup>128</sup>. More than half of the catechins are represented by epigallocatechin-3-gallate (EGCG) which is the

most potent catechin<sup>129</sup>. Sinecatechin ointment is effective in the treatment of external genital warts<sup>126,130</sup>. Although the exact mechanism of action is currently unknown, it probably consists of antiviral, pro-apoptotic, and immunomodulatory activities<sup>129,131–133</sup>. The antiviral properties could result from the inhibition of the transcription activator activity of protein 1 which effectively downregulates the expression of HPV genes. Furthermore, EGCG can activate pro-apoptotic proteins<sup>134</sup>, and preclinical studies suggest that polyphenols can modulate inflammatory processes<sup>135,136</sup>. The treatment is generally well tolerated and local skin reactions such as erythema, edema and erosions are the most indicated side effects<sup>128</sup>. Severe local reactions are rare and are mainly observed at higher concentrations (15%)<sup>128</sup>. This treatment is contraindicated in pregnancy and lactating pregnancy and in immunosuppressed patients, although studies of the use of sinecatechins in these patients are present in the literature<sup>137,138</sup>.



There are specific indications regarding the use of the various therapies in particular body sites (Tab.6)<sup>139</sup>.

Recommended Regimens for Urethral Meatus Warts
<p>Cryotherapy with liquid nitrogen OR Surgical removal</p>

Recommended Regimens for Vaginal Warts
<p><b>Cryotherapy with liquid nitrogen.</b> The use of a cryoprobe in the vagina is not recommended because of the risk for vaginal perforation and fistula formation. OR Surgical removal OR TCA or BCA 80%–90% solution</p>

Recommended Regimens for Cervical Warts
<p>Cryotherapy with liquid nitrogen OR Surgical removal OR TCA or BCA 80%–90% solution Management of cervical warts should include consultation with a specialist. For women who have exophytic cervical warts, a biopsy evaluation to exclude high-grade SIL must be performed before treatment is initiated.</p>

Recommended Regimens for Intra-anal Warts
<p>Cryotherapy with liquid nitrogen OR Surgical removal OR TCA or BCA 80%–90% solution Management of intra-anal warts should include consultation with a specialist.</p>

Table 6 Treatments for genital warts at particular sites. Workowski, K. A., Bolan, G. A. & Centers for Disease Control and Prevention. Sexually transmitted diseases treatment guidelines, 2015. *MMWR Recomm. Rep. Morb. Mortal. Wkly. Rep. Recomm. Rep.* **64**, 1–137 (2015).

## 2.8 Follow up

Most anogenital warts respond within 3 months of therapy. Factors that could affect response to therapy include immunosuppression and treatment compliance. In general, warts located on moist surfaces or in intertriginous areas respond best to topical treatment. A new treatment modality should be considered when no substantial improvement is observed after a full course of treatment or in case of severe side effects. Side effects rarely occur when the treatment is done correctly. Persistent hypopigmentation or hyperpigmentation can occur with ablative modalities (e.g. cryotherapy and diathermocoagulation) and has been described with immunomodulatory therapies (e.g. imiquimod cream). Atrophic or hypertrophic scarring is rare but can occur especially if patients do not have enough time to heal between treatments. Rarely, treatment can lead to chronic pain syndromes (e.g. vulvodynia and hyperesthesia at the treatment site) or, in the case of anal warts, painful defecation or fistulas<sup>123</sup>.

## 2.9 Counseling

Key messages for people with anogenital warts:

- If left untreated, genital warts may disappear, stay the same, or increase in size or number. The types of HPV that cause genital warts are different from the types that can cause cancer.
- Women with genital warts don't need Pap smears as often as other women.
- The time of acquisition of HPV cannot be determined definitively. Genital warts can develop months to years after you get HPV. The types

of HPV that cause genital warts can be passed on to another person even in the absence of visible signs of warts. Sexual partners tend to share HPV, although signs of HPV may occur in only one partner or neither.

- Although genital warts are common and benign, some people may suffer a significant psychosocial impact after receiving this diagnosis.
- Although genital warts can be treated, such treatment does not cure the infection. For this reason, it is common for genital warts to recur after treatment, especially in the first trimester.
- Genital warts can be transmitted sexually: patients with the condition should also be tested for other sexually transmitted diseases. HPV may remain present and can still be passed on to partners even after the warts have disappeared.
- Condoms can reduce the chances of passing on anogenital warts if used correctly; however, HPV can infect areas that are not covered by condoms<sup>123</sup>.

## 2.10 Management of sexual partners

People should inform current partners. Partners should receive appropriate counseling, advising them that they may already have HPV despite no visible signs of warts. Partners may benefit from a physical examination for signs of HPV infection and testing for other sexually transmitted infections<sup>123</sup>.

## CHAPTER 3 – Clinical Study

### 3.1 Preliminary considerations

External genital warts are very common. Physician-applied treatments such as cryotherapy, curettage and CO<sup>2</sup> laser therapy offer the advantage of ensuring a rapid therapeutic effect, with rapid elimination of clinically evident lesions and a reduction in viral load. However, these procedures are associated with high recurrence rates (RR) (about 20% -77%) in the short and medium term, not allowing a lasting clearance<sup>140</sup>.

### 3.2 Proactive sequential therapy concept

Guidelines for the treatment of external genital and perianal warts broadly summarize the etiology, clinical features, diagnosis, and management of the disease. However, they do not help the physician with substantiated treatment recommendations for a specific patient<sup>141</sup>. Due to the limitations described for single therapeutic options<sup>109</sup>, the sequential combination of an initial destructive therapy provided by the physician for rapid and complete clearance and a subsequent topical immunomodulatory treatment applied by the patient to bring down the recurrence rate, is used by some physicians in normal clinical practice<sup>141</sup>. This combination, defined as "sequential proactive therapy" is considered the most promising for reducing the risk of recurrence and transmission to sexual partners, conditions that most frequently occur within the first six months of treatment. The logic of sequential therapy is the treatment of subclinical lesions not eliminated by ablative treatment. In clinical practice, the ablative method should be used until

complete resolution of visible lesions. After wound healing (typically 3-5 days), the patient will apply the topical immunomodulatory treatment to the affected area for 12-16 weeks. The most suitable are therapeutic options with low RRs, confirmed by clinical studies and showing good tolerability. The best candidates are topical treatments with sinecatechins or imiquimod<sup>128</sup>. Concerning the level of evidence, the benefit of this regimen has yet to be confirmed by prospective clinical studies. So far we have only limited data: the use of sinecatechin 15% ointment after destructive treatment with cryotherapy plus podophyllin is described in a retrospective analysis by Juhl et al.<sup>142</sup>. 27 patients were treated with a combination approach and showed a clearance rate of 96.3% and a RR of only 7.4%, which are significantly better than the success rates for single modality approaches (e.g. podophyllotoxin : complete clearance rates 45–77%, RR 38–65%<sup>143</sup>; sinecatechins: complete clearance rates 51–57%, RR 4–8%<sup>126,128</sup>; and cryotherapy: complete clearance rates 79–88%, RR 25–25%. 39%<sup>125</sup>). Juhl et al. preferred the use of sinecatechins due to their good tolerability profile compared to imiquimod (no systemic side effects, no risk of hypopigmentation in the treated areas) and low RR. In addition, a three-arm randomized comparative study of imiquimod 5% cream has been published. This study included patients treated with ablative therapy followed by imiquimod (103 patients), patients treated with ablative treatment alone (100 patients) and patients treated with imiquimod alone (155 patients); Sustained clearance rates at six months were 91.5% in the combination therapy group, 73.6% in the ablation group, and 93.7% in the imiquimod alone group. In this study, combination therapy

was not superior to immunomodulator monotherapy<sup>144</sup>. Another randomized study published by On et al<sup>145</sup> compared warts treated with cryotherapy alone versus initial cryotherapy followed by sinecatechin 15% ointment applied by the patient twice daily for 16 weeks. In this study, 42 patients with at least two external genital warts underwent cryotherapy. Then they were randomized 1:1 to further treatment with sinecatechin 15% ointment, twice daily, for up to 16 weeks or until complete recovery or no additional treatment. Patients were followed up for a total of 65 weeks. The study demonstrated that cryotherapy has a direct cytotoxic effect with immediate short-term efficacy, while sinecatechins guarantee a more lasting clearance, treating both clinical and subclinical lesions. No serious adverse events were reported.

### 3.3 Aim of the study

Based on the previous observations, we decided to evaluate the efficacy and tolerability of a sequential proactive treatment, in particular using sinecatechin 10% ointment applied twice daily for 16 weeks in subjects affected by condyloma acuminata in the external genital or perianal site after CO<sup>2</sup> laser ablative therapy in a prospective randomized study. We used the recurrence rate of new condylomatous lesions in the treated sites as the main efficacy parameter.

### 3.4 Materials and methods

#### 3.4.1 Study project

It was a prospective, randomized study with allocation of patients (2:1) in two treatment arms, conducted at the Outpatient Department of Sexually Transmitted Diseases of the UOC of Dermatology of the Siena University Hospital "Santa Maria alle Scotte".

#### 3.4.2 Subjects

The inclusion criteria were:

- $\geq 18$  years old men or women with clinically evident condyloma acuminata suitable for ablative procedures, located on the penile shaft, foreskin, glans, pubic region, scrotum, large and small lips and in the perianal area, for a maximum extension of 25 cm<sup>2</sup>.

The exclusion criteria were:

- patients who have already undergone previous treatments for condyloma acuminata;
- immunocompromised patients;
- HIV-infected patients;
- pregnant or breastfeeding women;
- <18 years old;
- patients with known allergy to green tea derivatives;
- meatal lesions.

All study participants signed written informed consent. After disinfection of the skin with sodium hypochlorite 0.05% solution and cleansing with

physiological solution, we performed local anesthesia with 2% lidocaine. Subsequently we performed the vaporization of the lesions and 2 mm of peri-lesional healthy skin with CO2 laser (SmartXide 2; DEKA M.E.L.A. Srl - Calenzano, Florence, Italy). The laser therapy was repeated after three weeks in case of larger or more extensive lesions.

We enrolled and treated by CO2 laser ablation 36 patients, subsequently divided into 2 groups:

- Group A: 24 patients were allocated in the treatment arm with Sinecatechins 10% ointment (Veregen™, Cantabria Labs Difa Cooper, Caronno Pertusella, Italy) applied 2 times a day (morning and evening) for the following 16 weeks;
- Group B: 12 patients were allocated to the study arm without any sequential therapy (control group).

The ointment was applied to the treated areas and surrounding area within 1 cm. Compliance of the ointment treatment was assessed by asking the patient to return the empty packs at the final visit.

We collected the anthropometric parameters (sex, age, body mass index) and an accurate medical history (in particular cigarette smoking and alcohol consumption).

We also performed a biopsy of a small portion of the lesion for histological examination and viral typing by polymerase chain reaction (PCR).



Tables 7 and 8 show the main demographic and clinical characteristics of the enrolled subjects (24 in group A and 12 in group B).

Follow-up visits were carried out up to 12 months after the last laser treatment session. We also proposed a final superficial curettage of healed areas for PCR to detect virus persistence

For any recurrences in both groups, we proposed the exit from the study and the transition to another therapeutic regimen.

Patient	Gender	Age (years)	BMI	Smoke (sig/day)	Alcohol (glasses/day)	N° lesions	Size (mm)	Site	HPV type
1	M	52	24	0	0	>5, ≤10	>3 mm	perianal	6
2	F	27	22	15	0	>5, ≤10	>3 mm	labia majora and minora	6
3	M	23	19	0	1	>5, ≤10	>3 mm	penis shaft, glans	6
4	M	22	19	15	1	>10	>3 mm	penis shaft	6
5	F	39	25	0	0	≤5	>3 mm	pubis	6
6	M	69	26	0	0	≤5	>3 mm	penis shaft	11
7	M	28	22	15	0	≤5	≤3mm	pubis	6
8	M	36	20	0	0	>5, ≤10	≤3mm	base of the penis	6
9	M	21	18	0	1	>10	≤3mm	pubis, penis shaft	6
10	M	26	27	15	1	>10	>3 mm	pubis, penis shaft	6

11	M	25	20	10	1	>10	>3 mm	perianal	6
12	M	39	32	0	0	>5, ≤10	>3 mm	penile penis shaft	91
13	M	57	30	0	0	>10	>3 mm	glans, foreskin	6
14	F	25	18	10	0	>5, ≤10	>3 mm	labia minora, perianal	16
15	M	42	22	0	0	>5, ≤10	>3 mm	frenulum	42
16	M	27	26	0	1	>10	≤3mm	pubis, penis shaft	6
17	F	31	19	0	0	>5, ≤10	>3 mm	pubis, right inguinal region	6
18	M	54	28	20	1	>5, ≤10	>3 mm	penis shaft	6
19	M	35	23	0	0	≤5	≤3mm	pubis, penis shaft	6
20	F	43	22	0	0	>5, ≤10	>3 mm	vulva	6
21	M	27	27	15	1	≤5	≤3mm	penis shaft	11
22	M	42	30	20	0	>10	>3 mm	pubis	6
23	M	36	23	0	0	≤5	>3 mm	perianal	6
24	F	34	22	0	1	>5, ≤10	>3 mm	vulva, perianal	6, 16

Table 7 Group A summary data

Patient	Gender	Age (years)	BMI	Smoke (sig./day)	Alcohol (glasses/day)	N° lesions	Size (mm)	Site	HPV type
1	M	27	22	20	1	>5, ≤10	>3 mm	penis shaft	11
2	F	45	24	15	1	≤5	≤3mm	pubis	6
3	M	31	27	0	0	>10	>3 mm	perianal	11
4	M	28	25	0	0	>10	>3 mm	penis shaft	11
5	F	37	25	0	0	>5, ≤10	≤3mm	vulva	6
6	F	54	28	0	0	≤5	>3 mm	vulva	6
7	M	55	30	0	0	>5, ≤10	>3 mm	penis shaft	6
8	M	22	18	0	1	≤5	>3 mm	foreskin	6
9	M	28	20	15	1	>5, ≤10	>3 mm	glans	6
10	M	30	20	0	1	>5, ≤10	>3 mm	perianal	6
11	M	40	30	10	0	≤5	≤3mm	foreskin	11
12	M	34	24	0	0	>10	>3 mm	penis shaft	6

Table 8 Group B summary data

### 3.4.3 Endpoints

The primary endpoint was to compare the percentage of subjects with the appearance of new lesions in the area treated with CO<sup>2</sup> laser and sinecatechins in an observation period of 12 months after the last ablative session. The secondary endpoint was to evaluate local tolerability and the appearance of side effects such as burning, itching and pain. The intensity of cutaneous side effects was classified as none, mild, moderate, or severe. In case of serious side effects, the treatment was stopped.

#### 3.4.4 Statistic analysis

An initial descriptive analysis was conducted by summarizing the quantitative variables with mean and standard deviation, while the qualitative ones with absolute frequencies and percentages, in both cases dividing them into groups.

Subsequently, the difference between the two groups was evaluated with reference to all categories of variables (quantitative and qualitative), using the non-parametric Mann-Whitney test. This choice is motivated by the fact that the samples are not numerous and the variables do not meet the requirements of homogeneity of variance and Gaussian distribution (evaluated respectively with the Fligner-Killeen test and the Shapiro-Wilk test). All tests were conducted considering a significance level  $\alpha=0.05$  and using the R Studio software.

#### 3.5 Results

The two groups were similar for all the evaluated variables (Table 9), except for the recurrence of the disease. Most patients had 5 or more lesions to treat. One patient in group A left the study due to the appearance of burning and erosions in the treated site after one month of application (with complete restitutio ad integrum 2 weeks after suspension). Thus, 35 patients completed the study. During the observation period, 2 out of 23 patients in group A (RR: 8.7%) presented new condylomatous lesions in the treated sites; in the control group 6 subjects out of 12 (RR: 50%) presented new lesions in the treated sites.

The null hypothesis that the two samples derive from the same population, with reference to the recurrence of the disease, with p-value < 0.001, must be rejected.

The final PCR on the healed surfaces confirmed the complete clearance of the virus

In group A, 7 subjects (including the patient who left the study) reported mild to moderate erythema, erosions or burning sensation at the application site (Table 10).

Some examples are shown in figures 10 to 17.

	Group A N=24	Group B N=12	p-value
Age	35.8±12.4	35.9±10.7	0.71
Gender			
Males	18 (75.0%)	9 (75.0%)	0.83
Females	6 (25.0%)	3 (25.0%)	
Smoke (cigarettes/day)	5.63±7.71	5.00±7.69	0.83
BMI (kg/m <sup>2</sup> )	23.5±4.0	24.4±3.9	0.47
Alcohol(glasses/day)			
No	9 (37.5%)	5 (41.7%)	0.83
One glass	15 (62.5%)	7 (58.8%)	
Size			
≤3 mm	6 (25.0%)	3 (25.0%)	1.0
>3 mm	18 (75.0%)	9 (75.0%)	
N° lesions			
≤5	6 (25.0%)	4 (33.3%)	0.90
>5, ≤10	11 (45.8%)	5 (41.7%)	
>10	7 (29.2%)	3 (25.0%)	
<b>Recurrence</b>			
No	21 (91.3%)	6 (50.0%)	<b>0.0070</b>
Yes	2 (8.70%)	6 (50.0%)	

Table 9 Summary data of the two groups

Patient	1	3	9	10	11	13	15
Side effects	Erythema, erosions, burning	Erythema, erosions, pain	Erythema	Erythema, erosions, burning	Erythema, erosions, burning	Erythema, erosions	Erythema

Table 10 Documented side effects in patients of Group A following application of the ointment. The numbering corresponds to that reported in tab. 7

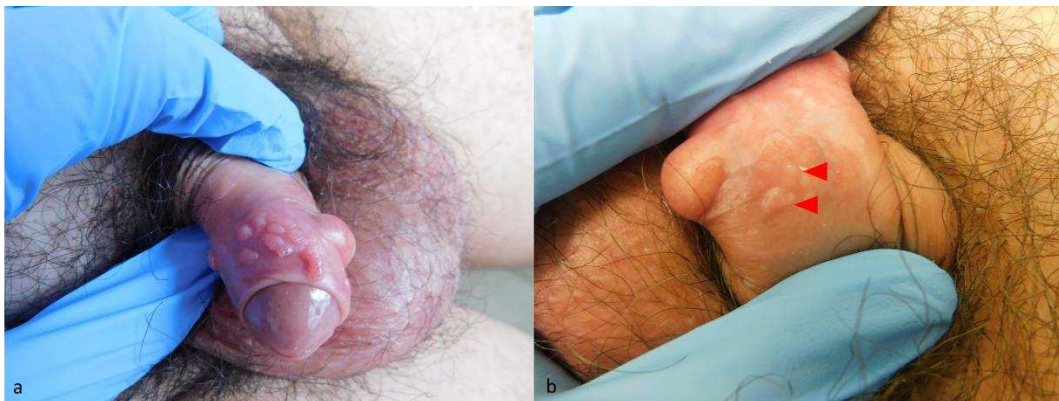


Figure 10 Foreskin warts in a patient of control group: a) first visit; b) 3-month follow-up: relapses (red triangles).

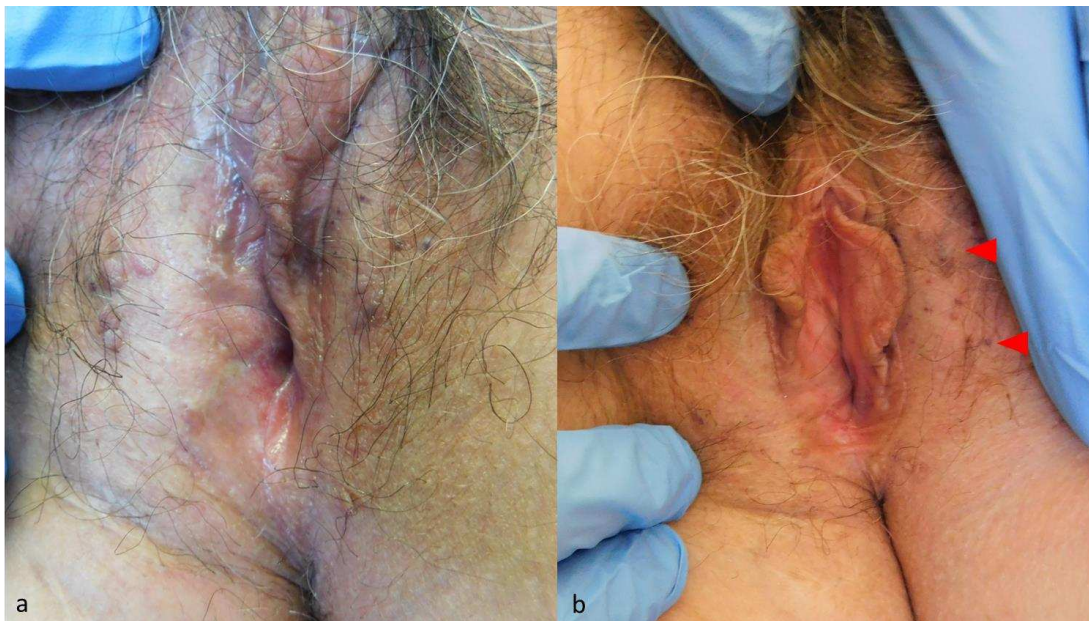


Figure 11 Vulvar warts in a patient of the control group: a) first visit; b) relapses at 3 months (red triangles)

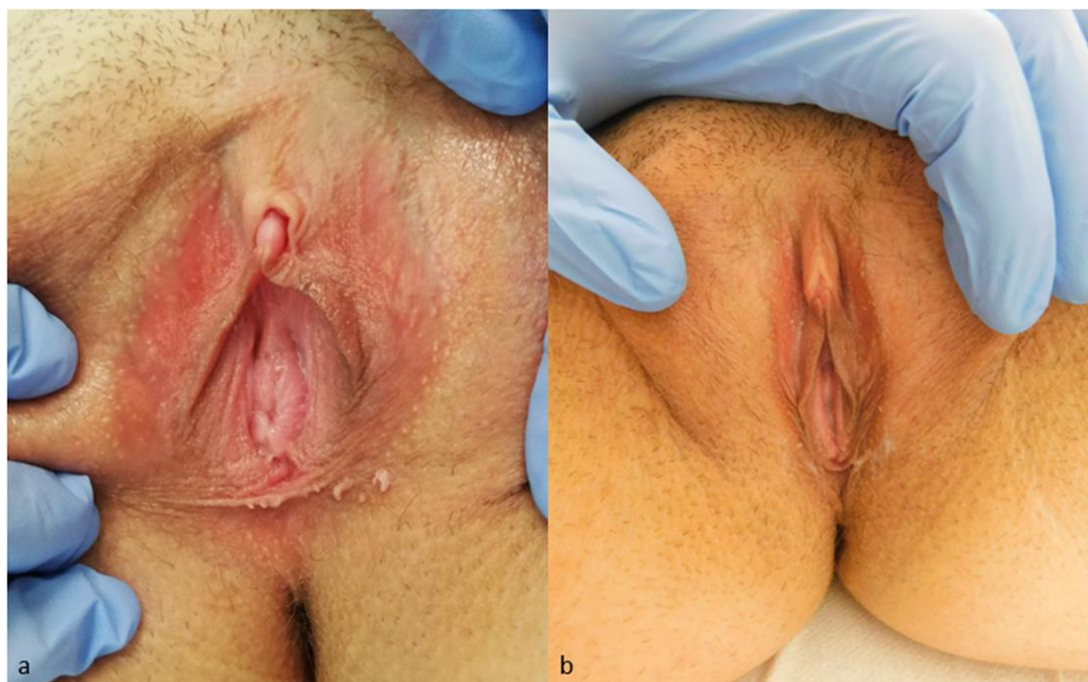
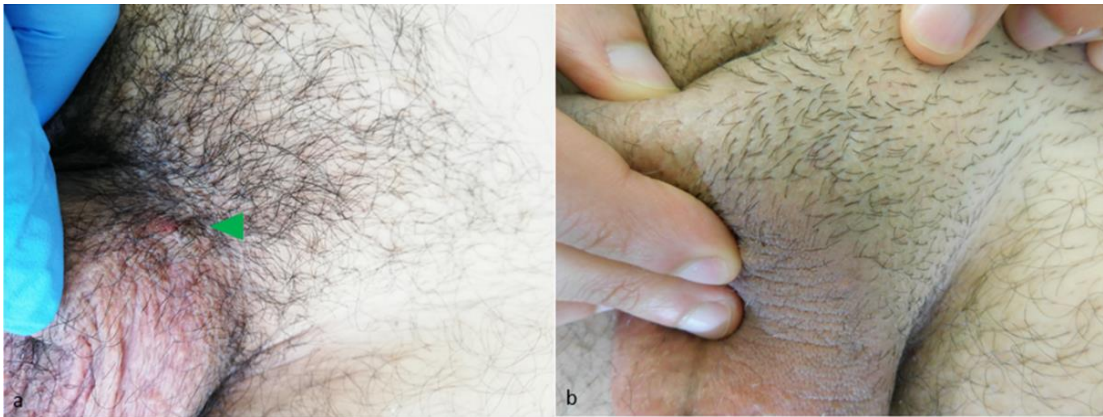
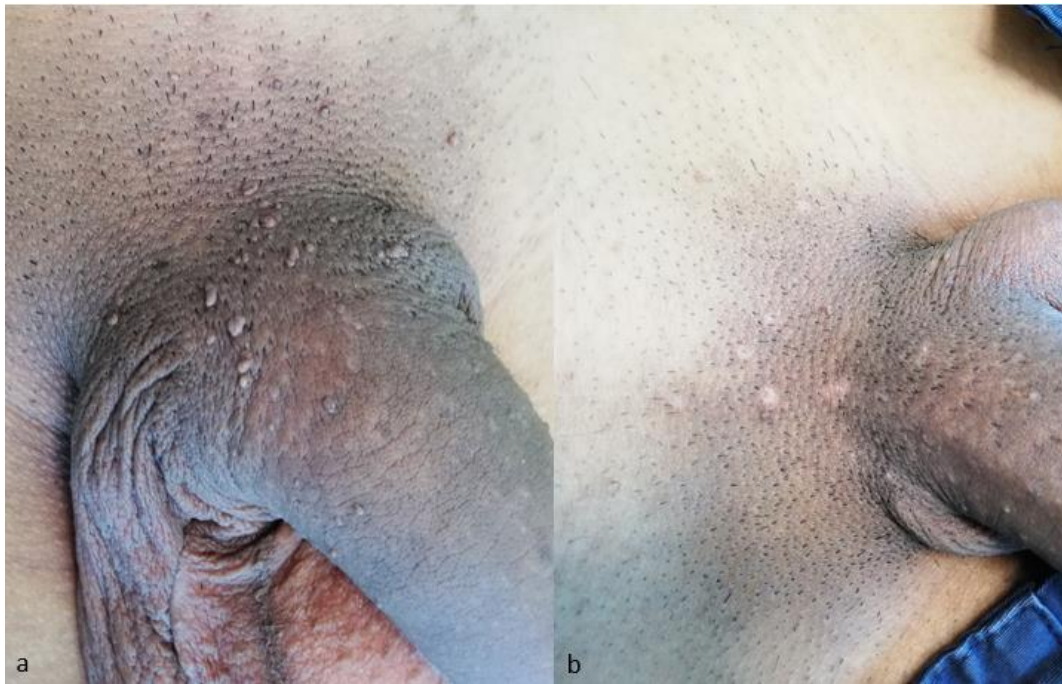Figure 12 Vulvar warts in a patient of the group A: a) first visit; b) no recurrence at 6 months

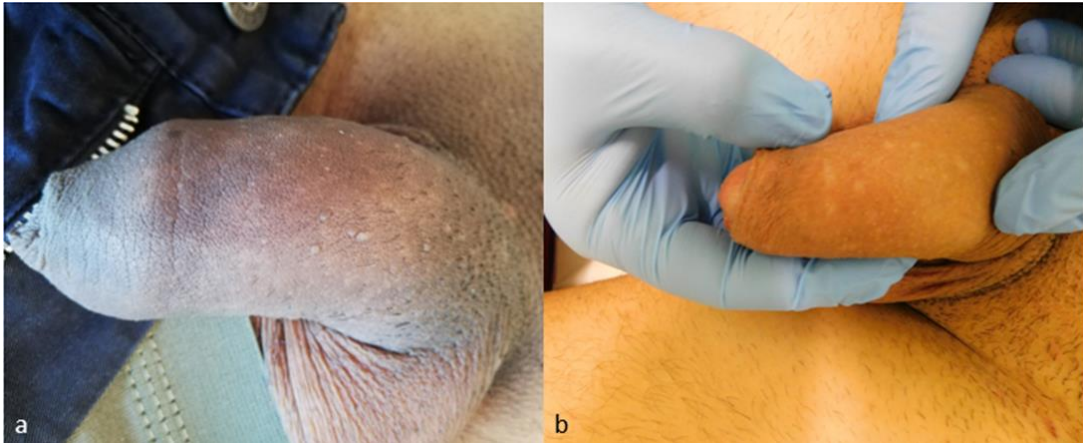


*Figure 13 Warts of the base of the penis (green triangle) in a patient of the group A: a) first visit; b) no recurrence at 6 months*

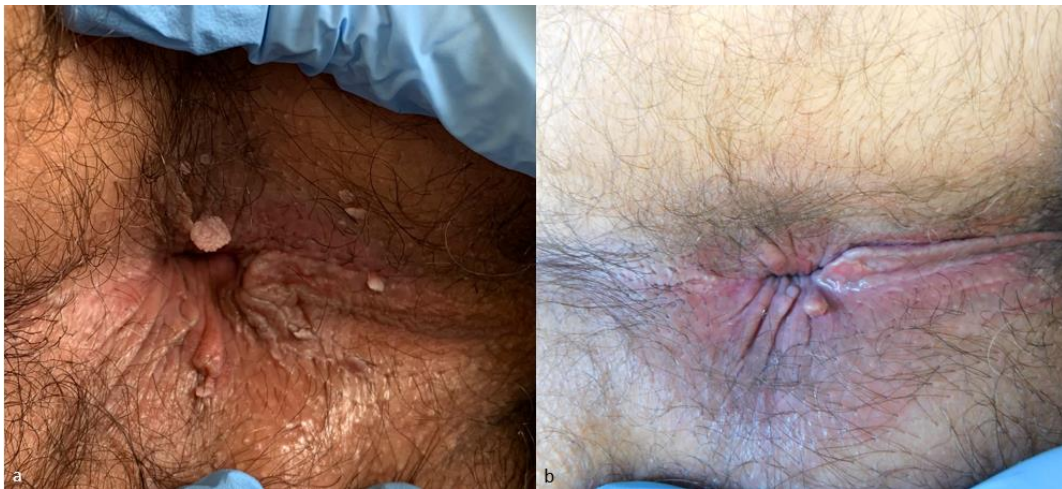

*Figure 14 Warts of the base of the penis in a patient of the group A: a) first visit; b) no recurrence at 6 months*

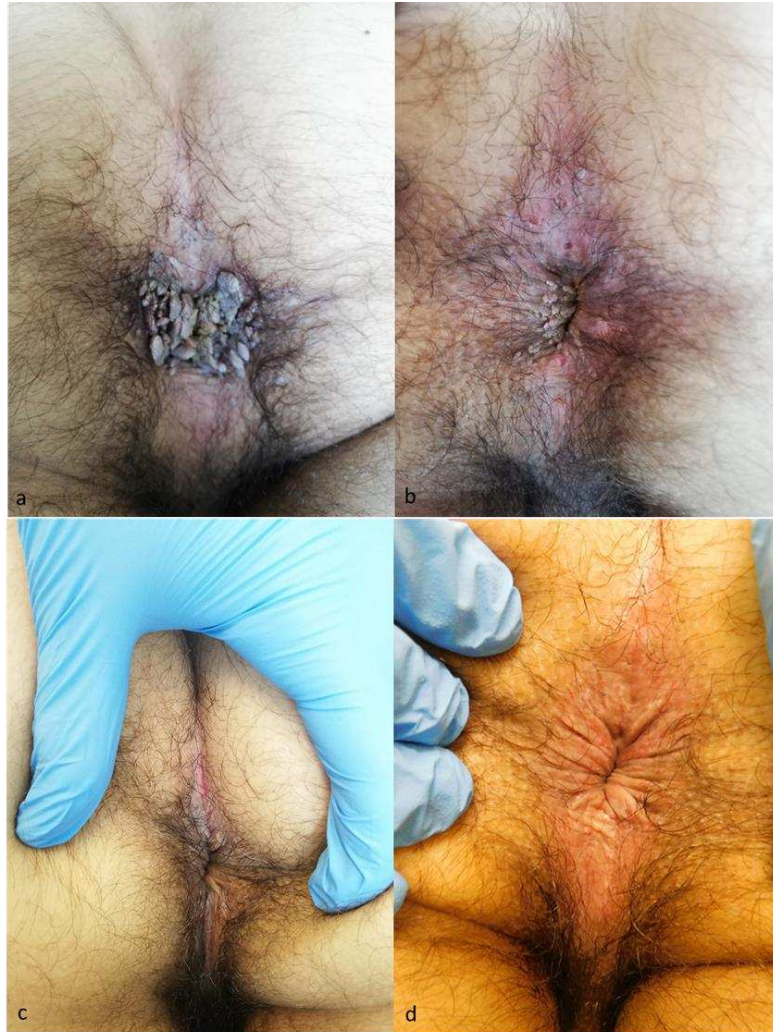



*Figure 15 Penile shaft warts in a patient of the group A: a) first visit; b) no recurrence at 6 months*



*Figure 16 Perianal warts in a patient of the group A: a) first visit; b) no recurrence at 6 months*



*Figure 17 Perianal warts in a patient of the group A: a) first visit; b) 3 weeks after the first laser treatment (new laser treatment was performed on the same date); c) 3 months after the start of treatment with sinecatechins (mild signs of irritant dermatitis); d) no recurrence at 6 months.*

### 3.6 Discussion

Different treatments (applied by the physician or the patient) for genital warts are available according to national and international guidelines, but there is currently no single approach<sup>146</sup>. Often such treatments are frustrating for both physicians and patients<sup>147</sup>. Destructive therapies such as cryotherapy, curettage or lasers are generally painful and sometimes burdened with a high recurrence rate<sup>147,148</sup>. Recurrent HPV infection is a complex phenomenon that probably involves several mechanisms

(autoinoculation, reactivation of latent infections, lack of homologous immunity, etc.)<sup>148</sup>. Studies report a recurrence at three months after cryotherapy in up to 40% of treated subjects<sup>149</sup>. After CO<sup>2</sup> laser treatment, Yanofsky et al.<sup>150</sup> reported that the RR after a CO<sup>2</sup> laser session was up to 77%. However, another study by Padilla-Ailhaud<sup>151</sup> showed that the RR after CO<sup>2</sup> laser six months after treatment reached 25%. The recurrence rate of the control group observed in our study lies perfectly within the range of results reported in the literature. After treatment with sinecatechins, the reported three-month RR was between 7% and 12%<sup>126,128</sup>. EGCG, the main component of green tea extract, has been shown to have antiviral activity against HPV<sup>136</sup>. EGCG is a potent anti-inflammatory, anti-oxidant and pro-apoptotic<sup>152</sup>. These mechanisms could explain its antiviral properties<sup>153</sup>. In the two pivotal studies evaluating the efficacy of green tea extract in the treatment of genital warts, recurrence during the three-month follow-up occurred in a very small number of patients (less than 5%)<sup>134,154</sup>. In a retrospective study, Juhl et al<sup>142</sup> evaluated the efficacy of combined treatment for genital warts with cryotherapy, podophyllin, and post-ablative immunomodulation with sinecatechin 15% ointment. The initial complete lesion clearance rate was 96%, with a 6-month RR of 7.4%. In a recent study evaluating the recurrence rate of genital warts after CO<sup>2</sup> laser ablation therapy, they reported a RR of 5% in the case group, versus a 29% recurrence rate in the control group (treated with laser alone)<sup>155</sup>. However, in our study, we exclusively enrolled patients who had not previously undergone other therapies for genital warts and we included lesions of the labia minora and perianal area. Consistent with literature

data, the results of our study support that the use of green tea extract as a proactive therapy after CO<sup>2</sup> laser treatment is associated with a lower recurrence rate compared to subjects treated only with CO<sup>2</sup> laser. Some limitations of our study must be taken into consideration: first of all, it was not a double-blind placebo study; a second aspect was the relatively short period of observation after discontinuation of sinecatechins. However, according to the literature, the greatest number of relapses for all treatments is observed in a short (3 months) period of time, as also confirmed by the relapses observed in our control group which occurred mostly during the first 3 months of follow-up<sup>156</sup>. Finally, our results can only be applied to subjects treated with CO<sup>2</sup> lasers, not to other ablative treatments such as cryotherapy or diathermocoagulation. Further studies are needed to verify this aspect. In our study, sinecatechin 10% ointment was applied twice daily. In the treatment of genital warts, this product is commonly used on a three application daily schedule. However, recently de Vries et al.<sup>157</sup>, using an adhesive tape stripping method, demonstrated that after topical application of 10% sinecatechins it is possible to detect a significant amount of substance on the patient's skin at 12 hours. There was no significant difference in EGCG concentrations after 8 and 12 hours. These data, therefore, support the rationale for twice-daily dosing. Another aspect that could be interesting to evaluate is the clearance of the virus in healthy skin after healing through molecular biology investigations, also considering that two of the patients enrolled in the treatment group were affected by HPV 16 (high oncogenic risk).

### 3.7 Conclusion

In this prospective randomized study, the use of sinecatechin 10% ointment as sequential proactive therapy after CO<sup>2</sup> laser ablative treatment was associated with a lower recurrence rate of new lesions at treated sites in the short to medium term compared to the control group. Comparative trials with larger studies and longer follow-ups are needed to confirm our data.

## Bibliography

1. Strauss, M. J. & Shaw, E. W. Crystalline virus-like particles from skin papillomas characterized by intranuclear inclusion bodies. *Proc. Soc. Exp. Biol. Med. Soc. Exp. Biol. Med. N. Y. N* **72**, 46–50 (1949).
2. Gissmann, L., Pfister, H. & Zur Hausen, H. Human papilloma viruses (HPV): characterization of four different isolates. *Virology* **76**, 569–580 (1977).
3. Gissmann, L. & zur Hausen, H. Human papilloma virus DNA: physical mapping and genetic heterogeneity. *Proc. Natl. Acad. Sci. U. S. A.* **73**, 1310–1313 (1976).
4. Orth, G., Favre, M. & Croissant, O. Characterization of a new type of human papillomavirus that causes skin warts. *J. Virol.* **24**, 108–120 (1977).
5. Bernard, H. U., Chan, S. Y. & Delius, H. Evolution of papillomaviruses. *Curr. Top. Microbiol. Immunol.* **186**, 33–54 (1994).
6. Chen, Z. *et al.* Non-human Primate Papillomaviruses Share Similar Evolutionary Histories and Niche Adaptation as the Human Counterparts. *Front. Microbiol.* **10**, (2019).
7. zur Hausen, H. Condylomata acuminata and human genital cancer. *Cancer Res.* **36**, 794 (1976).
8. zur Hausen, H., Meinhof, W., Scheiber, W. & Bornkamm, G. W. Attempts to detect virus-specific DNA in human tumors. I. Nucleic acid hybridizations with complementary RNA of human wart virus. *Int. J. Cancer* **13**, 650–656 (1974).
9. Rous, P. & Beard, J. W. Carcinomatous Changes in Virus-induced Papillomas of the Skin of the Rabbit. *Exp. Biol. Med.* **32**, 578–580 (1935).
10. Boiron, M., Levy, J. P., Thomas, M., Friedmann, J. C. & Bernard, J. SOME PROPERTIES OF BOVINE PAPILOMA VIRUS. *Nature* **201**, 423–424 (1964).
11. Bernard, H.-U. *et al.* Classification of papillomaviruses (PVs) based on 189 PV types and proposal of taxonomic amendments. *Virology* **401**, 70–79 (2010).

12. de Villiers, E.-M., Fauquet, C., Broker, T. R., Bernard, H.-U. & zur Hausen, H. Classification of papillomaviruses. *Virology* **324**, 17–27 (2004).
13. Harden, M. E. & Munger, K. Human papillomavirus molecular biology. *Mutat. Res. Mutat. Res.* **772**, 3–12 (2017).
14. Van Doorslaer, K. *et al.* The Papillomavirus Episteme: a central resource for papillomavirus sequence data and analysis. *Nucleic Acids Res.* **41**, D571-578 (2013).
15. Knipe, D.M., Howley, P.M. *Fields virology. 6th. Philadelphia, PA: Wolters Kluwer/Lippincott Williams & Wilkins Health; 2013.*
16. Favre, M., Orth, G., Croissant, O. & Yaniv, M. Human papillomavirus DNA: physical map. *Proc. Natl. Acad. Sci. U. S. A.* **72**, 4810–4814 (1975).
17. Zheng, Z.-M. & Baker, C. C. Papillomavirus genome structure, expression, and post-transcriptional regulation. *Front. Biosci. J. Virtual Libr.* **11**, 2286–2302 (2006).
18. Doorbar, J., Campbell, D., Grand, R. J. & Gallimore, P. H. Identification of the human papilloma virus-1a E4 gene products. *EMBO J.* **5**, 355–362 (1986).
19. Bergvall, M., Melendy, T. & Archambault, J. The E1 proteins. *Virology* **445**, 35–56 (2013).
20. McBride, A. A. The papillomavirus E2 proteins. *Virology* **445**, 57–79 (2013).
21. Doorbar, J. The E4 protein; structure, function and patterns of expression. *Virology* **445**, 80–98 (2013).
22. DiMaio, D. & Petti, L. M. The E5 proteins. *Virology* **445**, 99–114 (2013).
23. Vande Pol, S. B. & Klingelhutz, A. J. Papillomavirus E6 oncoproteins. *Virology* **445**, 115–137 (2013).
24. Roman, A. & Munger, K. The papillomavirus E7 proteins. *Virology* **445**, 138–168 (2013).

25. Dyson, N., Howley, P. M., Münger, K. & Harlow, E. The human papilloma virus-16 E7 oncoprotein is able to bind to the retinoblastoma gene product. *Science* **243**, 934–937 (1989).
26. Buck, C. B., Day, P. M. & Trus, B. L. The papillomavirus major capsid protein L1. *Virology* **445**, 169–174 (2013).
27. Pass, F., Reissig, M., Shah, K. V., Eisinger, M. & Orth, G. Identification of an immunologically distinct papillomavirus from lesions of epidermodysplasia verruciformis. *J. Natl. Cancer Inst.* **59**, 1107–1112 (1977).
28. Orth, G. *et al.* Characterization of two types of human papillomaviruses in lesions of epidermodysplasia verruciformis. *Proc. Natl. Acad. Sci. U. S. A.* **75**, 1537–1541 (1978).
29. Ramoz, N. *et al.* Mutations in two adjacent novel genes are associated with epidermodysplasia verruciformis. *Nat. Genet.* **32**, 579–581 (2002).
30. de Martel, C. *et al.* Global burden of cancers attributable to infections in 2008: a review and synthetic analysis. *Lancet Oncol.* **13**, 607–615 (2012).
31. Chaturvedi, A. K. Beyond cervical cancer: burden of other HPV-related cancers among men and women. *J. Adolesc. Health Off. Publ. Soc. Adolesc. Med.* **46**, S20-26 (2010).
32. Tota, J. E., Chevarie-Davis, M., Richardson, L. A., Devries, M. & Franco, E. L. Epidemiology and burden of HPV infection and related diseases: implications for prevention strategies. *Prev. Med.* **53 Suppl 1**, S12-21 (2011).
33. Winer, R. L. *et al.* Condom use and the risk of genital human papillomavirus infection in young women. *N. Engl. J. Med.* **354**, 2645–2654 (2006).
34. Chaturvedi, A. K. *et al.* Human papillomavirus and rising oropharyngeal cancer incidence in the United States. *J. Clin. Oncol. Off. J. Am. Soc. Clin. Oncol.* **29**, 4294–4301 (2011).



35. Gillison, M. L., Chaturvedi, A. K. & Lowy, D. R. HPV prophylactic vaccines and the potential prevention of noncervical cancers in both men and women. *Cancer* **113**, 3036–3046 (2008).
36. Hong, S. & Laimins, L. A. Regulation of the life cycle of HPVs by differentiation and the DNA damage response. *Future Microbiol.* **8**, 1547–1557 (2013).
37. Meyers, C., Frattini, M. G., Hudson, J. B. & Laimins, L. A. Biosynthesis of human papillomavirus from a continuous cell line upon epithelial differentiation. *Science* **257**, 971–973 (1992).
38. Dollard, S. C. *et al.* Production of human papillomavirus and modulation of the infectious program in epithelial raft cultures. *Genes Dev.* **6**, 1131–1142 (1992).
39. Ingle, A. *et al.* Novel laboratory mouse papillomavirus (MusPV) infection. *Vet. Pathol.* **48**, 500–505 (2011).
40. Kaur, P. & Li, A. Adhesive properties of human basal epidermal cells: an analysis of keratinocyte stem cells, transit amplifying cells, and postmitotic differentiating cells. *J. Invest. Dermatol.* **114**, 413–420 (2000).
41. Egawa, K. Do human papillomaviruses target epidermal stem cells? *Dermatol. Basel Switz.* **207**, 251–254 (2003).
42. Herfs, M. *et al.* A discrete population of squamocolumnar junction cells implicated in the pathogenesis of cervical cancer. *Proc. Natl. Acad. Sci. U. S. A.* **109**, 10516–10521 (2012).
43. Schäfer, G., Blumenthal, M. J. & Katz, A. A. Interaction of human tumor viruses with host cell surface receptors and cell entry. *Viruses* **7**, 2592–2617 (2015).
44. Richards, R. M., Lowy, D. R., Schiller, J. T. & Day, P. M. Cleavage of the papillomavirus minor capsid protein, L2, at a furin consensus site is necessary for infection. *Proc. Natl. Acad. Sci. U. S. A.* **103**, 1522–1527 (2006).

45. Day, P. M. & Schiller, J. T. The role of furin in papillomavirus infection. *Future Microbiol.* **4**, 1255–1262 (2009).
46. Cruz, L., Biryukov, J., Conway, M. J. & Meyers, C. Cleavage of the HPV16 Minor Capsid Protein L2 during Virion Morphogenesis Ablates the Requirement for Cellular Furin during De Novo Infection. *Viruses* **7**, 5813–5830 (2015).
47. Schelhaas, M. *et al.* Human papillomavirus type 16 entry: retrograde cell surface transport along actin-rich protrusions. *PLoS Pathog.* **4**, e1000148 (2008).
48. Smith, J. L., Lidke, D. S. & Ozbun, M. A. Virus activated filopodia promote human papillomavirus type 31 uptake from the extracellular matrix. *Virology* **381**, 16–21 (2008).
49. Day, P. M., Lowy, D. R. & Schiller, J. T. Papillomaviruses infect cells via a clathrin-dependent pathway. *Virology* **307**, 1–11 (2003).
50. Roberts, J. N. *et al.* Genital transmission of HPV in a mouse model is potentiated by nonoxynol-9 and inhibited by carrageenan. *Nat. Med.* **13**, 857–861 (2007).
51. Broniarczyk, J., Massimi, P., Bergant, M. & Banks, L. Human Papillomavirus Infectious Entry and Trafficking Is a Rapid Process. *J. Virol.* **89**, 8727–8732 (2015).
52. Schelhaas, M. *et al.* Entry of human papillomavirus type 16 by actin-dependent, clathrin- and lipid raft-independent endocytosis. *PLoS Pathog.* **8**, e1002657 (2012).
53. Day, P. M. & Schelhaas, M. Concepts of papillomavirus entry into host cells. *Curr. Opin. Virol.* **4**, 24–31 (2014).
54. Bienkowska-Haba, M., Williams, C., Kim, S. M., Garcea, R. L. & Sapp, M. Cyclophilins facilitate dissociation of the human papillomavirus type 16 capsid protein L1 from the L2/DNA complex following virus entry. *J. Virol.* **86**, 9875–9887 (2012).
55. Popa, A. *et al.* Direct binding of retromer to human papillomavirus type 16 minor capsid protein L2 mediates endosome exit during viral infection. *PLoS Pathog.* **11**, e1004699 (2015).

56. Bonifacino, J. S. & Hurley, J. H. Retromer. *Curr. Opin. Cell Biol.* **20**, 427–436 (2008).
57. Bergant Marušič, M., Ozbun, M. A., Campos, S. K., Myers, M. P. & Banks, L. Human papillomavirus L2 facilitates viral escape from late endosomes via sorting nexin 17. *Traffic Cph. Den.* **13**, 455–467 (2012).
58. Bergant, M. & Banks, L. SNX17 facilitates infection with diverse papillomavirus types. *J. Virol.* **87**, 1270–1273 (2013).
59. Pim, D., Broniarczyk, J., Bergant, M., Playford, M. P. & Banks, L. A Novel PDZ Domain Interaction Mediates the Binding between Human Papillomavirus 16 L2 and Sorting Nexin 27 and Modulates Virion Trafficking. *J. Virol.* **89**, 10145–10155 (2015).
60. Florin, L. *et al.* Identification of a dynein interacting domain in the papillomavirus minor capsid protein l2. *J. Virol.* **80**, 6691–6696 (2006).
61. Schneider, M. A., Spoden, G. A., Florin, L. & Lambert, C. Identification of the dynein light chains required for human papillomavirus infection. *Cell. Microbiol.* **13**, 32–46 (2011).
62. Pyeon, D., Pearce, S. M., Lank, S. M., Ahlquist, P. & Lambert, P. F. Establishment of human papillomavirus infection requires cell cycle progression. *PLoS Pathog.* **5**, e1000318 (2009).
63. Day, P. M., Baker, C. C., Lowy, D. R. & Schiller, J. T. Establishment of papillomavirus infection is enhanced by promyelocytic leukemia protein (PML) expression. *Proc. Natl. Acad. Sci. U. S. A.* **101**, 14252–14257 (2004).
64. Maglennon, G. A., McIntosh, P. & Doorbar, J. Persistence of viral DNA in the epithelial basal layer suggests a model for papillomavirus latency following immune regression. *Virology* **414**, 153–163 (2011).
65. Doorbar, J., Egawa, N., Griffin, H., Kranjec, C. & Murakami, I. Human papillomavirus molecular biology and disease association. *Rev. Med. Virol.* **25 Suppl 1**, 2–23 (2015).

66. Klingelhutz, A. J. & Roman, A. Cellular transformation by human papillomaviruses: lessons learned by comparing high- and low-risk viruses. *Virology* **424**, 77–98 (2012).
67. Barrow-Laing, L., Chen, W. & Roman, A. Low- and high-risk human papillomavirus E7 proteins regulate p130 differently. *Virology* **400**, 233–239 (2010).
68. Roman, A. The human papillomavirus E7 protein shines a spotlight on the pRB family member, p130. *Cell Cycle Georget. Tex* **5**, 567–568 (2006).
69. Felsani, A., Mileo, A. M. & Paggi, M. G. Retinoblastoma family proteins as key targets of the small DNA virus oncoproteins. *Oncogene* **25**, 5277–5285 (2006).
70. Münger, K. & Howley, P. M. Human papillomavirus immortalization and transformation functions. *Virus Res.* **89**, 213–228 (2002).
71. Moody, C. A. & Laimins, L. A. Human papillomavirus oncoproteins: pathways to transformation. *Nat. Rev. Cancer* **10**, 550–560 (2010).
72. Scheffner, M., Huibregtse, J. M., Vierstra, R. D. & Howley, P. M. The HPV-16 E6 and E6-AP complex functions as a ubiquitin-protein ligase in the ubiquitination of p53. *Cell* **75**, 495–505 (1993).
73. Klingelhutz, A. J., Foster, S. A. & McDougall, J. K. Telomerase activation by the E6 gene product of human papillomavirus type 16. *Nature* **380**, 79–82 (1996).
74. Gewin, L. & Galloway, D. A. E box-dependent activation of telomerase by human papillomavirus type 16 E6 does not require induction of c-myc. *J. Virol.* **75**, 7198–7201 (2001).
75. Galloway, D. A. *et al.* Regulation of telomerase by human papillomaviruses. *Cold Spring Harb. Symp. Quant. Biol.* **70**, 209–215 (2005).
76. Kiyono, T. *et al.* Binding of high-risk human papillomavirus E6 oncoproteins to the human homologue of the Drosophila discs large tumor suppressor protein. *Proc. Natl. Acad. Sci. U. S. A.* **94**, 11612–11616 (1997).

77. Lee, S. S., Weiss, R. S. & Javier, R. T. Binding of human virus oncoproteins to hDlg/SAP97, a mammalian homolog of the *Drosophila* discs large tumor suppressor protein. *Proc. Natl. Acad. Sci. U. S. A.* **94**, 6670–6675 (1997).
78. Thomas, M. C. & Chiang, C.-M. E6 oncoprotein represses p53-dependent gene activation via inhibition of protein acetylation independently of inducing p53 degradation. *Mol. Cell* **17**, 251–264 (2005).
79. Jha, S. *et al.* Destabilization of TIP60 by human papillomavirus E6 results in attenuation of TIP60-dependent transcriptional regulation and apoptotic pathway. *Mol. Cell* **38**, 700–711 (2010).
80. Brimer, N., Lyons, C., Wallberg, A. E. & Vande Pol, S. B. Cutaneous papillomavirus E6 oncoproteins associate with MAML1 to repress transactivation and NOTCH signaling. *Oncogene* **31**, 4639–4646 (2012).
81. Tan, M. J. A. *et al.* Cutaneous  $\beta$ -human papillomavirus E6 proteins bind Mastermind-like coactivators and repress Notch signaling. *Proc. Natl. Acad. Sci. U. S. A.* **109**, E1473-1480 (2012).
82. Rozenblatt-Rosen, O. *et al.* Interpreting cancer genomes using systematic host network perturbations by tumour virus proteins. *Nature* **487**, 491–495 (2012).
83. Mendoza, J.-A., Jacob, Y., Cassonnet, P. & Favre, M. Human papillomavirus type 5 E6 oncoprotein represses the transforming growth factor beta signaling pathway by binding to SMAD3. *J. Virol.* **80**, 12420–12424 (2006).
84. Sakakibara, N., Mitra, R. & McBride, A. A. The papillomavirus E1 helicase activates a cellular DNA damage response in viral replication foci. *J. Virol.* **85**, 8981–8995 (2011).
85. Fradet-Turcotte, A. *et al.* Nuclear accumulation of the papillomavirus E1 helicase blocks S-phase progression and triggers an ATM-dependent DNA damage response. *J. Virol.* **85**, 8996–9012 (2011).

86. Reinson, T. *et al.* Engagement of the ATR-dependent DNA damage response at the human papillomavirus 18 replication centers during the initial amplification. *J. Virol.* **87**, 951–964 (2013).
87. Edwards, T. G., Helmus, M. J., Koeller, K., Bashkin, J. K. & Fisher, C. Human papillomavirus episome stability is reduced by aphidicolin and controlled by DNA damage response pathways. *J. Virol.* **87**, 3979–3989 (2013).
88. Merle, E., Rose, R. C., LeRoux, L. & Moroianu, J. Nuclear import of HPV11 L1 capsid protein is mediated by karyopherin alpha2beta1 heterodimers. *J. Cell. Biochem.* **74**, 628–637 (1999).
89. Darshan, M. S., Lucchi, J., Harding, E. & Moroianu, J. The L2 minor capsid protein of human papillomavirus type 16 interacts with a network of nuclear import receptors. *J. Virol.* **78**, 12179–12188 (2004).
90. Kirnbauer, R. *et al.* Efficient self-assembly of human papillomavirus type 16 L1 and L1-L2 into virus-like particles. *J. Virol.* **67**, 6929–6936 (1993).
91. Zhou, J., Sun, X. Y., Stenzel, D. J. & Frazer, I. H. Expression of vaccinia recombinant HPV 16 L1 and L2 ORF proteins in epithelial cells is sufficient for assembly of HPV virion-like particles. *Virology* **185**, 251–257 (1991).
92. Buck, C. B., Pastrana, D. V., Lowy, D. R. & Schiller, J. T. Efficient intracellular assembly of papillomaviral vectors. *J. Virol.* **78**, 751–757 (2004).
93. Buck, C. B., Thompson, C. D., Pang, Y.-Y. S., Lowy, D. R. & Schiller, J. T. Maturation of papillomavirus capsids. *J. Virol.* **79**, 2839–2846 (2005).
94. Bernard, B. A. *et al.* The human papillomavirus type 18 (HPV18) E2 gene product is a repressor of the HPV18 regulatory region in human keratinocytes. *J. Virol.* **63**, 4317–4324 (1989).

95. Thierry, F. & Yaniv, M. The BPV1-E2 trans-acting protein can be either an activator or a repressor of the HPV18 regulatory region. *EMBO J.* **6**, 3391–3397 (1987).
96. Jeon, S. & Lambert, P. F. Integration of human papillomavirus type 16 DNA into the human genome leads to increased stability of E6 and E7 mRNAs: implications for cervical carcinogenesis. *Proc. Natl. Acad. Sci. U. S. A.* **92**, 1654–1658 (1995).
97. Akagi, K. *et al.* Genome-wide analysis of HPV integration in human cancers reveals recurrent, focal genomic instability. *Genome Res.* **24**, 185–199 (2014).
98. Vinokurova, S. *et al.* Type-dependent integration frequency of human papillomavirus genomes in cervical lesions. *Cancer Res.* **68**, 307–313 (2008).
99. Pett, M. & Coleman, N. Integration of high-risk human papillomavirus: a key event in cervical carcinogenesis? *J. Pathol.* **212**, 356–367 (2007).
100. Matsukura, T., Koi, S. & Sugase, M. Both episomal and integrated forms of human papillomavirus type 16 are involved in invasive cervical cancers. *Virology* **172**, 63–72 (1989).
101. Johannsen, E. & Lambert, P. F. Epigenetics of human papillomaviruses. *Virology* **445**, 205–212 (2013).
102. Ojesina, A. I. *et al.* Landscape of genomic alterations in cervical carcinomas. *Nature* **506**, 371–375 (2014).
103. Isaacson Wechsler, E. *et al.* Reconstruction of human papillomavirus type 16-mediated early-stage neoplasia implicates E6/E7 deregulation and the loss of contact inhibition in neoplastic progression. *J. Virol.* **86**, 6358–6364 (2012).
104. Münger, K. *et al.* Viral carcinogenesis and genomic instability. *EXS* 179–199 (2006) doi:10.1007/3-7643-7378-4\_8.
105. *Dermatology: ExpertConsult.* (Elsevier, 2012).

106. Castle, P. E. & Maza, M. Prophylactic HPV vaccination: past, present, and future. *Epidemiol. Infect.* **144**, 449–468 (2016).
107. Meyer, T. *et al.* Association of rare human papillomavirus types with genital premalignant and malignant lesions. *J. Infect. Dis.* **178**, 252–255 (1998).
108. Brown, D. R., Schroeder, J. M., Bryan, J. T., Stoler, M. H. & Fife, K. H. Detection of multiple human papillomavirus types in Condylomata acuminata lesions from otherwise healthy and immunosuppressed patients. *J. Clin. Microbiol.* **37**, 3316–3322 (1999).
109. *Verruche Ano-genitali e Cutanee - Linee Guida e Raccomandazioni SIDeMaST 2016-2017.*
110. Forman, D. *et al.* Global burden of human papillomavirus and related diseases. *Vaccine* **30 Suppl 5**, F12-23 (2012).
111. Desai, S. *et al.* Genital warts and cost of care in England. *Sex. Transm. Infect.* **87**, 464–468 (2011).
112. the Genital Warts 2 (GW2) Working Group *et al.* Prevalence and incidence of external genital warts in a sample of Italian general female population. *BMC Infect. Dis.* **17**, (2017).
113. Notiziario IST 2014;27(4).
114. Syrjänen, S. & Puranen, M. Human papillomavirus infections in children: the potential role of maternal transmission. *Crit. Rev. Oral Biol. Med. Off. Publ. Am. Assoc. Oral Biol.* **11**, 259–274 (2000).
115. Wisniewski, P. M. *et al.* Studies on the transmission of viral disease via the CO<sub>2</sub> laser plume and ejecta. *J. Reprod. Med.* **35**, 1117–1123 (1990).
116. Oriel, J. D. Natural history of genital warts. *Sex. Transm. Infect.* **47**, 1–13 (1971).



117. Rymark, P., Forslund, O., Hansson, B. G. & Lindholm, K. Genital HPV infection not a local but a regional infection: experience from a female teenage group. *Sex. Transm. Infect.* **69**, 18–22 (1993).
118. Sonnex, C. *et al.* Anal human papillomavirus infection in heterosexuals with genital warts: prevalence and relation with sexual behaviour. *BMJ* **303**, 1243 (1991).
119. Arima, Y. *et al.* Development of genital warts after incident detection of human papillomavirus infection in young men. *J. Infect. Dis.* **202**, 1181–1184 (2010).
120. Goon, P. & Sonnex, C. Frequently asked questions about genital warts in the genitourinary medicine clinic: an update and review of recent literature. *Sex. Transm. Infect.* **84**, 3–7 (2008).
121. *Lever WF, Elder DE. Lever's Histopathology of the Skin, 8th edn. Philadelphia: Lippincott-Raven, 1997.*
122. Woodhall, S. *et al.* Estimation of the impact of genital warts on health-related quality of life. *Sex. Transm. Infect.* **84**, 161–166 (2008).
123. Workowski, K. A., Bolan, G. A. & Centers for Disease Control and Prevention. Sexually transmitted diseases treatment guidelines, 2015. *MMWR Recomm. Rep. Morb. Mortal. Wkly. Rep. Recomm. Rep.* **64**, 1–137 (2015).
124. Nelson, A. A. & Lask, G. P. Principles and practice of cutaneous laser and light therapy. *Clin. Plast. Surg.* **38**, 427–436, vi (2011).
125. Scheinfeld, N. & Lehman, D. S. An evidence-based review of medical and surgical treatments of genital warts. *Dermatol. Online J.* **12**, 5 (2006).
126. Tatti, S. *et al.* Sin catechins, a defined green tea extract, in the treatment of external anogenital warts: a randomized controlled trial. *Obstet. Gynecol.* **111**, 1371–1379 (2008).

127. Rosen, T. Green tea catechins: biologic properties, proposed mechanisms of action, and clinical implications. *J. Drugs Dermatol. JDD* **11**, e55-60 (2012).
128. Stockfleth, E. & Meyer, T. Sinecatechins (Polyphenon E) ointment for treatment of external genital warts and possible future indications. *Expert Opin. Biol. Ther.* **14**, 1033–1043 (2014).
129. Singh, B. N., Shankar, S. & Srivastava, R. K. Green tea catechin, epigallocatechin-3-gallate (EGCG): mechanisms, perspectives and clinical applications. *Biochem. Pharmacol.* **82**, 1807–1821 (2011).
130. Gross, G. *et al.* A randomized, double-blind, four-arm parallel-group, placebo-controlled Phase II/III study to investigate the clinical efficacy of two galenic formulations of Polyphenon E in the treatment of external genital warts. *J. Eur. Acad. Dermatol. Venereol. JEADV* **21**, 1404–1412 (2007).
131. Tatti, S. *et al.* Polyphenon E: a new treatment for external anogenital warts. *Br. J. Dermatol.* **162**, 176–184 (2010).
132. Nguyen, H. P., Doan, H. Q., Brunell, D. J., Rady, P. & Tying, S. K. Apoptotic gene expression in sinecatechins-treated external genital and perianal warts. *Viral Immunol.* **27**, 556–558 (2014).
133. Khan, N., Afaq, F., Saleem, M., Ahmad, N. & Mukhtar, H. Targeting multiple signaling pathways by green tea polyphenol (-)-epigallocatechin-3-gallate. *Cancer Res.* **66**, 2500–2505 (2006).
134. Stockfleth, E. & Meyer, T. The use of sinecatechins (polyphenon E) ointment for treatment of external genital warts. *Expert Opin. Biol. Ther.* **12**, 783–793 (2012).
135. Trompezinski, S., Denis, A., Schmitt, D. & Viac, J. Comparative effects of polyphenols from green tea (EGCG) and soybean (genistein) on VEGF and IL-8 release from normal

- human keratinocytes stimulated with the proinflammatory cytokine TNFalpha. *Arch. Dermatol. Res.* **295**, 112–116 (2003).
136. Tying, S. K. Sinecatechins: Effects on HPV-Induced Enzymes Involved in Inflammatory Mediator Generation. *J. Clin. Aesthetic Dermatol.* **5**, 19–26 (2012).
137. Bilenchi, R. *et al.* Sinecatechins 10% ointment for genital warts: Case report of a beneficial reaction in an HIV-positive woman. *Int. J. STD AIDS* **29**, 1033–1035 (2018).
138. Werner, R. N., Westfechtel, L., Dressler, C. & Nast, A. Anogenital warts and other HPV-associated anogenital lesions in the HIV-positive patient: a systematic review and meta-analysis of the efficacy and safety of interventions assessed in controlled clinical trials. *Sex. Transm. Infect.* **93**, 543–550 (2017).
139. *Sexually Transmitted Diseases Treatment CDC Guidelines, 2015, MMWR Recomm Rep 2015;64.*
140. Maw, R. D., Reitano, M. & Roy, M. An international survey of patients with genital warts: perceptions regarding treatment and impact on lifestyle. *Int. J. STD AIDS* **9**, 571–578 (1998).
141. Schöfer, H. *et al.* Sinecatechins and imiquimod as proactive sequential therapy of external genital and perianal warts in adults. *Int. J. STD AIDS* **28**, 1433–1443 (2017).
142. Juhl, M. E., Seferovic, V., Antonijevic, S. & Krunic, A. Combined treatment of anogenital HPV infection with cryodestruction, podophyllin 25% and post-ablation immunomodulation with sinecatechins 15% ointment - a retrospective analysis. *Int. J. STD AIDS* **27**, 1071–1078 (2016).
143. Lacey, C. J. N. *et al.* Randomised controlled trial and economic evaluation of podophyllotoxin solution, podophyllotoxin cream, and podophyllin in the treatment of genital warts. *Sex. Transm. Infect.* **79**, 270–275 (2003).

144. Schöfer, H., Van Ophoven, A., Henke, U., Lenz, T. & Eul, A. Randomized, comparative trial on the sustained efficacy of topical imiquimod 5% cream versus conventional ablative methods in external anogenital warts. *Eur. J. Dermatol. EJD* **16**, 642–648 (2006).
145. On, S. C. J. *et al.* A single-blinded randomized controlled study to assess the efficacy of twice daily application of sinecatechins 15% ointment when used sequentially with cryotherapy in the treatment of external genital warts. *J. Drugs Dermatol. JDD* **13**, 1400–1405 (2014).
146. Stone, K. M., Becker, T. M., Hadgu, A. & Kraus, S. J. Treatment of external genital warts: a randomised clinical trial comparing podophyllin, cryotherapy, and electrodesiccation. *Genitourin. Med.* **66**, 16–19 (1990).
147. Beutner, K. R. & Ferenczy, A. Therapeutic approaches to genital warts. *Am. J. Med.* **102**, 28–37 (1997).
148. Ranjeva, S. L. *et al.* Recurring infection with ecologically distinct HPV types can explain high prevalence and diversity. *Proc. Natl. Acad. Sci. U. S. A.* **114**, 13573–13578 (2017).
149. Lopaschuk, C. C. New approach to managing genital warts. *Can. Fam. Physician Med. Fam. Can.* **59**, 731–736 (2013).
150. Yanofsky, V. R., Patel, R. V. & Goldenberg, G. Genital warts: a comprehensive review. *J. Clin. Aesthetic Dermatol.* **5**, 25–36 (2012).
151. Padilla-Ailhau, A. Carbon dioxide laser vaporization of condyloma acuminata. *J. Low. Genit. Tract Dis.* **10**, 238–241 (2006).
152. Curti, V. *et al.* In vitro polyphenol effects on apoptosis: An update of literature data. *Semin. Cancer Biol.* **46**, 119–131 (2017).

153. Taylor, P. W., Hamilton-Miller, J. M. T. & Stapleton, P. D. Antimicrobial properties of green tea catechins. *Food Sci. Technol. Bull.* **2**, 71–81 (2005).
154. Tzellos, T. G. *et al.* Efficacy, safety and tolerability of green tea catechins in the treatment of external anogenital warts: a systematic review and meta-analysis. *J. Eur. Acad. Dermatol. Venereol. JEADV* **25**, 345–353 (2011).
155. Puviani, M. *et al.* Efficacy of sinecatechins 10% as proactive sequential therapy of external genital warts after laser CO<sub>2</sub> ablative therapy: The PACT study (post-ablation immunomodulator treatment of condylomata with sinecatechins): a randomized, masked outcome assessment, multicenter trial. *Int. J. STD AIDS* **30**, 131–136 (2019).
156. Lacey, C. J. N., Woodhall, S. C., Wikstrom, A. & Ross, J. 2012 European guideline for the management of anogenital warts: Management of anogenital warts. *J. Eur. Acad. Dermatol. Venereol.* **27**, e263–e270 (2013).
157. de Vries, H. J. C., Soltanipoor, M., Kezic, S. & Vergunst, C. E. Sinecatechins ointment 10% (Veregen®) for genital warts: percutaneous penetration of epigallocatechin gallate concentrations in the stratum corneum collected by adhesive tape stripping method. *J. Eur. Acad. Dermatol. Venereol. JEADV* **32**, e357–e358 (2018).