



Misdiagnosis of vertebral fractures on local radiographic readings of the multicentre POINT (Prevalence of Osteoporosis in INTERNAL medicine) study

This is the peer reviewed version of the following article:

Original:

Diacinti, D., Vitali, C., Gussoni, G., Pisani, D., Sinigaglia, L., Bianchi, G., et al. (2017). Misdiagnosis of vertebral fractures on local radiographic readings of the multicentre POINT (Prevalence of Osteoporosis in INTERNAL medicine) study. *BONE*, 101, 230-235 [10.1016/j.bone.2017.05.008].

Availability:

This version is available <http://hdl.handle.net/11365/1008406> since 2017-07-04T12:03:48Z

Published:

DOI:10.1016/j.bone.2017.05.008

Terms of use:

Open Access

The terms and conditions for the reuse of this version of the manuscript are specified in the publishing policy. Works made available under a Creative Commons license can be used according to the terms and conditions of said license.

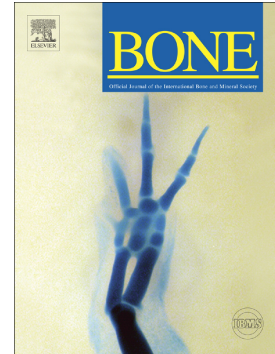For all terms of use and more information see the publisher's website.

(Article begins on next page)

Accepted Manuscript

Misdiagnosis of vertebral fractures on local radiographic readings of the multicentre POINT (Prevalence of Osteoporosis in INTernal medicine) study

Daniele Diacinti, Claudio Vitali, Gualberto Gussoni, Daniela Pisani, Luigi Sinigaglia, Gerolamo Bianchi, Ranuccio Nuti, Luigi Gennari, Stefano Pederzoli, Maddalena Grazzini, Antonella Valerio, Antonino Mazzone, Carlo Nozzoli, Mauro Campanini, Carlina V. Albanese, The Research Department of FADOI



PII: S8756-3282(17)30163-1
DOI: doi: [10.1016/j.bone.2017.05.008](https://doi.org/10.1016/j.bone.2017.05.008)
Reference: BON 11317
To appear in: *Bone*
Received date: 21 December 2016
Revised date: 28 March 2017
Accepted date: 3 May 2017

Please cite this article as: Daniele Diacinti, Claudio Vitali, Gualberto Gussoni, Daniela Pisani, Luigi Sinigaglia, Gerolamo Bianchi, Ranuccio Nuti, Luigi Gennari, Stefano Pederzoli, Maddalena Grazzini, Antonella Valerio, Antonino Mazzone, Carlo Nozzoli, Mauro Campanini, Carlina V. Albanese, The Research Department of FADOI , Misdiagnosis of vertebral fractures on local radiographic readings of the multicentre POINT (Prevalence of Osteoporosis in INTernal medicine) study, *Bone* (2017), doi: [10.1016/j.bone.2017.05.008](https://doi.org/10.1016/j.bone.2017.05.008)

This is a PDF file of an unedited manuscript that has been accepted for publication. As a service to our customers we are providing this early version of the manuscript. The manuscript will undergo copyediting, typesetting, and review of the resulting proof before it is published in its final form. Please note that during the production process errors may be discovered which could affect the content, and all legal disclaimers that apply to the journal pertain.

Misdiagnosis of vertebral fractures on local radiographic readings of the multicenter POINT (Prevalence of Osteoporosis in INTERNAL medicine) study

Daniele Diacinti¹, Claudio Vitali², Gualberto Gussoni³, Daniela Pisani⁴, Luigi Sinigaglia⁵, Gerolamo Bianchi⁶, Ranuccio Nuti⁷, Luigi Gennari⁷, Stefano Pederzoli⁸, Maddalena Grazzini⁹, Antonella Valerio³, Antonino Mazzone¹⁰, Carlo Nozzoli⁹, Mauro Campanini¹¹ and Carlina V. Albanese¹

The Research Department of FADOI *

¹ Department of Radiological Sciences, Oncology and Anatomic-Pathology, University Sapienza, Rome; ² Internal Medicine, Hospital of Piombino, Livorno; ³ FADOI Foundation, Research Department, Milan; ⁴ Department of Clinical and Molecular Medicine, Sant' Andrea Hospital, University Sapienza Rome; ⁵ Rheumatology, "G. Pini" Institute, Milan; ⁶ Department of Locomotor System, Division of Rheumatology, ASL3 – Azienda Sanitaria Genovese, Genoa; ⁷ Department of Medical, Surgical and Neurological Sciences, University of Siena; ⁸ Area Medica, Hospital of Sassuolo, Modena; ⁹ Department of Internal Medicine, AOU "Careggi", Florence; ¹⁰ Department of Internal Medicine, Legnano Hospital, Legnano; ¹¹ Department of Internal Medicine, Hospital "Maggiore della Carità" Novara.

* Members of the POINT Study Group are listed in the Appendix. FADOI is the Italian Scientific Society of Hospital Internal Medicine

Corresponding author:

Dr. Daniele Diacinti, MD

Department of Radiological Sciences, Oncology and Pathology

Sapienza Università di Roma

V.le Regina Elena 324

00161 Roma

Phone: +39 06 49975482 Fax: +39-06-490243 E-mail: daniele.diacinti@uniroma1.it

Abstract

Background. Osteoporotic vertebral fractures (VFs) are often misdiagnosed because asymptomatic and occurring in the absence of specific trauma. Further, diagnostic assessment of VFs may be suboptimal.

Aim of the study. To assess the misdiagnosis of vertebral fractures on local radiographic readings in the cohort of patients enrolled in the POINT study.

Methods. We enrolled hospitalised patients, admitted for any cause to the Internal Medicine Units of 37 hospitals participating to the cross-sectional previously published POINT study. The assessment of VFs was performed both by local radiologists and by two expert skeletal radiologists, by using semiquantitative method (SQ). To better evaluate mild vertebral deformities, the two central radiologists also used the algorithm-based qualitative assessment (ABQ).

Results. The radiographs of 661 patients (401 females; mean age 75.8 ± 8.0) were evaluated.

The inter-reader percent agreement between two central expert radiologists per-vertebra assessment was excellent (99.78%; $k = 0.984$; 95% CI, 0.977–0.991). Central reading identified 318/661 (48.1%) patients with at least one VF. Local and central readings agreed in 502/661 (75.9%) patients, resulting in a fair reproducibility ($k = 0.52$; 95% confidence interval 0.44–0.59). Diagnostic performance parameters of local readings were: sensitivity 76.1%; specificity 75.8%; PPV 74.46%; NPV 77.38%). By examining 9254 vertebrae, central and local readers diagnosed 665 (7.2%) and 562 (6.1%) VFs respectively. Misdiagnosis (102 false positives and 205 false negatives) mainly occurred for mild VFs. Local readings identified correctly 460 out 665 VFs diagnosed by central readings, resulting in sensitivity of 69.2% and PPV of 81.8%

Conclusions. Following a standardized protocol of acquisition techniques and of interpretation criteria, an excellent agreement between local and central readings for moderate and severe vertebral fractures resulted. However a significant amount of mild vertebral fractures, that are the most of VFs, were misdiagnosed by local radiologists. In order to improve VFs assessment, the radiologists should be trained and sensitized in relation to the relevant clinical significance of osteoporotic VFs identification.

Key words

Vertebral fractures, vertebral deformities, semiquantitative method (SQ), algorithm-based qualitative approach (ABQ), osteoporosis

Conflict of interest: All the authors: Daniele Diacinti, Claudio Vitali, Gualberto Gussoni, Daniela Pisani, Luigi Sinigaglia, Gerolamo Bianchi, Ranuccio Nuti, Luigi Gennari, Stefano Pederzoli, Maddalena Grazzini, Antonella Valerio, Antonino Mazzone, Carlo Nozzoli, Mauro Campanini and Carlina V. Albanese have declared no conflicts of interest.

Introduction

Vertebral fractures (VFs) are the most common of all fragility fractures due to osteoporosis (OP), occurring in approximately 25% of postmenopausal women [1,2] and men [3,4]. Most of VFs are clinically asymptomatic and, as a consequence, they often remain undiagnosed, and then a proper therapeutic intervention is omitted in most of these cases [5]. Retrospective studies on standard chest radiographs obtained in internal medicine and emergency departments revealed that about half of osteoporotic VFs were under-reported [6-7]. Also retrospective analyses of multiple detector computer tomography (MDCT) exams of the chest and abdomen demonstrated a large number of underdiagnosed cases of VFs by radiologists [8-10]. In these studies the lack of recognition of VFs is generally relevant with reference to those of mild degree that show the radiological aspect of wedging or biconcavity. This makes the radiological interpretation of mild vertebral deformities a relevant matter of controversy [11-12]. It is actually difficult to discriminate between true VFs and mild wedge like deformities in the mid-thoracic region and bowed endplates in the lumbar region, due to normal variation in height, developmental abnormalities, degenerative changes, Scheuermann's disease and large Schmorl's nodes [13-15]. This difficulty may lead to a misinterpretation of vertebral deformities as VFs and then to an overestimation of VFs, that may imply an inappropriate therapeutic intervention.

Accurate recognition of vertebral deformities due to true VFs has relevant clinical implications considering that baseline vertebral fractures are determinants of the risk of incident vertebral and non-vertebral fractures [16-17]. The presence of multiple thoracic or lumbar VFs may result in restrictive lung disease or abdominal constipation, with an increased mortality rate and impaired quality of life [18-21]. Anyway also the prevalent mild vertebral fracture has relevant clinical significance implicating a 2-fold increase in subsequent vertebral fractures over 3 years [22-24], so the need for accuracy in their radiographic identification.

In daily clinical practice the radiologist usually diagnoses VFs by visual inspection of the patient's spinal radiographs. However, this qualitative approach to identify VFs is regarded as subjective and its reproducibility is low, especially when performed by inexperienced observers [25-26]

The visual semiquantitative (SQ) method represents a simple but standardized approach to identify VFs based on visual assessment of vertebral morphology and of vertebral height reduction [27]. SQ method, provides reasonable reproducibility, sensitivity, and specificity [28], when utilized by expert radiologist. Therefore SQ method it is currently the most widely used in epidemiological studies and therapeutic trials on osteoporosis that consider the prevention of incident VFs as end-point [29-32].

Using SQ method we reported, in a previously published multicentre study (the POINT study), [33] high prevalence (47.5%) of fragility VFs in an old population of patients hospitalised in Internal Medicine Unit (IMUs) in Italy. We also demonstrated, in this particular population, that older age, chronic obstructive pulmonary disease and a previous diagnosis of OP were the demographic and clinical variables more strictly predictive of the presence of VFs. To strongly reduce the inter-rater variability, the VFs prevalence was defined in this study after a centralized evaluation of all the spine radiographs collected in participating centres. Readings made by the local radiologists working in the participating centres, although available, were not considered for the previously published POINT study analysis.

Conversely, aim of the present study is to assess the accuracy of diagnosis of vertebral fractures given by local radiologists compared to central reading in the cohort of patients enrolled in the POINT study.

Patients and Methods

The initial population of this study, was constituted by patients included in the POINT study. They were hospitalised patients aged 60 and over, admitted for any cause to the participating IMUs of 37 tertiary-care public hospitals [33].

In all patients radiographs of the thoracic and lumbar spine from T4 to L5 in the anterior–posterior and left-lateral projections, have been obtained following standardized technical parameters [34], as indicated in a procedure manual supplied to all radiologists of the 37 Centres included in the study. For lateral views, patients were positioned on their left side with knees and hips flexed. Tube-to-film distance was set at 105 cm, and the X-ray beam was centred at T7 and L2 for the thoracic and lumbar views, respectively.

Criteria for good image quality were correct lateral projection (superimposition of endplates and of the posterior edges of the vertebral bodies) and visualization of T12 on both thoracic and lumbar views to allow for complete spine assessment.

The spine radiographs of enrolled patients were evaluated for presence of VFs by one radiologist at each included centre; subsequently, radiographs were sent to a centralised radiological Unit (Radiology Dept., Policlinico Umberto I, University of Rome Sapienza), in electronic format or as x-ray films. Here two expert skeletal radiologists, CVA and DD, independently reviewed the spine images, blinded of local readings .

To assess the intra-reader reproducibility of central reading, the two expert skeletal radiologists independently read each set of scans twice, with a minimum of 7 days between evaluations of the same images, and blinded to the previous analysis made by local radiologists.

To identifying vertebral fractures, both local radiologists and central radiologists utilized SQ method by Genant et al. [27]. For vertebral fractures diagnosis SQ method initially relies upon visual assessment of vertebral morphology and configuration to discriminate true vertebral fractures from non-fracture vertebral deformities as developmental variant (“butterfly vertebra”, “Cupid’s bow”), degenerative change, large Schmorl’s nodes, Scheuermann’s disease. Then, by visual SQ assessment of vertebral height reduction, the vertebrae are classified as either normal (<20 % reduction) or as mild (20 %–25 % reduction), moderate (25 %–40 % reduction) or severe (>40 % reduction) VF. Each VF was also classified by type (wedge, biconcave, crush) based upon reduction in anterior, middle, and/or posterior heights.

Central radiologists, in addition to SQ method, in order to better evaluate mild vertebral deformities, also used the algorithm-based qualitative approach (ABQ) [35], improving the reliability of consensus reading considered as “gold standard”. ABQ approach focuses primarily on the qualitative analysis of vertebral bodies to identify change in the vertebral endplate supplying additional elements respect to SQ method to diagnose VFs discriminating non-fracture vertebral deformities, the so-called short vertebral height (SVH).

The “true reading” consisted of the results for which the two expert radiologists of the central reading agreed on VF identification by individual SQ assessments. In case of discordance on fracture identification, the two radiologists reviewed the spine images together, in order to reach a final consensus.

Statistical analysis

We calculated the prevalence of fractures on a per patient and on a per vertebrae basis , classifying VFs according to grade (mild, moderate and severe).

Intra-reader reproducibility of central reading and inter-reader agreement between the two expert radiologists of central reading and between central and local radiologist were calculated by Cohen’s kappa (k) statistics and associated 95% confidence intervals (CI).

We also calculated sensitivity, specificity, positive (PPV) and negative (NPV) predictive values of local reports, considering the consensus central reading as gold standard.

All statistical analysis was performed on a per patient and on a per vertebra basis.

Analyses were performed using statistic software SPSS (version 22; SPSS, Chicago).

Ethical Aspects

The study was conducted in accordance with the existing national rules and the Helsinki Declaration. The study protocol received the approval of the Ethical Committees of all the participating centres, and informed consent from enrolled patients was obtained.

Results

The spine radiographs of 661 patients that had both central and local reports were judged of good quality and so formed the final study cohort (401 females and 260 males; age range 60-95; mean age 75.8 ± 8.0). The number of patients enrolled was similar for each of the 37 centres ranging from 15 to 18. Therefore we compared the cumulative diagnosis per patient and per vertebra of all centres to the diagnosis provided in consensus by central readers. At each centre there was one radiologist who examined the radiographs of enrolled patients.

Per-patient analysis

Central expert radiologists identified in consensus 318/661 (48.1%) patients with at least one vertebral fracture: 174 (26.3%) had one prevalent VF and 144 (21.8%) had two or more VFs. No significant differences were observed between women (48.1%) and men (46.7%) as for prevalence of VFs. For both sexes, the prevalence of VFs increased with age, from 37% in patients aged 60-74 years to 55% in patients older than 75.

The intra-reader reproducibility of central readers was very high for both expert radiologists ($k=0.86$; 95% CI, 0.804–0.881 and 0.88; 95% CI, 0.817–0.892 respectively) and the inter-reader agreement between the two radiologists on a per patient basis was very good as well ($k = 0.82$; 95% CI, 0.786–0.863).

Local reading diagnosed the presence of VF in 242 out of the 318 patients in whom at least a VF was found by central readers, thus reaching a false-negative rate of 24%. In 35 (46%) of false-

negative cases, local reports did not describe any fracture or deformity, while in 41 (54%) of the cases local radiologists misdiagnosed VFs as vertebral deformities.

Conversely, a VF was found by local radiologist in 83 cases out of the 343 patients judged to be without VFs by central readers. So the false positive rate of local reading was 24%.

The local and central readings agreed in vertebral fracture assessment (presence *versus* absence of any VF) in 502/661 (75.9%) patients, resulting a fair reproducibility ($k=0.52$; 95% CI, 0.44–0.59).

Assuming the consensus central readings as gold standard, on a per patient basis, local readings had sensitivity 76.1% , specificity 75.8% , PPV 74.46% and NPV 77.38%.

Per-vertebra analysis

The inter-reader percent agreement between two central expert radiologists per-vertebra assessment was excellent (agreement 99.78%; $k=0.984$; 95% CI, 0.977–0.991).

When the presence of VF in any single vertebral body was considered, central readers in consensus and local readers diagnosed 665 (7.2%) and 562 (6.1%) VFs respectively, in a total of 9254 examined vertebrae. A description of the number of VFs of different degree found by central and local readers was detailed in Table 1. Among 562 VFs identified by local readers , 102 were classified as normal vertebrae by the central readers (false positives).

On the other side 205 vertebrae were incorrectly evaluated by local readings as not presenting VFs (false-negatives). Therefore local and central readers agreed in 460 out 665 VFs resulting a sensitivity of 69.2% and PPV of 81.8% .

Misdiagnosis of VFs by the local radiologists were limited to wedge and biconcave fractures of mild degree (30.8%), while both moderate and severe VFs were correctly classified. The distribution of true VFs identified both by central and local readings for each vertebral body is shown in Figure 1. As expected, most of the vertebral fractures were identified by both central and local readings in the upper thoracic spine , at T7-T8, or in the lower thoracic and upper lumbar spine , at T11-L1. The proportion of under-diagnosed fractures by local radiologist resulted higher in the thoracic spine (54% % at T7-T11 level) than in the lumbar spine (34% at L1-L5 level).

Central readers identified 152 non-fractures vertebral deformities applying ABQ approach, 50 of which were diagnosed also by local readers using only the SQ method. Therefore 102 vertebrae considered mild fractures by local readers , were classified as non-fractures deformities by central readers using ABQ method while were (false-positives). In detail, 78 wedge deformities due to degenerative changes (n=56) and Scheuermann' disease (n=22) were localized at the spine thoracic

level; additional 24 cases with biconcave appearance were due to severe scoliosis (n=16) and large Schmorl's nodes (n=8) localized at the lumbar spine level (Figure 2).

Discussion

In this study we compared the local and centralized radiologic readings, that were taken into account as gold standard, for diagnosis of vertebral fractures in an elderly hospitalised population. Following a strict protocol with standardization of acquisition techniques and of interpretation criteria, the agreement and the diagnostic performance parameters between local and central vertebral fracture assessment on per-patient basis (presence versus absence of any VF per-patient) were approximately 76%.

This result could be considered satisfactory but actually it means that local radiologists didn't identify 76 patients with vertebral fractures, equivalent with an high false negative rate (24%). The analysis per-vertebra basis demonstrated that discrepancies between local and central readings can be ascribed in the present study to both underreporting and overestimation of VFs by the local radiologists. High rate (30.8%) of VFs identified in consensus by central expert radiologist were underreported by the locally operating radiologists. Similarly to what was previously reported in other studies [8-10], underestimation of the prevalence of VFs were limited to the detection of mild vertebral fractures.

This can be probably ascribed to both inherent difficult evaluation of borderline vertebral deformities and lacking in experience of local radiologists induced to erroneously classify these vertebrae as normal. Otherwise in this study resulted an excellent (100%) agreement between the local and central readings for moderate and severe vertebral fractures, that are often symptomatic and therefore easily recognizable. This is a result of particular importance, considering that the risk of future vertebral fracture increases with the number and severity of prevalent vertebral fractures, [36]. It is documented [22] that among the women with mild, moderate, and severe vertebral fractures at baseline, 10.5, 23.6, and 38.1% respectively developed new vertebral fractures after 3 years respect to 4.3% of the women without prevalent vertebral fractures. Even if implicates a smaller increase of fracture risk respect to moderate or severe fractures, it is highlighted that the mild vertebral fractures are the most of VFs therefore their misdiagnosis has a relevant clinical impact anyway [23-24].

On the other side, overestimation of VFs occurred in about three-quarters of cases in the mid-thoracic region, where mild wedging due to osteoarthritis changes (that are common in an elderly population like the present one) were misinterpreted by local readers as VFs [37]. In the remaining

cases, mistakes in VF diagnosis occurred in the lumbar spine, where the biconcave appearance of vertebral bodies related to severe scoliosis and large Schmorl's nodes, was incorrectly classified by local radiologists as biconcave VF.

Our data were consistent with previous comparative studies between local and central radiographic reports [38-39]. In these studies under-diagnosis of VFs by local radiologists accounts from 25.8% to 46.5%, in spite of the use a standardized protocol for radiograph acquisition and SQ method to correctly identify VFs. In one of these studies [38] it was highlighted that a consistent number of false negative cases was due to ambiguous terms used in the radiologic reports ("biconcavity," "wedge deformity," and "slight reduction in height"). In another study long-standing fractures ("old" fractures) associated with secondary degenerative changes, were excluded from the computation of VFs [39].

As in some previous studies [29-32], in our experience the local radiologists used the standardized SQ method for visual assessment of vertebral morphology and visual estimation of reduction in vertebral height $\geq 20\%$, as a criterion for diagnosis of prevalent VF. SQ method has some limitations. In cases of mild vertebral deformities such as mild wedging in the midthoracic region and mild biconcavity in the lumbar region the distinction between borderline deformity (grade 0.5) and definite mild (grade 1) fractures can be difficult and sometimes arbitrary . Therefore, with the purpose of an accurate diagnosis of prevalent vertebral fractures, it is necessary adequate experience of the observer to distinguish normal variations and degenerative changes from true fractures of vertebral bodies. [40]

In the present study, central readers preliminarily applied the ABQ approach to correctly discriminate non-osteoporotic vertebral deformities from true VFs and then used SQ method to graduate VFs [41]. Using the combined approach, both ABQ and SQ, to vertebral fracture assessment the central consensus reading could be considered more reliable as gold standard.. The ABQ approach in the hands of expert observers may allow accurate identification of true fractures because it is mainly based on the identification of changes in the vertebral endplate more than on the vertebral height measurement [42]. This difference in the approaches used for vertebral fracture assessment may partially explain the misdiagnosis between local and central expert readers to identify mild vertebral fractures. After the all , the aim of this study was to evaluate the diagnostic accuracy of vertebral fractures assessment in daily practice, therefore we would like that the local non expertise radiologists to use only the most common and simple SQ method , as usually happen.

An incorrect diagnosis of mild VFs may have important implications from the clinical and therapeutic point of view [43]. As a consequence of that, the radiologic report of a VF strongly

induces the physician to introduce a proper anti-osteoporotic treatment [44]. So, the under-reporting of VF by the radiologists implies that many patients requiring this kind of therapeutic option cannot be properly identified [45]. On the other side, the incorrect classification of the various vertebral deformities as VFs may induce the prescription of unnecessary therapy, thus exposing patients to possible side effects and increasing personal or social health costs [46]. The recognition of vertebral fractures, as well as the prevention and treatment of further fractures, will likely do much to reduce fracture-related costs for the healthcare systems [47].

We are aware that this study suffers from some limitations. First, our results were obtained in a population of hospitalized patients with high prevalence of VF. Thus, these results cannot be extended to the general population. Second, we used the conventional radiographic technique for obtaining radiograph. It is well known that X-ray cone-beam may cause geometric distortion of vertebrae located at extremities of the scans, and therefore the accuracy of diagnosis of VFs could be reduced, namely at the upper thoracic and lower lumbar levels.

Conversely, this study has some strengths, which may make its findings interesting. The same standardized protocol was applied in all the participating centres for the acquisition of radiographs to obtain images of good quality and therefore to facilitate their interpretation based on SQ method. The reproducibility of the vertebral fracture assessment was very high for. The consensus central reading considered as “gold standard” was reliable, because of very high reproducibility intra- and inter-reader for both central expert skeletal radiologists.

This study demonstrated that following a standardized protocol of acquisition techniques and of interpretation criteria, an excellent agreement was obtained between local and central readings for moderate and severe fractures. However, a significant percentage of mild vertebral fractures, that are the most of VFs, were misdiagnosed by local radiologists. This large amount of discrepancies observed between radiographic reports from less expert readers and those from readers with adequate expertise demonstrates that a consistent part of radiologists should be adequately trained and sensitized in relation to the relevant clinical significance of osteoporotic VFs identification.

In particular we suggest also in daily practice a combined approach for vertebral fracture assessment, using both ABQ and SQ methods, in order to discriminate non-fracture vertebral deformities from true vertebral fractures more accurately.

In this way the radiologist may play its diagnostic role adequately in the management of patients with osteoporosis by correctly identifying all of VFs, and so driving the physician to properly treat the patients with anti-osteoporotic drugs.

Acknowledgements

We would like to mention all the members of the POINT Study Group who actively contributed in enrolment of patients and data collection (listed per centre and in order of number of enrolled patients):

C.L. Muzzolini (Ceva - CN); C. Pintaudi (Catanzaro); G. Scanelli (Ferrara); M. Grandi, C. Sacchetti (Sassuolo - MO); C. Nozzoli, M. Grazzini, F. Pieralli (Firenze); A. D'Angelo, M. Fazio (Palermo); C. Cagnoni, L. Occhipinti (Bobbio - PC); M. Campanini, F. Bobbio (Novara); A. Mazzone, M. Rondena, I. Stefani (Legnano - MI); E. Sgnaolin, P. De Sandre, K. Mattiello, G. Vescovo (Vicenza); D. Parisi, D. Di Michele, A. Zullo, M. Stucchi, T. Franchi (Teramo); M. Gasparini, S. Gerini (Fabriano - AN); G. Landini, L. Fattorini (Firenze); L. Roncucci, S. Mancini (Modena); A. Paradiso (Roma); P. Leandri, M. Reta (Bologna), R. Nardi; C. Vitali, G. Palombi (Piombino - LI); R. Frediani, G. Traballi (Verbania); A. Andreoli (Castelfranco Emilia - MO); M. Errico, F. Molinaro (S. Giovanni Rotondo - FG); L. Fusconi (Arezzo); V. Tucci, M. Nocera (Crotone); M. Zanardi, A. Maselli (San Giovanni in Persiceto - BO); A. Bulfoni, C. Vitale (Udine); M. Cipriani, A. Montagnani (Grosseto); G. Occhipinti (Livorno); S. Costantino, M. Cortigiani (Roma); G. Porciello (Fratta - AR); L. Anastasio, V. Manno (Vibo Valentia); L. Massarelli (Asti); P. Sposito (Messina); P. Stobbione, M. Tancredi (Asti); P. Del Medico (Civitanova Marche - MC); R. Giorgi, A.M. Nuzzi (Alba - CN); G. Mauro (San Giovanni in Fiore - CS); A. Migliore, F. Vacca (Roma); S. Scarpato (Scafati - SA).

The POINT Study is a joint project between FADOI (Italian Scientific Society of Hospital Internal Medicine), CROI (Italian College of Hospital Rheumatologists), SIOMMMS (Italian Scientific Society for Osteoporosis, Mineral Metabolism, and Skeletal Diseases), and SIRM (Italian Scientific Society of Medical Radiology, Musculoskeletal Section).

This study was supported by unrestricted research grants from Lilly Italia (Sesto Fiorentino, Italy) and from Istituto Farmaco Biologico Stroder, (Florence, Italy). The funders had no role in the study design, data collection and analysis, and preparation of the manuscript.

References

1. Johnell O, Kanis J. Epidemiology of osteoporotic fractures. *Osteoporos Int* 2005; Suppl 16: S3–S7
2. Cauley JA, Palermo L, Vogt M, Ensrud KE, Ewing S, Hochberg M, Nevitt MC, Black DM. Prevalent vertebral fractures in black women and white women. *J Bone Miner Res* 2008; 23: 1458-1467; doi: 10.1359/JBMR.080411
3. O'Neill TW, Felsenberg D, Varlow J, Cooper C, Kanis JA, Silman AJ. The prevalence of vertebral deformity in European men and women: the European Vertebral Osteoporosis Study. *J Bone Miner Res* 1996; 11: 1010–1018
4. Cummings SR, Melton LJ. Epidemiology and outcomes of osteoporotic fractures. *Lancet* 2002; 359: 1761-1767
5. Gehlbach SH, Bigelow C, Heimisdottir M, May S, Walker M, Kirkwood JR. Recognition of vertebral fracture in a clinical setting. *Osteoporos Int* 2000; 11: 577-582
6. Kim N, Rowe BH, Raymond G, Jen H, Colman I, Jackson SA, Siminoski KG, Chahal AM, Folk D, Majumdar SR. Underreporting of vertebral fractures on routine chest radiography. *AJR Am J Roentgenol* 2004; 182: 297-300
7. Majumdar SR, Kim N, Colman I, Chahal AM, Raymond G, Jen H, Siminoski KG, Hanley DA, Rowe BH. Incidental vertebral fractures discovered with chest radiography in the emergency department: prevalence, recognition, and osteoporosis management in a cohort of elderly patients. *Arch Intern Med* 2005; 165: 905-9
8. Williams AL, Al-Busaidi A, Sparrow PJ, Adams JE, Whitehouse RW. Underreporting of osteoporotic vertebral fractures on computed tomography. *Eur J Radiol* 2009; 69: 179–183
9. Bartalena T, Giannelli G, Rinaldi MF, Rimondi E, Rinaldi G, Sverzellati N, Gavelli G. Prevalence of thoracolumbar vertebral fractures on multidetector CT: underreporting by radiologists. *Eur J Radiol*. 2009; 69: 555-9 doi:10.4329/wjr.v2.i10.399
10. Carberry GA, Pooler BD, Binkley N, Lauder TB, Bruce RJ, Pickhardt PJ. Unreported vertebral body compression fractures at abdominal multidetector CT. *Radiology* 2013; 268: 120-6.
11. Kleerekoper M, Nelson DA. Vertebral fracture or vertebral deformity? *Calcif Tissue Int* 1992; 50: 5-6
12. Ziegler R, Scheidt-Nave C, Leidig-Bruckner G. What is a vertebral fracture? *Bone* 1996; 18:169S-177S
13. Lenchik L, Rogers LF, Delmas PD, Genant HK. Diagnosis of osteoporotic vertebral fractures: importance of recognition and description by radiologists. *AJR Am J Roentgenol* 2004; 183:949-58
14. Fink HA¹, Milavetz DL, Palermo L, Nevitt MC, Cauley JA, Genant HK, Black DM, Ensrud KE; Fracture Intervention Trial Research Group.. What proportion of incident radiographic vertebral deformities is clinically diagnosed and viceversa? *J Bone Miner Res* 2005; 20: 1216-22
15. Kim YJ, Chae Su, Kim GD, Park KH, Lee YS, Lee HY. Radiographic detection of osteoporotic vertebral fracture without collapse. *J Bone Metab* 2013; 20: 89-94
16. Cauley JA, Hochberg MC, Lui LY, Palermo L, Ensrud KE, Hillier TA, Nevitt MC, Cummings SR. Long-term risk of incident vertebral fractures. *JAMA* 2007; 298: 2761-2767
17. Lindsay R, Pack S, Li Z. Longitudinal progression of fracture prevalence through a population of postmenopausal women with osteoporosis. *Osteoporos Int* 2005; 16: 306-312
18. Kado DM, Browner WS, Palermo L, Nevitt MC, Genant HK, Cummings SR. Vertebral fractures and mortality in older women: study of osteoporotic Fractures Research Group. *Arch Intern Med* 1999; 159: 1215-1220

19. Johnell O, Kanis JA, Oden A, Sernbo I, Redlund-Johnell I, Petterson C, De Laet C, Jonsson B. Mortality after osteoporotic fractures. *Osteoporos Int* 2004; 15: 38-42
20. Romagnoli E, Carnevale V, Nofroni I, D'Erasmus E, Paglia F, De Geronimo S, Pepe J, Rajejntroph N, Maranghi M, Minisola S. Quality of life in ambulatory postmenopausal women: the impact of reduced bone mineral density and subclinical vertebral fractures. *Osteoporos Int* 2004; 15: 975-980
21. Bliuc D, Nguyen ND, Milch VE, Nguyen TV, Eisman JA, Center JR. Mortality risk associated with low-trauma osteoporotic fracture and subsequent fracture in men and women. *JAMA* 2009; 301: 513-21
22. Delmas PD, Genant HK, Crans GG, Stock JL, Wong M, Siris E, Adachi JD. Severity of prevalent vertebral fractures and the risk of subsequent vertebral and nonvertebral fractures: results from the MORE trial. *Bone*. 2003 Oct;33(4):522-32.
23. Pongchaiyakul C, Nguyen ND, Jones G, Center JR, Eisman JA, Nguyen TV. Asymptomatic vertebral deformity as a major risk factor for subsequent fractures and mortality: a long-term prospective study. *J Bone Miner Res* 2005; 20: 1349-1355
24. Roux C, Fechtenbaum J, Kolta S, Briot K, Girard M. Mild prevalent and incident vertebral fractures are risk factors for new fractures. *Osteoporos Int* 2007; 18: 1617-1624
25. Jensen GF, McNair P, Boesen J, Hegedüs V. Validity in diagnosing osteoporosis. Observer variation in interpreting spinal radiographs. *Eur J Radiol* 1984; 4: 1-3
26. Ferrar L, Jiang G, Clowes JA, et al. Comparison of densitometric and radiographic vertebral fracture assessment using the algorithm-based qualitative (ABQ) method in postmenopausal women at low and high risk of fracture. *J Bone Miner Res* 2008; 23: 103-111 ; doi: 10.1359/JBMR.071032
27. Genant HK, Wu CY, van Kuijk C, Nevitt MC. Vertebral fracture assessment using a semiquantitative technique. *J Bone Miner Res* 1993; 8: 1137-1148
28. Genant HK, Jergas M, Palermo L, Nevitt M, Valentin RS, Black D, Cummings SR. Comparison of semiquantitative visual and quantitative morphometric assessment of prevalent and incident vertebral fractures in osteoporosis. The Study of Osteoporotic Fractures Research Group. *J Bone Miner Res* 1996; 11: 984-996
29. Liberman UA, Weiss SR, Broll J, Minne HW, Quan H, Bell NH, Rodriguez-Portales J, Downs RW Jr, Dequeker J, Favus M. Effect of oral alendronate on bone mineral density and the incidence of fractures in postmenopausal osteoporosis. *N Engl J Med* 1995; 333: 1437-1443
30. Neer RM, Arnaud CD, Zanchetta JR, Prince R, Gaich GA, Reginster JY, Hodsman AB, Eriksen EF, Ish-Shalom S, Genant HK, Wang O, Mitlak BH. Effect of parathyroid hormone (1-34) on fractures and bone mineral density in postmenopausal women with osteoporosis. *N Engl J Med* 2001; 344: 1434-1441
31. Black DM, Delmas PD, Eastell R, Reid IR, Boonen S, Cauley JA, Cosman F, Lakatos P, Leung PC, Man Z, Mautalen C, Mesenbrink P, Hu H, Caminis J, Tong K, Rosario-Jansen T, Krasnow J, Hue TF, Sellmeyer D, Eriksen EF, Cummings SR; HORIZON Pivotal Fracture Trial. Once-yearly zoledronic acid for treatment of postmenopausal osteoporosis. *N Engl J Med* 2007; 356: 1809-1822
32. Cummings SR, San Martin J, McClung MR, Siris ES, Eastell R, Reid IR, Delmas P, Zoog HB, Austin M, Wang A, Kutilek S, Adami S, Zanchetta J, Libanati C, Siddhanti S, Christiansen C; FREEDOM Trial. Denosumab for prevention of fractures in postmenopausal women with osteoporosis. *N Engl J Med* 2009; 361: 756-65
33. Vitali C, Gussoni G, Bianchi G, Albanese CV, Diacinti D, Sinigaglia L, Nuti R, Muzzolini CL, Pintaudi C, Scanelli G, Magni G, Valerio A, Iori I, Mazzone A, Campanini M; Research Department of FADOI. High prevalence of fragility vertebral fractures in patients hospitalised in Internal Medicine Units. Results of the POINT (Prevalence of Osteoporosis in INTERNAL medicine) study. *Bone* 2015;74: 114-120

34. Banks LM, van Kuijk, HK Genant Radiographic technique for assessing osteoporotic vertebral deformity. In: Genant HK, Jergas M, van Juijk C, eds. Vertebral Fracture In Osteoporosis. University of California Osteoporosis Research Group, San Francisco, 1995: p 131-147
35. Jiang G, Eastell R, Barrington NA, Ferrar L. Comparison of methods for the visual identification of prevalent vertebral fracture in osteoporosis. *Osteoporos Int* 2004; 15: 887-896
36. Ferrar L, Roux C, Felsenberg D, Gluer CC, Eastell R. Association between incident and baseline vertebral fractures in European women: vertebral fracture assessment in the Osteoporosis and Ultrasound Study (OPUS). *Osteoporos Int* 2012; 23(1):59-65.
37. Abdul-Hamid Osman A, Bassionni H, Koutri R, Nus J, Geusens P, Dequeker J. Aging of the thoracic spine: distinction between wedging in osteoarthritis and fracture in osteoporosis across sectional and longitudinal study. *Bone* 1994; 15: 437-442
38. Delmas PD, van de Langerijt L, Watts NB, Eastell R, Genant H, Grauer A, Cahall DL. Underdiagnosis of vertebral fractures is a worldwide problem: the IMPACT study. *J Bone Miner Res* 2005; 20: 557-563 doi: 10.1359/JBMR.041214
39. Fechtenbaum J, Cropet C, Kolta S, Verdoncq B, Orcel P, Roux C. Reporting of vertebral fractures on spine X-rays. *Osteoporos Int* 2005; 16: 1823-6.
40. Buehring B, Krueger D, Checovich M, Gemar D, Vallarta-Ast N, Genant HK, Binkley N. Vertebral fracture assessment: impact of instrument and reader. *Osteoporos Int* 2010; 21: 487-494 doi 10.1007/s00198-009-0972-4
41. Ferrar L, Jiang G, Armbrecht G, Reid DM, Roux C, Gluer CC, Felsenberg D, Eastell R. Is short vertebral height always an osteoporotic fracture? The Osteoporosis and Ultrasound Study (OPUS). *Bone* 2007; 41: 5-12
42. Ferrar L, Jiang G, Schousboe JT, DeBold CR, Eastell R. Algorithm-Based Qualitative and Semiquantitative Identification of Prevalent Vertebral Fracture: Agreement Between Different Readers, Imaging Modalities, and Diagnostic Approaches. *J Bone Miner Res* 2008; 23:417-424 doi: 10.1359/JBMR.071032
43. D.L. Kendler, , D.C. Bauer,, K.S. Davison, L. Dian, MbBS, D.A. Hanley, S.T. Harris, M.R. McClung, , P.D. Miller, J.T. Schousboe, C.K. Vertebral fractures: clinical importance and management. *Am J Med.* 2016 Feb;129(2):221
44. Tosteson AN, Melton LJ 3rd, Dawson-Hughes B, Baim S, Favus MJ, Khosla S, Lindsay RL; National Osteoporosis Foundation Guide Committee. Cost-effective osteoporosis treatment thresholds: the United States perspective. *Osteoporos Int* 2008 Apr;19(4):437-47 doi:10.1007/s00198-007-0550-6.
45. Cooper MS, Palmer AJ, Seibel MJ. Cost-effectiveness of the Concord Minimal Trauma Fracture Liaison service, a prospective, controlled fracture prevention study. *Osteoporos Int* 2012;23(1):97-107.
46. Bennett DL, Post RD. The role of the radiologist when encountering osteoporosis in women. *AJR Am J Roentgenol* 2011; 196: 331-337.
47. Adams JE Opportunistic identification of vertebral fractures. *J Clin Densitom* 2016 Jan;19(1):54-62

Table 1. Grading and type of vertebral fractures assessed by central and local readings
(n. vertebrae=9254)

	Wedge		Biconcavity		Crush		Total	
	CR	LR	CR	LR	CR	LR	CR	LR
Mild	290	213	92	66	0	0	382 (4,1%)	279 (3%)
Moderate	114	114	70	70	10	10	194 (2.1%)	194 (2.1%)
Severe	49	47	11	13	29	29	89 (1%)	89 (1%)
Total	453 (4.9%)	374 (4%)	173 (1.9%)	149 (1.6%)	39 (0.4%)	39(0.4%)	665 (7.1%)	562 (5.9%)

CR= Central reading LR= Local reading

Legend to figures

Figure 1. Distribution of true fractures per vertebral level by the central and local radiographic readings

Figure 2. Examples of incorrect interpretation of mild vertebral deformities by local readings

A) False-negative : mild concave fracture with depression of the central vertebral endplate at T11 detected by central reading ;

B) False-negative : mild wedge fracture at T3 centrally reported ;

C) False-positive : a mild wedging at T7 due to degenerative changes by osteoarthritis was misdiagnosed as mild fracture by local readings.

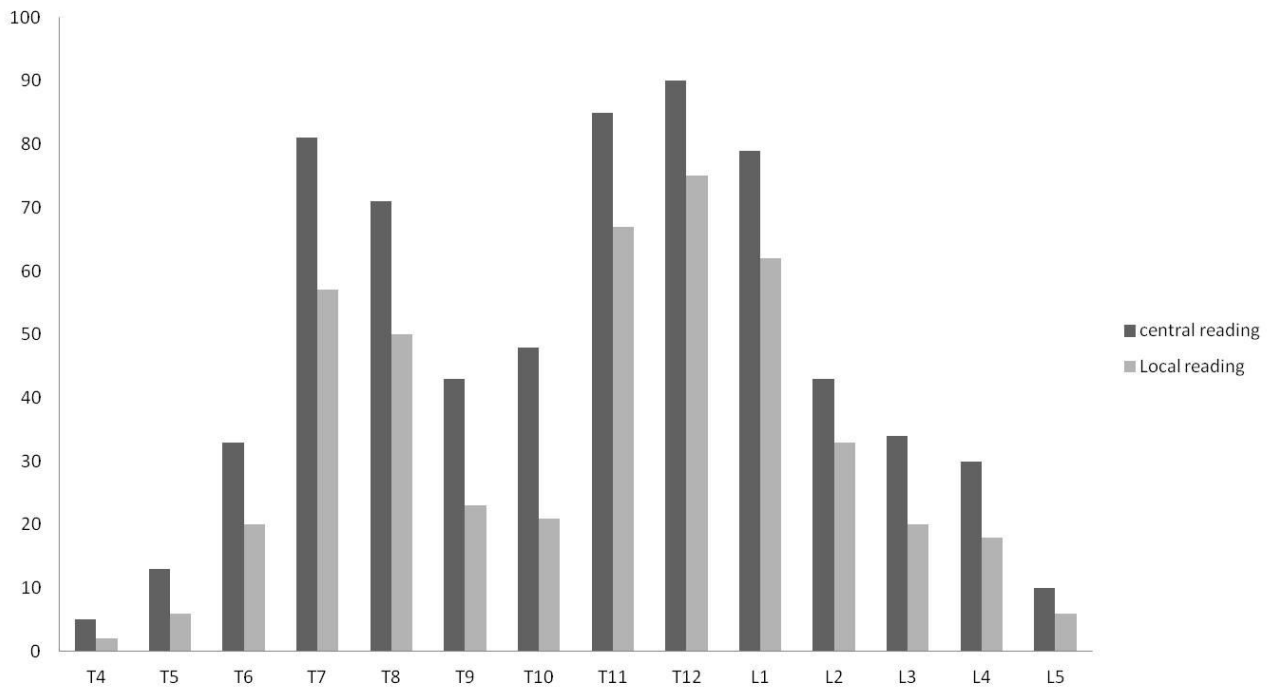


Fig. 1

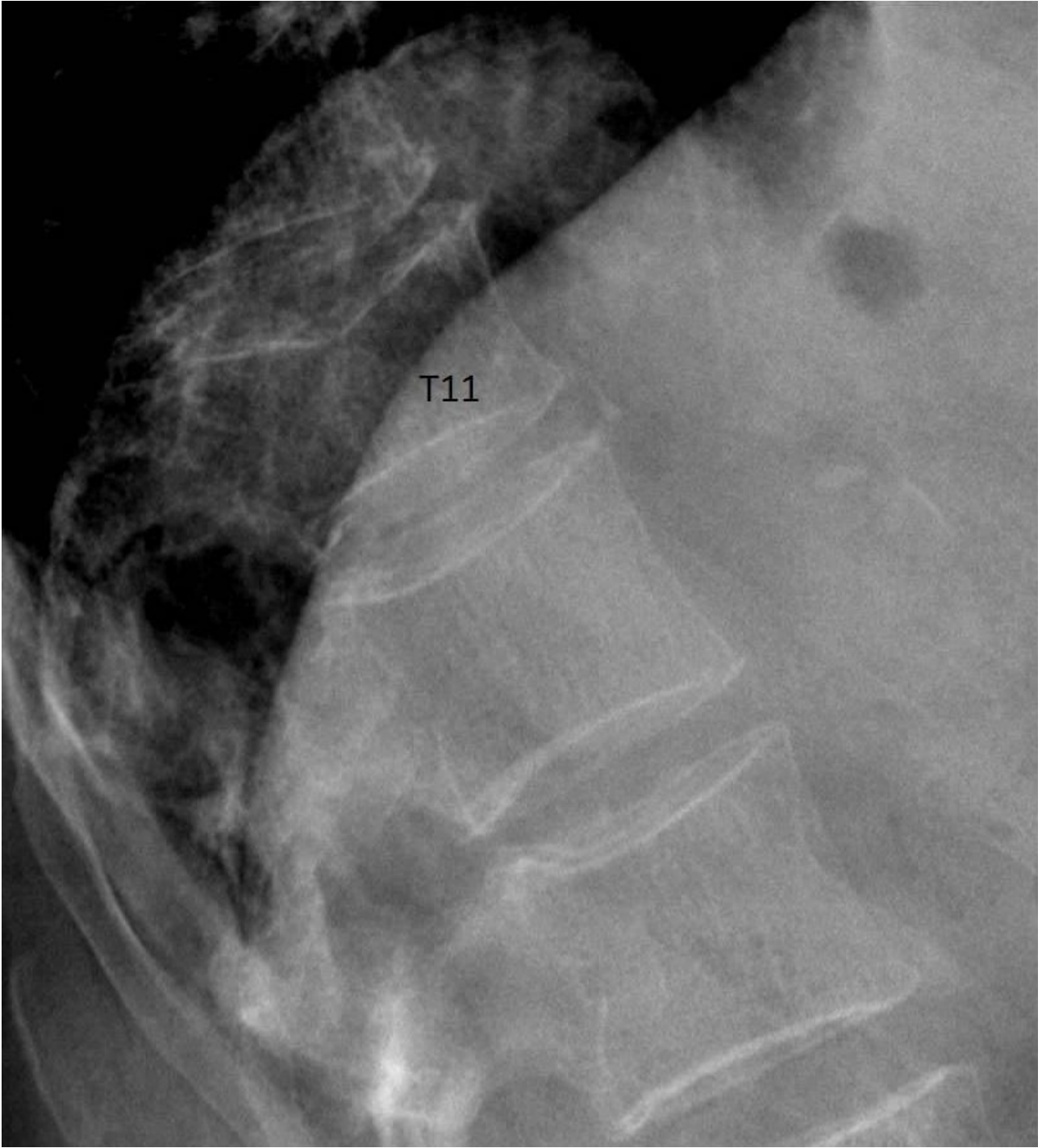


Fig. 2a

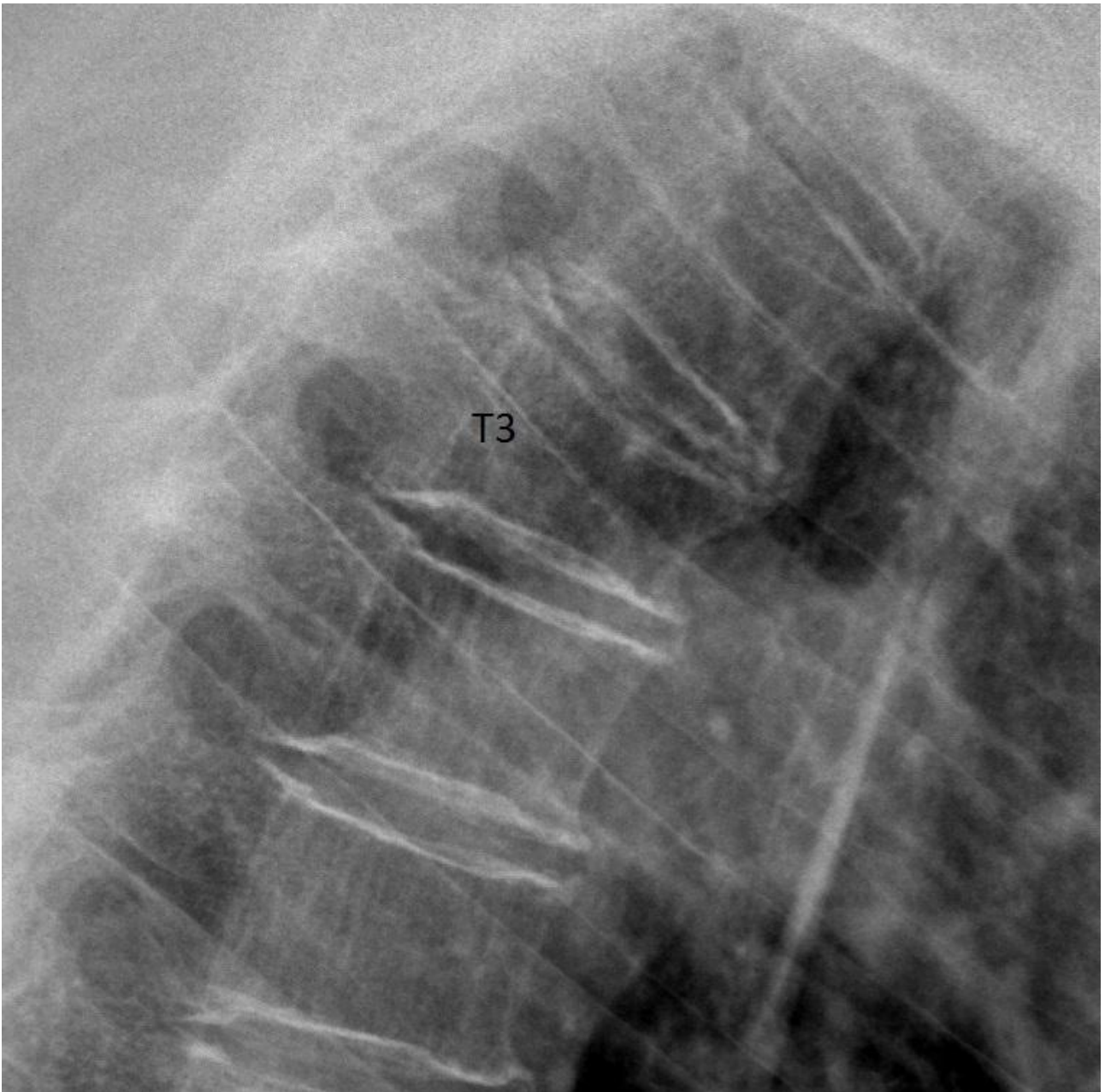


Fig. 2b

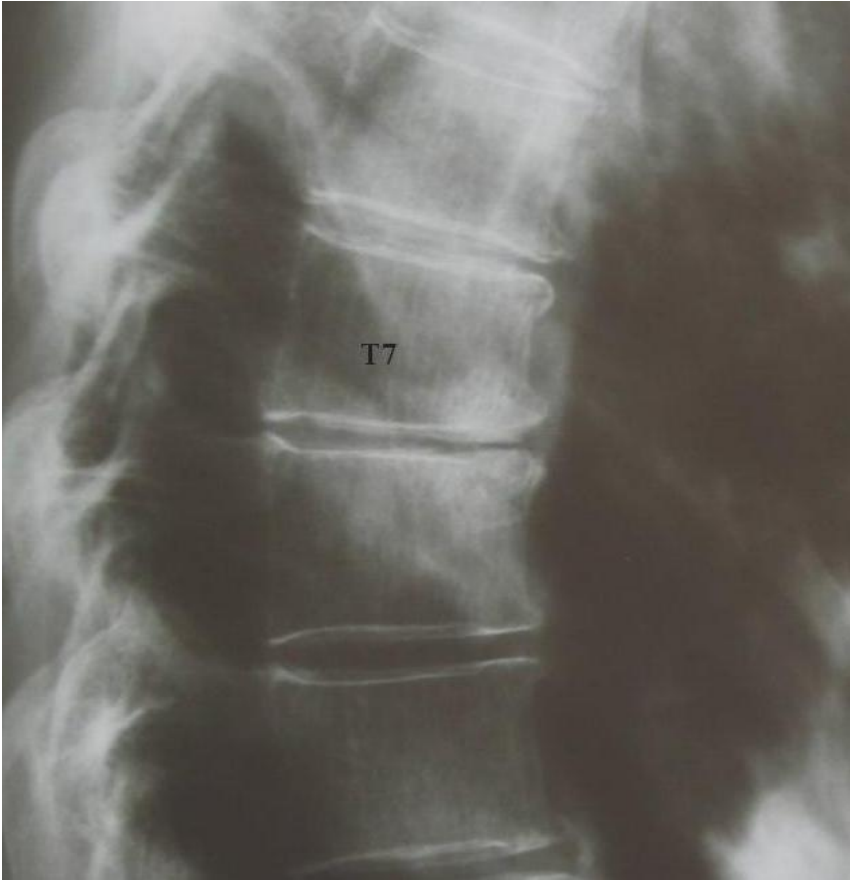


Fig. 2c

Highlights

- An excellent agreement between local and central readings for moderate and severe vertebral fractures was reached
- However a significant amount of mild VFs resulted misdiagnosed by local radiologists
- Use of ABQ and SQ methods, allows to discriminate mild VFs and vertebral deformities more accurately
- Adequate training and sensitization of radiologists for vertebral fractures assessment is needed